

Lipectomy vs Liposuction

Dehhaze Adil¹, Diher Issam^{2*}, Taybi Otmane², Daghourri Nada-Imane², Laabaci Rim², Echmili Mouad², Tita Sara², Tazi Hanae²

¹Assistant Professor and Head of the Department of Plastic, Reconstructive and Aesthetic Surgery, Center for Burned Patients, CHU Tangier-Tetouan-Al Hoceima, Morocco

²Resident, Department of Plastic, Reconstructive and Aesthetic Surgery, Center for Burned Patients, CHU Tangier-Tetouan-Al Hoceima, Morocco

DOI: [10.36347/sasjs.2022.v08i11.009](https://doi.org/10.36347/sasjs.2022.v08i11.009)

| Received: 22.08.2022 | Accepted: 16.09.2022 | Published: 29.11.2022

*Corresponding author: Diher Issam

Resident, Department of Plastic, Reconstructive and Aesthetic Surgery, Center for Burned Patients, CHU Tangier-Tetouan-Al Hoceima, Morocco

Abstract

Original Research Article

Lipomas are benign tumors of adipose tissue consisting of soft, lobulated masses held together with connective tissue and sometimes encapsulated in a thin, fibrous capsule. Lipomas are the most common soft tissue tumor, occurring in 1% of the population. The objective of our study is to present the epidemiological aspects of lipomas in the population of the region of Tangier-Tetouan-Al Hoceima, to determine the etiopathogenic aspects, and to describe the modalities of surgical treatment and especially to make a comparison between the lipectomy and liposuction. This study was carried out retrospectively, by collecting, the sex, and the reason for consultation and the location of the lipomas in the patients admitted to our service, over a period of 12 months from April 2021 to May 2022. The age of our patients ranged from 21 to 46 years. The mean age was 35 years and 3 months. We had 20 (74%) women and 7 (26%) men. The sex-ratio men/women were 0, 35. It must be said that many of our patients consulted because they had noticed an abnormal swelling on one part or another of their bodies. Regarding the management of our patients, only 5 benefited from liposuction while 22 patients benefited from a lipectomy. In all patients, the postoperative follow-up was simple with no early complications.

Keywords: lipomas, lipectomy, liposuction, swelling, functional or aesthetic discomfort.

Copyright © 2022 The Author(s): This is an open-access article distributed under the terms of the Creative Commons Attribution 4.0 International License (CC BY-NC 4.0) which permits unrestricted use, distribution, and reproduction in any medium for non-commercial use provided the original author and source are credited.

I. INTRODUCTION

Lipomas are benign tumors composed of subcutaneous adipose tissue. They are typically asymptomatic, but may cause discomfort with direct pressure. Removal is typically done for symptomatic or aesthetic purposes. Lipomas are typically removed by excision, with potential complications of bleeding, infection, seroma, scarring and recurrence. The objective of our study is to present the epidemiological aspects of lipomas in the population of the region of Tangier- Tetouan-Al Hoceima, to determine the diagnostic aspects, and to describe the therapeutic modalities and especially to compare between lipectomy and liposuction.

II. MATERIELS AND METHODS

Retrospectively, we included in this study all the patients treated in our plastic surgery department of the CHU Tangier between the periods from 04/01/2021

to 05/30/2022. Information collected included age, sex, lipoma site, treatment modality, complications, etc.

The results were collated and analyzed using the EXCEL program with tables, frequencies, and percentages. These were used to describe the therapeutic modalities and especially to compare between lipectomy and liposuction.

III. RESULTAS

We included in this study a total of 27 patients treated in our plastic surgery department of the CHU Tangier between the periods from 04/01/2021 to 05/30/2022. They all had lipomas of different diameters and different locations.

The mean age was 35 years and 3 months; the age group between 31 and 40 represents 66.67% in our study (Table 1).

Table 1: Distribution of patients according to the age

	Number	percentage
20-30	4	14.81%
31-40	18	66.67%
41-50	5	18.52%

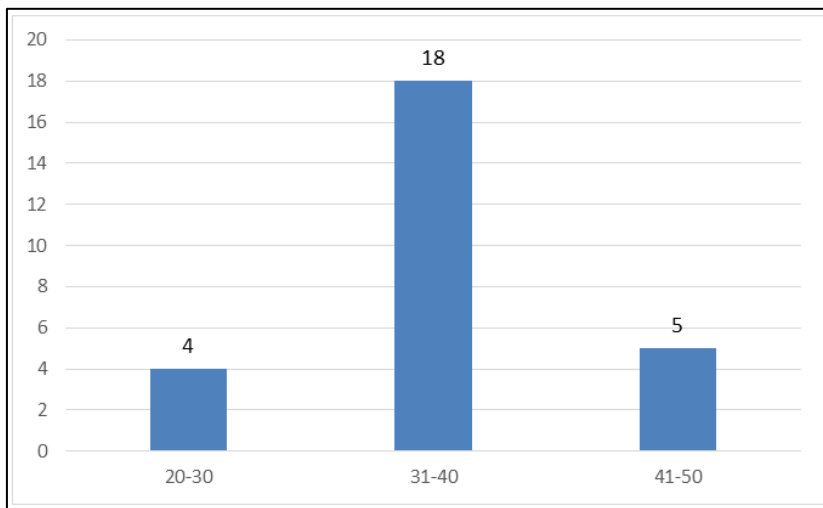


Figure 1: Distribution of patients according to the age

In this study, we had 20 (74%) women and 7 (26%) men. The sex-ratio men/women were 0, 35.

Table 2: Distribution of patients according to the sex

	Number	percentage
Women	20	74%
men	7	26%

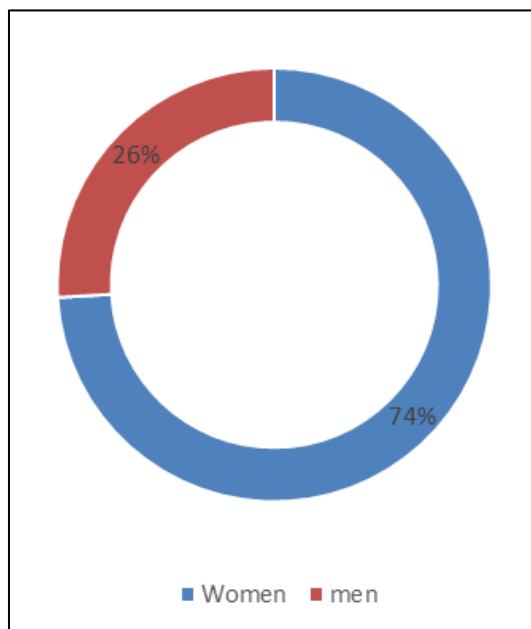


Figure 2: Distribution of patients according to the sex.

It must be said that many of our patients consulted because they had noticed an abnormal swelling on one part or another of their bodies. 25 of these patients also had functional or aesthetic

discomfort; 9 of our patients complained of pain. The other 2 patients had no symptoms and presented for swelling.

Table 3: symptomatology in our patients

symptom	discomfort	pain	Swelling
Number	25	9	26

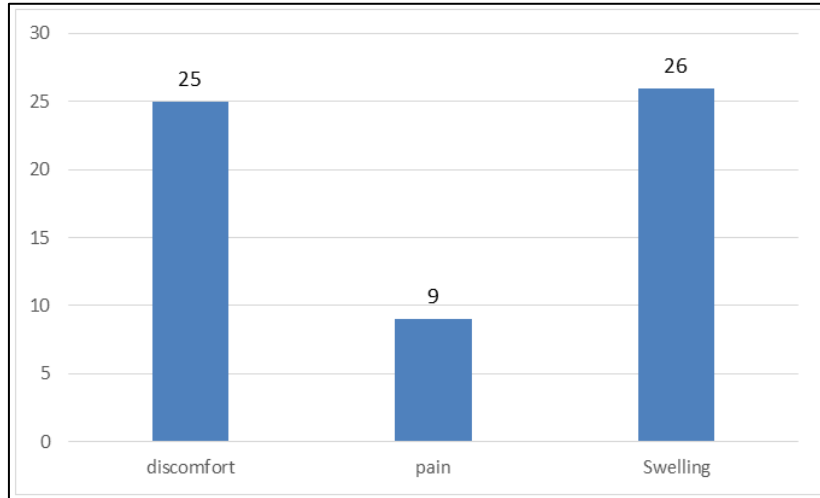


Figure 3: symptomatology in our patients

We therefore note that of our 27 diagnosed lipomas, we could not specify the evolution time of 15 of them. We can also say that 12 patients ended up consulting after 3 years of evolution.

On clinical examination, our patients had lipomas of different diameters, different consistencies and different locations. 60% of the tumors, whose

clinical or macroscopic examinations specified the dimensions, had a diameter ranging from 2 to 4cm.

The lipomas appeared as firm masses in 10 % of cases and soft in 90% of cases.

The recorded tumors were almost all mobile except for 2 cases which were fixed either deep or superficial.

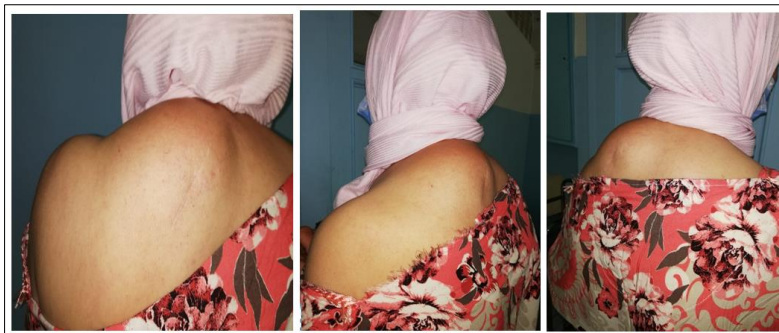

Figure 4: clinical aspect of a back lipoma

Table 4: different lipoma localization in our study

Lipoma localization	number	Percentage
Back	10	37.03%
Shoulder	7	25.92%
Arms	6	22.22%
Thigh	4	14.83%

In our patients, ultrasound examination was done almost systematically. We also noted 1 case where the diagnosis suggested by ultrasound was invalidated by the anatomopathological result.

Regarding the management of our patients, only 5 benefited from liposuction while 22 patients benefited from a lipectomy.

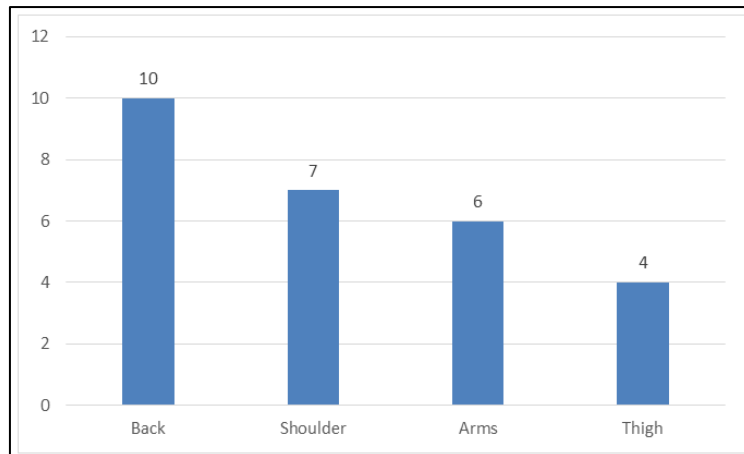


Figure 5: different lipoma localization in our study

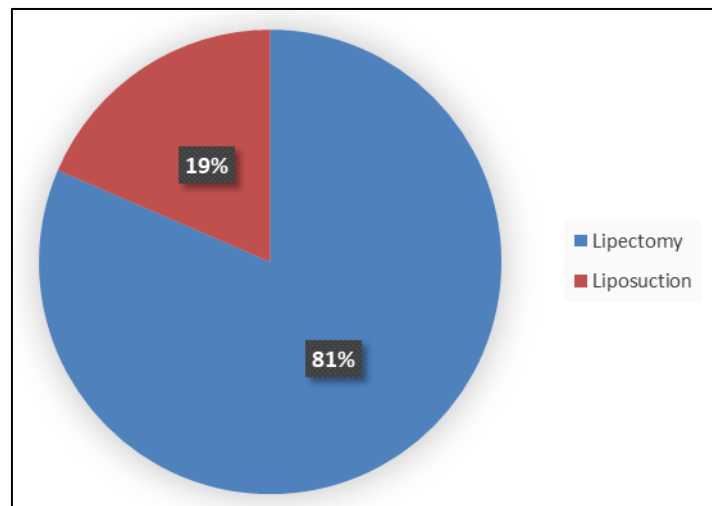


Figure 6: treatment management of our patients

It can be seen that the usual management method for these tumors in our department is complete surgical excision based on the clinic (size, appearance,

symptomatology and evolution) and the paraclinical, in short on the diagnosis of presumption.

In all patients, the postoperative follow-up was simple with no early complications.

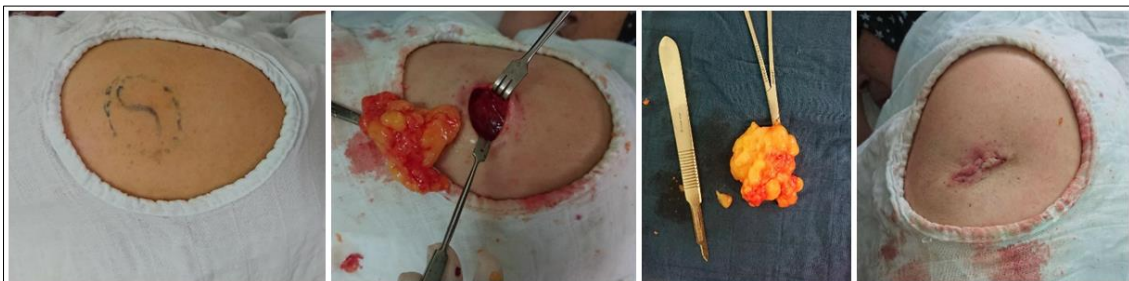


Figure 7: procedure of lipoma surgical excision

All the patients in our series benefited from a follow-up until the healing of the operative wound and the recovery of the anatomopathological results. After that, we could not attest to a documented regular follow-up.

IV. DISCUSSION

Lipomas are benign tumors of adipose tissue consisting of soft, lobulated masses held together with connective tissue and sometimes encapsulated in a thin, fibrous capsule. Lipomas are the most common soft

tissue tumor, occurring in 1% of the population. Onset occurs most frequently between the ages of 40-60 years. Lipomas can be found in nearly any organ throughout the body, but most are subcutaneous in location and are, frequently on the neck and trunk. Only occasionally do they involve the fascia or deep muscular plane. They are soft to firm in texture, may be visibly elevated or detectable by palpation, and have no overlying color change. The 'slippage sign' may be detected as slight lateral movement when gently maneuvering the edges of the mass. Lipomas are usually asymptomatic and may be observed for changes. Indications for removal include a size larger than 5 cm, pain or discomfort, rapid growth, diagnosis clarification, and cosmesis [1].

The etiology of lipomas remains uncertain. One hypothesis suggests trauma causes fat herniation, leading to the formation of pseudo-lipomas. Another posits that trauma stimulates cytokine release, triggering pre-adipocyte differentiation. No definitive link has been found between trauma and lipoma formation. Some studies have established an association between solitary lipomas and gene rearrangements of chromosome 12 as well as abnormalities in the HMGA2-LLP fusion gene [2]. Lipomas may be associated with a variety of diseases, including adipositis dolorosa, Madelung disease, Cowden syndrome and Gardner's syndrome [3].

There are many surgical methods to treat lipomas. There is a desire among patients and clinicians for an alternative method to lipoma excision. The ideal substitute would be a device that is low priced, does not require extensive training and results in minimal scarring.

For pre-operative reason, the borders of the lipoma are marked with a surgical pen, using palpation to detect the edges. The skin is cleansed with chlorhexidine or alternative disinfectant and a ring block is performed using lidocaine with or without epinephrine. The patient is draped to maintain a sterile operating field [1].

- **Incision and Pressure Method:** The surgeon performs a linear incision about 1/3 to 1/2 the diameter of the lipoma, on the skin directly above the lipoma. Usually, Metzenbaum scissors are inserted and spread circumferentially around the tumor in order to break up fibrous bands connecting the fat lobules to the surrounding tissue. Once separated, the lipoma is then expressed applying digital pressure to the edges of the mass. If necessary, a hemostat may be used to provide traction and the incision may be extended to facilitate removal. The resultant cavity is explored to ensure adequate hemostasis and complete removal of fatty tissue. This method of extraction is most effective for encapsulated lipomas but is commonly employed in the removal of nonencapsulated lipomas as well [1].

- **Elliptical Excision Method:** For large or complicated lipomas, elliptical excision may be necessary. This involves removing a footballshaped wedge of skin in order to maximize visualization of the surgical field. Once exposed, the lipoma is dissected away from the surrounding tissue and removed as a single mass or in segments. While this method results in larger scars than previously described methods, elliptical excision may improve cosmesis by removing excess stretched tissue that arises from slow expansion of the fatty tumor. The removed fat may or may not be sent for histopathologic analysis. Potential complications include bleeding, infection, seroma, scarring, pain and recurrence [1].
- **Liposuction:** Typically performed as a cosmetic procedure, liposuction may be used to remove fat. With this technique, subcutaneous fat is removed via a low suction cannula introduced through small incisions made in the skin [4]. Liposuction allows surgeons to make incisions at specific locations to maximize cosmetic outcomes. During a typical liposuction operation, several small about 1 cm, incisions are made at strategic locations surrounding the target area [5]. In wet liposuction, fluid is infused in order to loosen adipose tissue and reduce bleeding. Anesthetics may be included to reduce pain. Dry liposuction describes the removal of fat without injecting fluid to the surgical field [1]. A smaller cannula 1 mm, is first used to create tunnels in the fat [5]. Cannulae of gradually increasing diameter are then employed to aspirate fat. The most important aspect of proper aspiration is the slow, repeated, to-and-fro movement of the cannulae. Deeper layers of fat are aspirated first and then the superficial layers. Multiple different liposuction techniques exist in order to properly remove adipose tissue.
 - **Conventional Liposuction Technique:** The conventional liposuction technique begins by creating relatively large incisions 1-1.5 cm near the target area. A larger cannula 0.6-1 cm in diameter is then introduced into the subcutaneous layer to aspirate the adipose tissue. This process may be performed under "dry" or "wet" conditions, and the patient is typically under general anesthesia. The larger cannulae and larger incisions makes this technique very fast and effective, however, this method requires hospitalization due to the general anesthesia and typically results in more significant scarring [5].
 - **Tumescent Liposuction Technique:** In tumescent liposuction, 4-8 small incisions of 1-3 mm at key locations are performed in the target area. Large quantities about 1-4 L of Klein's fluid, composed of saline, dilute epinephrine and lignocaine, are injected. The saline balloons fat tissue, epinephrine causes vasoconstriction, and lignocaine induces local anesthesia. A microcannula, typically 1.5-3 mm in diameter, is introduced to aspirate adipose

tissue [5, 6]. Since the tumescent technique is one of the only liposuction methods that only requires local anesthesia, the procedure does not require hospital admission and is associated with a rapid postoperative recovery time. However, this technique is particularly expensive to perform, and the removal of adipose tissue is considerably slower than in the conventional technique.

- **Power-Assisted Liposuction:** is similar to the conventional technique, but it includes a reciprocating cannula, which mimics the to-and-fro piercing motion typically made by the surgeon. This technique is especially useful in areas with lower surgical mobility such as umbilical and waist areas, as it allows surgeons to remove fat more completely without expanding the existing incisions. While it increases the ease of the procedure for the surgeon, PAL has the same shortcomings of conventional liposuction, including general anesthesia and a large cannula [5].

V. CONCLUSION

Although lipoma affects a large portion of the population, the majority of removal procedures for lipomas are still performed with a standard set of scalpels and scissors. Unfortunately, the standard methods can result in significant scarring. The most effective adipose tissue removal method that is FDA approved is liposuction, but the required equipment and training are cost prohibitive for many surgeons. New methods are desired to effectively remove an entire lipoma with reduced scarring and costs. Ultrasound and pharmaceutical methods have shown promise, but still require FDA approval. Laser technologies have been

effective for deeper lipomas, but require very large incisions. Our society and the industry would benefit from the development of a novel, directed approach to lipoma excision, which may utilize a combination of components from the many emerging technologies.

REFERENCES

1. Usatine, R. P., Pfenninger, J. L., Stulberg, D. L., & Small, R. (2011). *Dermatologic and cosmetic procedures in office practice*. Elsevier Health Sciences.
2. Italiano, A., Ebran, N., Attias, R., Chevallier, A., Monticelli, I., Mainguené, C., ... & Pedeutour, F. (2008). NF1B rearrangement in superficial, retroperitoneal, and colonic lipomas with aberrations involving chromosome band 9p22. *Genes, Chromosomes and Cancer*, 47(11), 971-977.
3. Pandya, K. A., & Radke, F. (2009). Benign skin lesions: lipomas, epidermal inclusion cysts, muscle and nerve biopsies. *Surgical Clinics*, 89(3), 677-687.
4. Al-basti, H. A., & El-Khatib, H. A. (2002). The use of suction-assisted surgical extraction of moderate and large lipomas: long-term follow-up. *Aesthetic plastic surgery*, 26(2), 114-117.
5. Venkataram, J. (2008). Tumescent liposuction: a review. *Journal of cutaneous and aesthetic surgery*, 1(2), 49-57.
6. Coldiron, B., COLEMAN III, W. P., Cox, S. E., Jacob, C., Lawrence, N., Kaminer, M., & NARINS, R. S. (2006). ASDS guidelines of care for tumescent liposuction. *Dermatologic Surgery*, 32(5), 709-716.