

Organoid Nevus- A Case Series of 8 Patients

Dr. Avanita Solanki, Dr. Anisha Arora*, Dr. Aniket Panchal, Dr. Ishan Pandya, Dr. Neha Nagrani, Dr. Neela Patel, Dr. Jigna Barot

A.M.C MET Medical College, L G Hospital, Maninagar, Ahmedabad, Gujarat, India

DOI: [10.36347/sjams.2019.v07i11.024](https://doi.org/10.36347/sjams.2019.v07i11.024)

| Received: 08.11.2019 | Accepted: 15.11.2019 | Published: 18.11.2019

*Corresponding author: Dr. Anisha Arora

Abstract

Original Research Article

Nevus sebaceous of Jadassohn is a hamartoma composed of abnormal epidermal and dermal components with clinical and histological features that change with aging. It can progress to benign and malignant tumors. Suspected cases of transformation should be clinically monitored and excised. The present study was a cross sectional study. Total 8 patients were studied during 6 months of study period. Out of 8 patients, 4 were male and 4 were female. All patients were followed up and treated accordingly. Neoplastic changes were found in two cases on histopathological examination, one was a Syringocystadenoma papilliferum and other was a Trichoblastoma. Malignant neoplasm on nevus sebaceous occurs in about 2.5% of cases, with basal cell carcinoma accounting for 1.1%. Development of malignancies in nevus sebaceous is a rare phenomenon and decision of excision of the lesion should be made after thorough evaluation of the pros and cons.

Keywords: Nevus sebaceous of jadassohn, Organoid nevus, syringocystadenoma papilliferum, Trichoblastoma, Basal cell carcinoma.

Copyright © 2019: This is an open-access article distributed under the terms of the Creative Commons Attribution license which permits unrestricted use, distribution, and reproduction in any medium for non-commercial use (NonCommercial, or CC-BY-NC) provided the original author and source are credited.

INTRODUCTION

The term 'nevus' has been derived from word 'naevus', which is Latin for 'maternal impression' and has been used to describe a large variety of clinically dissimilar lesions. It is considered synonymous to cutaneous hamartoma. Described in 1895 by Josef Jadassohn, nevus sebaceous of Jadassohn, is a congenital malformation. Also referred to as organoid nevus, it is hamartoma of the pilosebaceous follicular unit [1]. It includes follicular, sebaceous, and apocrine components, and epidermal hyperplasia. Most commonly involving scalp, it may appear on the forehead, face, or neck [1].

It is usually sporadic in occurrence, with an incidence of approximately 0.3% in neonates. It occurs in 3 phases [1]. It undergoes a growth phase during puberty due to hormonal changes in the patient's body. In adulthood, the growths may develop secondary neoplasms [2]. Trichoblastoma is the most common benign neoplasm [3]. Most common malignant tumor seen is basal cell carcinoma[3].

MATERIALS & METHOD

The present study was a hospital based prospective cross sectional study conducted in

department of dermatology at a tertiary care hospital. Written and informed consent with photographs was taken when the cases were seen. Over the period of 6 months, 8 patients of nevus sebaceous of Jadassohn have been studied. All the patients were examined for signs and symptoms of disease on presentation. A detailed history was taken and examination was done. Surgical excisional biopsy was done whenever required and histopathological examination was done.

CLINICAL SUMMARY

8 cases presenting with nevus sebaceous on scalp are described below.

Case 1: A 12 year old female patient presented with asymptomatic 2x2 cm sized nodule on right side parietal area of scalp. The lesion was present since birth as a small nodule, which increased in size through the years to become thicker, larger, verrucous and more nodular during the past 2 years.

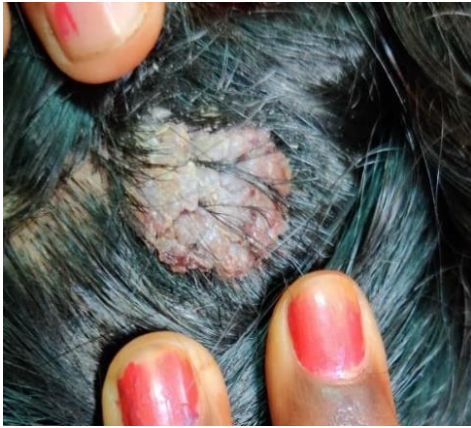

Fig-1: 2x2 cm sized verrucous nodule on right side parietal area of scalp

Case 2: A 20 year old male patient of pemphigus vulgaris presented with single asymptomatic well defined, nodular lesion sized 4x 5 cm on scalp. Patient noticed the lesion since 1 year. The lesion was firm in consistency and was skin colored.

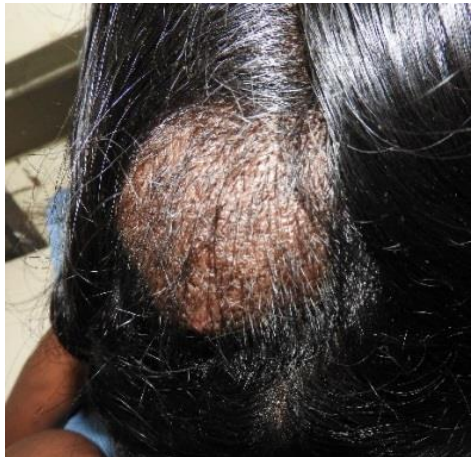

Fig-2: 4x 5 cm sized well defined skin colored nodule over occipital area of scalp

Case 3: An 11 year old female patient presented with asymptomatic skin colored verrucous lesion over scalp since birth. The lesion was biopsied. The histopathological finding was suggestive of nevus sebaceous of Jadassohn with few areas showing glandular papillary proliferation connected to skin surface.

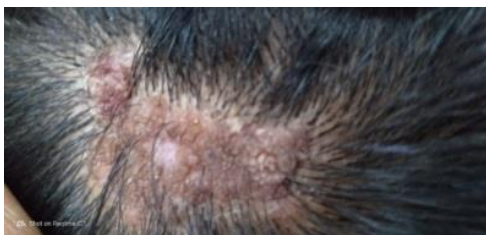

Fig-3: 2x 5 cm sized skin colored verrucous lesion over scalp

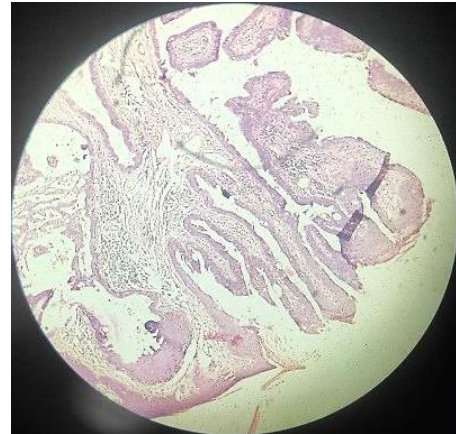


Fig-4: Histopathology showing glandular papillary proliferation connected to skin surface

Case 4: A 28 year old male patient presented with well defined, verrucous plaques of size 3x 4 cm over right parietal region of scalp. As per the history, the lesion was present since birth as yellow- orange, velvety plaque of size 1x2 cm. It had rapidly increased in size, grew thicker in past 10 years. A diagnosis of post pubertal nevus sebaceous was made. Patient came for excision for cosmetic purposes and excision biopsy was done. Biopsy findings were suggestive of nevus sebaceous of Jadassohn.

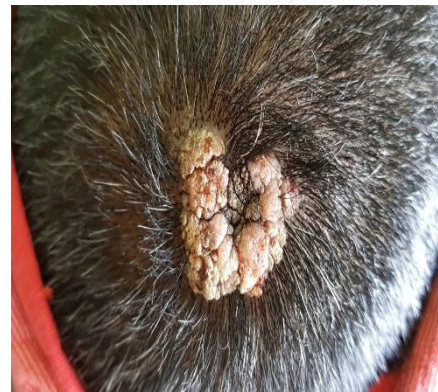

Fig-5: 3x 4 cm size well defined, verrucous plaque over right parietal area of scalp

Case 5: A 60 year old male presented with 2x2 cm sized skin colored, well defined nodular lesion with few areas of brownish crust over scalp since 10 years. The lesion which was initially asymptomatic, presented with severe pruritus since 2 months.

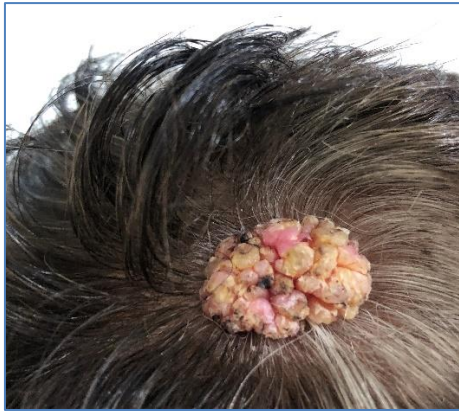

Fig-6: 2x2 cm sized skin colored, well defined, verrucous, nodule over parietal area of scalp

Case 6: A 14 old year male patient presented with single asymptomatic lesion over occipital area of scalp, present since birth. The lesion was flat initially; it increased in size in past few months to develop into a verrucous, firm nodule 1x2 cm in size.

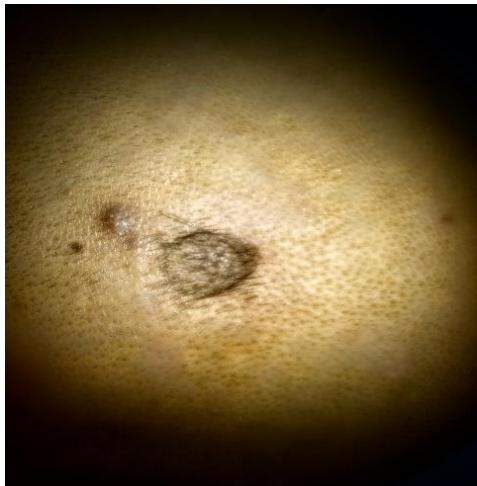

Fig-7: 1x2 cm sized well defined nodule over right parietal area of scalp

Case 7: A 14 year old female patient presented with solitary asymptomatic, verrucous plaque sized 1x1 cm over parietal area of scalp since birth. Excision biopsy was done.

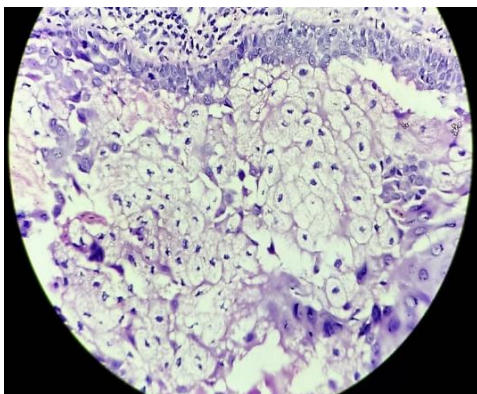


Fig-8: Histopathological appearance suggestive of Nevus sebaceous of Jadassohn

Case 8: A 36 year old female patient presented with single large asymptomatic nodule over forehead since 1 year. Excision of lesion was done. Histopathology finding suggests features of Trichoblastoma along with the finding of Nevus sebaceous of jadassohn.

DISCUSSION

Nevus sebaceous presents as sharply circumscribed, yellow orange hamartoma varying in size from few millimeters to several centimeters. The lesions are usually congenital, solitary and linear in configuration. Scalp is the most common site (50%). Other areas of head and neck may be involved. Trunk involvement occurs in 5% patients or less. Lesions persist throughout the life and alopecia is usually present along with it [1].

Three clinical stages have been described in natural history of nevus sebaceous. The prepubertal stage can be seen as solitary, circumscribed, yellowish orange, smooth velvety plaques on scalp or face which remains unchanged from birth to puberty [2].

The post pubertal stage shows increase in size, thickness and nodularity of the lesion. The lesion now becomes velvety, waxy or greasy and cerebriform. Patients may present for the first time during this stage [2].

The third stage is the stage of neoplastic changes. It is characterised by benign and malignant tumors arising from the nevi. The most common tumors are trichoblastoma and syringocystadenoma papilliferum, each occurring in about 5% of nevus sebaceous. Other benign tumors which occur include syringoma, apocrine cystadenoma, trichilemmoma, spiradenoma, nodular hidradenoma, keratoacanthoma[2]. Malignancy is seen in middle age with risk of less than 5%. Basal cell carcinoma is the commonest. Other tumors include squamous cell carcinoma, sebaceous, apocrine and eccrine carcinoma [2]. The risk for tumor development increases with age. Rarely aggressive malignant and adnexal neoplasms may arise. Multiple internal abnormalities may be associated with nevus sebaceous which makes it imperant to include this entity in epidermal nevus syndromes [1].

Diagnosis of this entity is usually clinical. Differential diagnosis in neonate is aplasia cutis [2, 3]. Other differentials in early lesions are viral warts, juvenile xanthogranuloma and mastocytoma [2, 3]. Later in life, the differentials include congenital nevi, epidermal nevus, seborrheic keratosis, and viral warts [3].

Histopathology in prepubertal lesions is epidermal acanthosis and papillomatous epidermis with

multiple underdeveloped sebaceous glands and hair follicles [1,2].

In post pubertal lesions, epidermis is hyperplastic and more papillomatous. There is massive development of sebaceous glands which are placed high in dermis. The hair roots remain malformed and may be seen as buds of basaloid cells or may disappear [1]. Mature lesions have been described as broad, bald, bumpy (papillomatous) and bubbly (sebaceous)[3].

Treatment can be done for cosmetic purposes. Prophylactic surgical excision should be done in childhood due to its potential for neoplastic transformation. This is of uncertain benefit since most tumors are benign and tend to develop in adulthood [1]. Ablative CO2 laser and photodynamic therapy has been tried. Careful clinical follow up is sufficient with therapeutic excision, wherever required.

CONCLUSION

Study emphasizes the need for regular follow up in patients with nevus sebaceous. Clinician should be suspicious of any changes in the lesion, due to the

risk of malignant transformation. However, development of malignancies in nevus sebaceous is a rare phenomenon and decision of excision of the lesion should be made after thorough evaluation of the pros and cons.

REFERENCES

1. William DJ, Timothy GB, Dirk ME, Epidermal nevi, Neoplasm, and Cysts. Andrew's disease of the skin clinical dermatology. Canada: Saunders Elsevier. 2006.10th edition: 661-662
2. Sacchidanand S, Chetan O, Arun CI, Nevi and Other Developmental Defects. IADVL Textbook of Dermatology. Mumbai, India: Bhalani Publishing House. 2016. 4th ed .290-291
3. Baigrie D, Cook C. Nevus Sebaceous. In Stat Pearls [Internet] 2019 Jan 17. Stat Pearls Publishing.
4. Cribier B, Tumors arising in nevus sebaceous: A study of 596 cases. J Am Acad Dermatol. 2000;42:263
5. Bruna Paninson, Basal Cell Carcinoma on a Nevus sebaceous of Jadassohn: A Case Report. J Clin aesthet Dermatol.2019 Mar; 12(3): 40-43.