

## Pelvic Chondrosarcoma

El Mehdi Ouissaden\*, Issa fathi, Reda Allah Bassir, Moncef Bouftal, Kharmaz Mohamed, Moulay Omar Lamrani, Ahmed El Bardouni, Mustapha Mahfoud, ET Mohamed Saleh Berrada

Department of Orthopedic Surgery, Ibn Sina Hospital, University Mohamed V, Rabat, Morocco

DOI: [10.36347/sjams.2019.v07i11.044](https://doi.org/10.36347/sjams.2019.v07i11.044)

| Received: 06.11.2019 | Accepted: 13.11.2019 | Published: 24.11.2019

\*Corresponding author: El Mehdi Ouissaden

### Abstract

### Case Report

Patient of 34 years who presented for 2 years a pelvic chondrosarcoma grade I (right shutter frame) with endopelvic extension and intimate contact with the nervous vascular pedicle and in whom a surgical carcinological exeresis was indicated with good Evolution Clinical and radiological.

**Keywords:** Chondrosarcoma pelvic surgical carcinological exeresis.

**Copyright © 2019:** This is an open-access article distributed under the terms of the Creative Commons Attribution license which permits unrestricted use, distribution, and reproduction in any medium for non-commercial use (NonCommercial, or CC-BY-NC) provided the original author and source are credited.

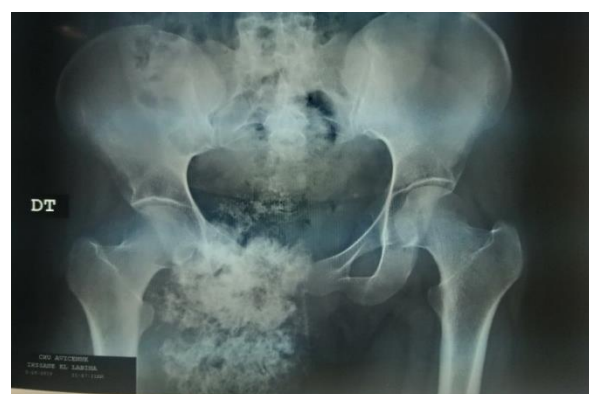## INTRODUCTION

Chondrosarcoma (CS) is a malignant skeletal tumor with cartilaginous differentiation. In terms of incidence, it represents the second most frequent bone tumor in adults [1] and is preferentially located in the pelvis in 22 to 39% of cases 234567. CSs of the pelvic girdle remain asymptomatic in the long-term and may thus be large at the time of diagnosis. From a therapeutic viewpoint, Chondrosarcomas is individualized from other primary skeletal tumors as it is radioresistant and chemoresistant: its only treatment is carcinological surgical exeresis. However, depth in the pelvis, tumor size and its connections with local articular, nervous, vascular and visceral structures very often make carcinological exeresis difficult and require complex reconstructions.

## OBSERVATION

This is a 34-year-old patient with no pathological history who presented for two years a painful tumefaction in the fold of the right groin whose volume increases gradually. A clinical examination found a painful mass consistency firm making 20 cm / 20 adherents to the deep plane without signs of vasculo nerve compression. A radiograph of the pelvis was asked which objected to an osteocondensant image poorly limited with areas of necrosis interesting the obturator frame with extension to the soft parts (figure 1). A CT scan was requested which objectifies a tumoral

process involving the right obturator frame and the posterior wall of the acetabulum with endopelvic extension without invasion of the viscères arriving at the contact of the femoral vascular pedicle in order to invade it (figure 2 and 3). A guided percutaneous biopsy guided scan was performed showing a chondrosarcoma grade I. The diagnosis of CS was confirmed histologically by a subject pathologist specialized in the diagnosis of tumors of the locomotor apparatus. A carcinologic surgical resection (figure 4 and 5) was indicated in collaboration with the visceral vascular surgeons and urologists.



**Fig-1:** Osteocondensant image poorly limited with areas of necrosis interesting the obturator frame with extension to the soft part

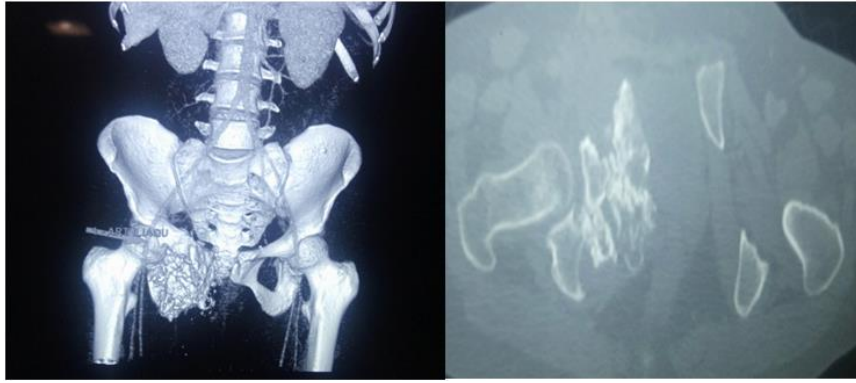


Fig-2: Tumoral process involving the right obturator frame and the posterior wall of the acetabulum with endopelvic extension

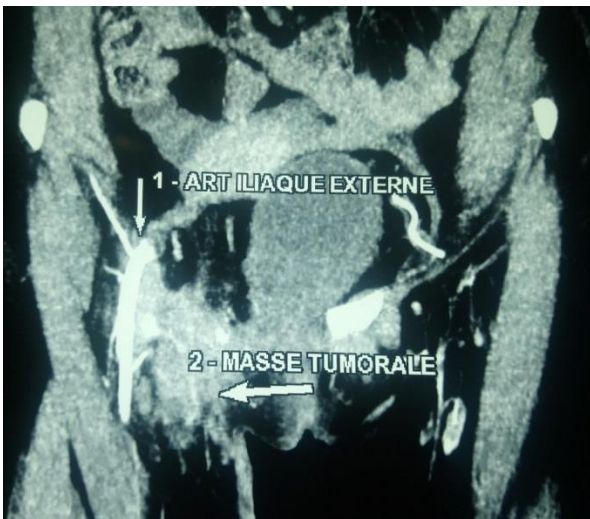


Fig-3: We find that the tumor comes into contact with the femoral pedicle without invading it

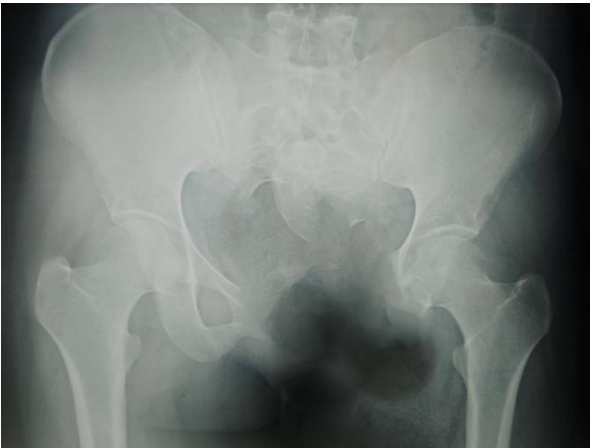

Fig-4: Carcinologic surgical resection of the right obturator frame

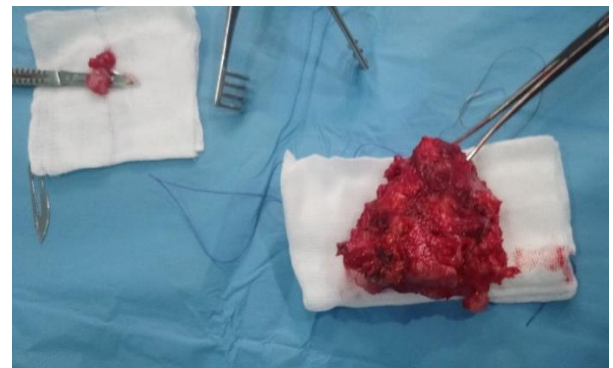


Fig-5: Surgical carcinological exeresis

## DISCUSSION

As observed, CSs are slightly male-predominant tumors, which affect mature adults with peak frequency in the fourth decade .The only treatment of CS, whatever its location, is surgical carcinological exeresis. The survival of patients with CS of the pelvic girdle varies between 51% and 88% at 10 years. It is lower than that of patients with peripheral CS (57% to 83%). Block resection with healthy surgical margins makes it possible to obtain the lowest rate of recurrence and better survival. The rate of healthy margins is very variable in the literature, ranging from 25 to 82%. The two series in the literature assigned to intralesional surgery of pelvic CS both concluded that this technique is ineffective . This is also true for grade 1 CS for which it was originally proposed and which concurs with our observation. Periacetabular location was statistically significant risk factor pejorative for survival. This was also the case for Mochizuki *et al.* [4, 1]. For Sheth *et al.* [2, 4], Zone 3 CS is a poor prognostic factor for survival, and for Ozaki *et al.* [6], zone 3 location carries a greater risk of local recurrence, without the difference being statistically significant. This is probably due to the surgical difficulty in obtaining healthy margins in particular locations, unlike zone 1, which is easily accessible, with the exception of cases of crossing the sacroiliac articulation. In this pelvic location, local recurrences are frequent: their incidence varies from 18 to 45% in the literature, and 31% in our experience. We have observed that the risk of local recurrence is directly related to the quality of initially exeresis margins, which is corroborated by

several studies. According to Pring *et al.* [3, 5], high-grade CSs are significant risk factors for local recurrence. Our study does not confirm these results. Concerning treatment of local recurrence, we observed that patients undergoing surgical exeresis showed better survival than those who were not so treated, but the two study populations were too small in size to provide proof of a statistically significant difference. Influence of surgical technique (amputation versus conservative treatment) on resection margin quality. Two studies have reported the superiority of amputation over conservative surgery. In 1972, Marcove *et al.* [26] observed a statistically significant difference between inter-ilioabdominal disarticulation and local resection for survival criteria. In 2005, Donati *et al.* [3, 3] showed, in a series of 125 pelvic CSs, that radical surgery made it possible to obtain a higher level of healthy surgical margins (80% versus 61% for conservative surgery,  $p = 0.077$ ), and a diminution of the local recurrence level. This result is at the limit of significance. Moreover, these two studies have the same limitations: the age of the record studied that is responsible for insufficiency of preoperative radiological assessment. It indeed appears logical that improvements in imaging techniques provide good assessments of margin quality and tumor resection before the intervention. According to the same reasoning, the use of navigation may improve the quality of exeresis [4, 6, 7]. However, Fiorenza *et al.* [4, 3], in a series of 153 axial and peripheral CSs in 2002, did not manage to show that improved preoperative imaging associated with radical surgery made it possible to improve resection margins, the rate of local recurrence and survival. It thus does not appear possible to conclude on the superiority of amputation both in terms of resection margin quality and survival. Our rare indications of first-intention amputation to date remain bulky tumours with vascular or nerve invasion, infected tumors or on radiation zones, in non-metastatic patients. As already reported in the literature patients treated by first-intention conservative surgery, 92% preserved their limb until the last follow-up. Studies published in the last 10 years objectively quantified the limb preservation level at the latest follow-up after initial conservative surgery, varying from 48 to 90%. The large variability of these data is probably related to the great heterogeneity of these series. Among the reconstructions, the functional results were worse than those concerning the acetabular zone. Zone 1 reconstructions only or isolated zone 3 resections without reconstruction had a better functional prognosis. These results conform with those reported in the literature, acetabular reconstruction remaining the main difficulty of reconstructive pelvic surgery.

## CONCLUSION

Chondrosarcoma (CS) is a primary malignant bone tumor with cartilaginous differentiation. The only available treatment is carcinological surgical resection since the usual adjuvant treatments are ineffective. The pelvic location creates specific technical difficulties both for exeresis and reconstruction. Our objective was to evaluate the carcinological and functional outcomes of inter-ilioabdominal amputation and conservative surgery.

## REFERENCES

1. Unni KK. Chondrosarcoma. In: Dahlin's Bone Tumor. General aspects and data on 11,087 cases, 5th ed. Lippincott-Raven: Philadelphia. 1996; 71–108.
2. Campanacci M.: Bone, Soft Tissue Tumors. New York: Springer, 1986.
3. Henderson ED, Dahlin DC. Chondrosarcoma of bone—a study of two hundred and eighty-eight cases. JBJS. 1963 Oct 1;45(7):1450-8.
4. Huvos AG. In: Bone Tumors: Diagnosis, Treatment and Prognosis. WB Saunders: Philadelphia. 1979: 206–237.
5. Lee FY, Mankin HJ, Fondren G, Gebhardt MC, Springfield DS, Rosenberg AE, Jennings LC. Chondrosarcoma of bone: an assessment of outcome. JBJS. 1999 Mar 1;81(3):326-8.
6. Ozaki T, Hillmann A, Lindner N, Blasius S, Winkelmann W. Chondrosarcoma of the pelvis. Clinical Orthopaedics and Related Research®. 1997 Apr 1;337:226-39.
7. Ucla E, Tomeno B, Forest M. Facteurs du pronostic tumoral dans les chondrosarcomes de l'appareil locomoteur: a propos de 180 cas. Revue de chirurgie orthopédique et réparatrice de l'appareil moteur. 1991;77(5):301-11.
8. Aydinli U, Ozturk C, Yalcinkaya U, Tirelioglu O, Ersozlu S. Limb-sparing surgery for primary malignant tumours of the pelvis. Acta orthopaedica belgica. 2004 Oct;70(5):417-22.
9. Bell RS, Davis AM, Wunder JS, Buconjic T, McGoveran B, Gross AE. Allograft reconstruction of the acetabulum after resection of stage-IIB sarcoma. Intermediate-term results. JBJS. 1997 Nov 1;79(11):1663-74.
10. Enneking WF, Dunham WK. Resection and reconstruction for primary neoplasms involving the innominate bone. The Journal of bone and joint surgery. American volume. 1978 Sep;60(6):731-46.