

## Prostate MRI Parameters - A Systemic Review

Dr. Awadesh Tiwari<sup>1</sup>, Dr. Parama Shivam<sup>2\*</sup>, Dr. Ramya Ganesh<sup>3</sup>

<sup>1</sup>Department of Radiology, Associate Professor, Lumbini Medical College Nepal

<sup>2</sup>Assistant professor, Govt. Medical College THENI, Tamil Nadu, India

<sup>3</sup>Senior lecturer, Department of Periodontia Malabar Dental College Mallapuram, Kerala, India

DOI: [10.36347/sjams.2019.v07i11.059](https://doi.org/10.36347/sjams.2019.v07i11.059)

| Received: 20.11.2019 | Accepted: 27.11.2019 | Published: 30.11.2019

\*Corresponding author: Dr. Awadesh Tiwari

### Abstract

### Original Research Article

This systematic review includes all the articles from 2000 till 2019 with the aim to review the basic components of prostate MRI parameters and to list the sequences available in development to assist in implementation and image quality optimization prostate study. In the preliminary search around 26 papers were found out and 20 were included in this study. Functional techniques like DWI and DCE MRI plays crucial role in determining the stage of prostate cancer.

**Keywords:** Prostate cancer, MRI parameters, DWI, parameters.

**Copyright © 2019:** This is an open-access article distributed under the terms of the Creative Commons Attribution license which permits unrestricted use, distribution, and reproduction in any medium for non-commercial use (NonCommercial, or CC-BY-NC) provided the original author and source are credited.

## INTRODUCTION

Prostate MRI has proven to be the most effective tool to diagnostic and management pathway in men at risk of prostate cancer [1, 2]. The Excellent Resolution and High signal to noise ratio achieved by MRI in combination with the functional measurements of water diffusion and contrast enhancements improves insight into the histopathology of the prostate [2].

MRI Prostate allows for risk stratification of men at risk for prostate cancer including its ability to predict cancer aggressiveness prior to biopsy [2].

## AIM

To review the basic components of Prostate MRI Parameters. To list Sequences available and in development to assist in the implementation and image quality optimization Prostate MRI study.

## METHODOLOGY

A detailed research was done from “Google search”, “Wiley”, “Pubmed” etc using keywords MRI parameters, prostate cancer etc. 26 articles were found, out of which 20 articles were selected for this systematic review.

### Prostate MRI techniques

Under this topic, we will cover technical points such as equipment, patient preparation, basic and advanced parameters

### Equipment specification

Prostate MRI can be obtained with a conventional 1.5 tesla or high field 3.0 magnets with or without an endo rectal coil [2].

3.0T magnet provides twice the SNR compared to 1.5T systems which provide improved spatial and temporal resolution and results in improved image quality [5, 6].

Endo rectal coil should be considered in older 1.5T systems for better results [8, 9]. Endo rectal coil is not required in 3T systems for lesion detection [10, 11].

The use of Endo rectal coil during image acquisition may not necessarily be enough to obtain ideal prostate MRI [15, 18]. In such cases, use of Liquid barium or perfluoro carbon instead of air for coil insufflation, since air can induce susceptibility artifacts on Diffusion weighted Image [15].

Use of ERC is more time consuming and costly since it requires on site physician and it causes discomfort to the patients during coil placement [15].

### Patient preparation

Patients should be asked to empty their bowel during Prostate MRI examination [1, 2]. The reason is it may cause susceptibility artifact in the image due the presence of rectal gas especially during diffusion

weighted sequence. This is of paramount importance to achieve good image quality [5, 6].

### Parameters

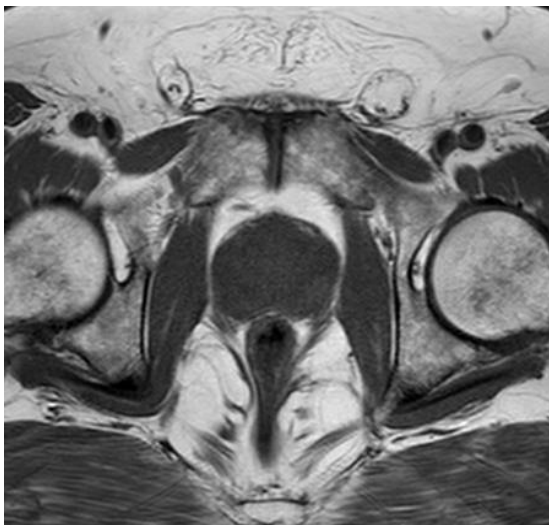
Prostate MRI is usually termed as Multi parametric MRI because it incorporates the combined use of anatomic and functional pulse sequences [9].

Anatomic pulse sequence includes T1 and T2 weighted MRI [10]. T1 weighted is not used for lesion detection but it is used to document biopsy related residual hemorrhage which can mimic prostate cancer [12]. T1 weighted should be acquired in axial plane using spin or gradient echo sequences. Its acquisition is inherent for dynamic contrast enhanced imaging [17].

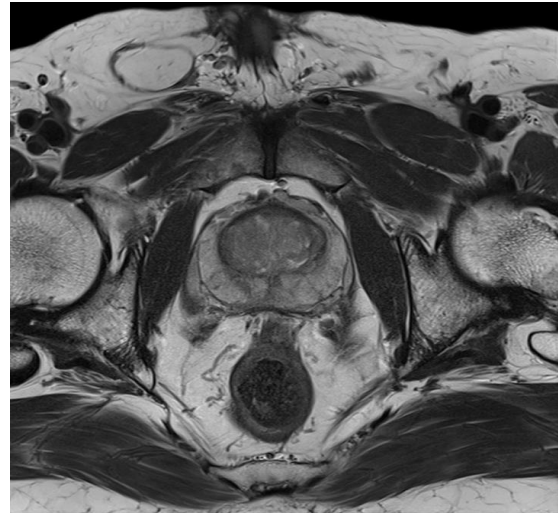
T2 weighted is the workhouse of Prostate MRI because the anatomic details can be best delineated in this protocol mainly in axial plane<sup>18</sup>. T2 weighted should be acquired in all 3 planes using fast/turbo spin echo sequences.

### Basic Parameters are

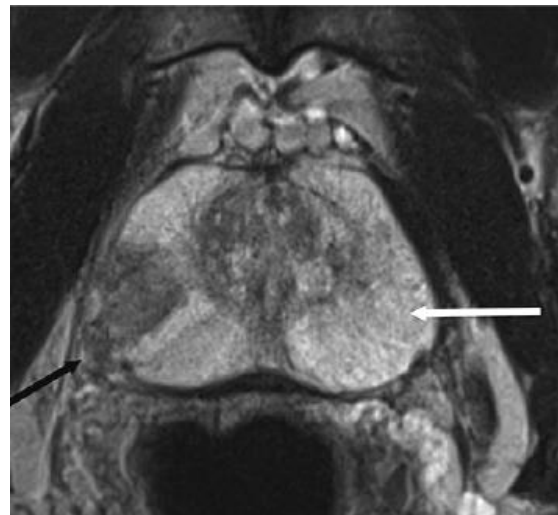
- Slice Thickness 3-4mm
- Field of View- 12-20cm covering entire prostate and seminal vesicle
- In Plane dimension <0.7mm Phase x <0.4mm Frequency



Normal Appearance of prostate T1 Weighted Axial Image



Normal Appearance T2 weighted



Tumor Appearance T2 weighted

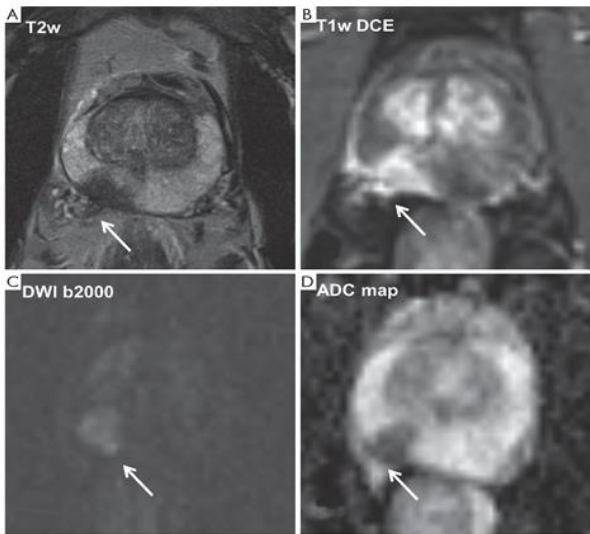
2. Functional pulse sequences includes diffusion weighted MRI (DW MRI) and Dynamic contrast enhanced MRI (DCE MRI)

DW MRI evaluates the Brownian water molecules within tissue, which is restricted in cancer-harboring tissues [15]. DW MRI has 2 key components, apparent diffusion coefficient (ADC) maps and High B Value DW MRI [18]. B Value is a factor related to the degree which an acquisition is diffusion weighted. 2 or more B values are needed to calculate ADC maps from DW MRI [17]. The ADC Map and High B value DW image are used in conjunction in a qualitative manner [16].

Technical specification of image acquisition for DW MRI jelle *et al.* 2012

- Echo time (TE)- <90 msec, Repetition time (TR) >3000 msec
- Slice thickness- <4mm without gap
- Field of View- 16-20cm covering entire prostate and seminal vesicle

- In plane dimension- <2.5mm (Phase and Frequency)



DCE MRI evaluates the vascularity of the prostate in order to identify permeability changes related to the tumor angiogenesis [6]. DCE MRI consists of T1 weighted images obtained before, during and after injection of gadolinium based contrast agent (GDCA) [8]. DCE MRI is the most invasive component of prostate MRI since it employs intravenous GBCA injection [9].

Technical specification of image acquisition for DCE MRI parkin *et al.* 2009

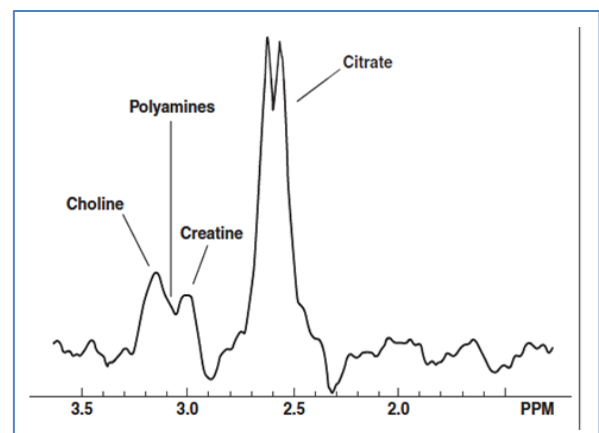
- Echo time (TE)- <100 msec, Repetition time (TR) >5 msec
- Slice thickness- 3mm without gap
- Field of View- 12-20cm covering entire prostate and seminal vesicle
- In plane dimension- <2mm (Phase and Frequency)
- Scanning time should be less than 2 minutes
- GBCA dose : 0.1 mmol/kg, Injection rate 2-3cc/sec

MR Spectroscopic imaging (MRS) is emerging as useful technique for evaluating the extent and aggressiveness of primary and recurrent Prostate cancer [2]. It is the only non-invasive method of studying chemical metabolites but is not clinically used to

diagnose Prostate cancer and it's still in research stage [2].

- Choline (Cho), Creatine (Cr), citrate (Cit) are the metabolites measured with proton spectroscopy in prostate
- Cho - Cell membrane components that is increased in high turnover states , Normal peak at 3.2 ppm
- Cit – biochemical molecule produced by normal prostate tissue. Normal peak at 2.6 ppm
- Cr is involved in energy metabolism. Normal peak at 3.0 ppm

MRS evaluation is mainly based on Choline peak elevation and Choline- Creatine ratios.

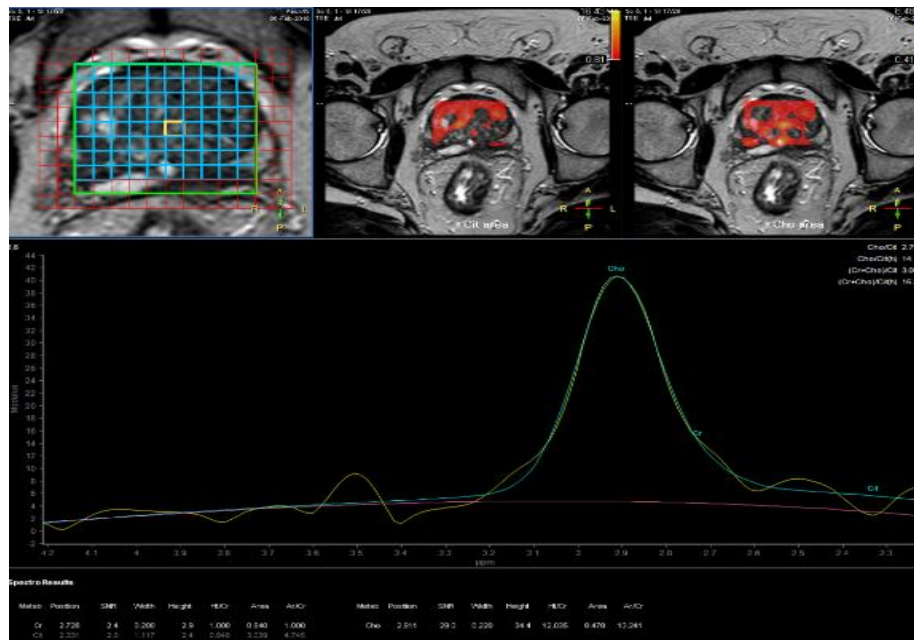


**Normal Appearance of Spectroscopy**

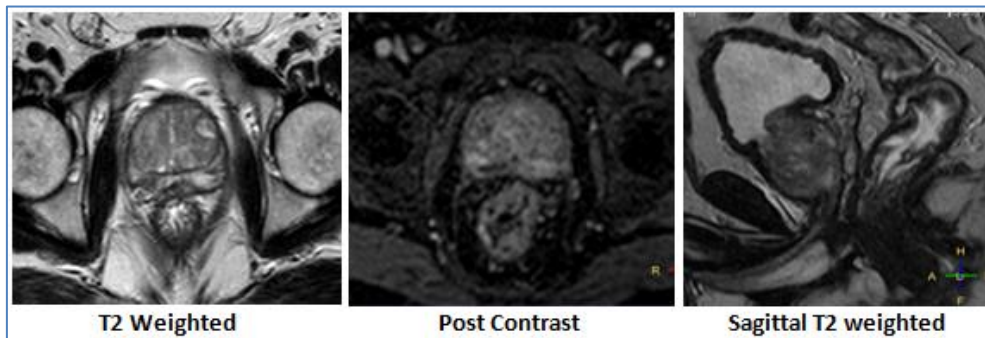
Technical specification of image acquisition for DCE MRI

Axial Probe 2d SI PRESS Sequence is used in MR Spectroscopy protocol

- Echo time (TE)- 144 msec, Repetition time (TR) 1000 msec
- Slice thickness- 10mm without gap
- NEX- 1.00
- Field of View- 12-20cm covering entire prostate and seminal vesicle



This MR image is suggestive of malignant lesion involving transitional zone of left mid zone with no capsular breach or pelvic adenopathy



## CONCLUSION

The results obtained by MRI Prostate represent a significant addition to traditional imaging techniques for the management of prostate cancer. Parameters used to obtain high resolution images plays a major role in diagnosing prostate cancer. Functional techniques like DWI and DCE MRI plays crucial role in determining the stage of prostate cancer.

## REFERENCES

- Jemal A, Siegel R, Ward E, Hao Y, Xu J, Thun MJ. Cancer statistics, 2009. *CA: a cancer journal for clinicians*. 2009 Jul;59(4):225-49.
- Carter HB, Piantadosi S, Isaacs JT. Clinical evidence for and implications of the multistep development of prostate cancer. *The Journal of urology*. 1990 Apr 1;143(4):742-6.
- Parkin DM, Bray FI, Devesa SS. Cancer burden in the year 2000. The global picture. *European journal of cancer*. 2001 Sep 1;37:4-66.
- Dickinson L, Ahmed HU, Allen C, Barentsz JO, Carey B, Futterer JJ, Heijmink SW, Hoskin PJ, Kirkham A, Padhani AR, Persad R. Magnetic resonance imaging for the detection, localisation, and characterisation of prostate cancer: recommendations from a European consensus meeting. *European urology*. 2011 Apr 1;59(4):477-94.
- Franiel T, Stephan C, Erbersdobler A, Dietz E, Maxeiner A, Hell N, Huppertz A, Miller K, Strecker R, Hamm B. Areas suspicious for prostate cancer: MR-guided biopsy in patients with at least one transrectal US-guided biopsy with a negative finding—multiparametric MR imaging for detection and biopsy planning. *Radiology*. 2011 Apr;259(1):162-72.
- Kitajima K, Kaji Y, Fukabori Y, Yoshida KI, Sukanuma N, Sugimura K. Prostate cancer detection with 3 T MRI: comparison of diffusion-weighted imaging and dynamic contrast-enhanced MRI in combination with T2-weighted imaging. *Journal of Magnetic Resonance Imaging: An Official Journal of the International Society for Magnetic Resonance in Medicine*. 2010 Mar;31(3):625-31.
- Futterer JJ, Heijmink SW, Scheenen TW, Veltman J, Huisman HJ, Vos P, de Kaa CA, Witjes JA, Krabbe PF, Heerschap A, Barentsz JO. Prostate cancer localization with dynamic contrast-enhanced MR imaging and proton MR

- spectroscopic imaging. *Radiology*. 2006 Nov;241(2):449-58.
8. Tanimoto A, Nakashima J, Kohno H, Shinmoto H, Kuribayashi S. Prostate cancer screening: the clinical value of diffusion-weighted imaging and dynamic MR imaging in combination with T2-weighted imaging. *Journal of Magnetic Resonance Imaging: An Official Journal of the International Society for Magnetic Resonance in Medicine*. 2007 Jan;25(1):146-52.
  9. Van As NJ, de Souza NM, Riches SF, Morgan VA, Sohaib SA, Dearnaley DP, Parker CC. A study of diffusion-weighted magnetic resonance imaging in men with untreated localised prostate cancer on active surveillance. *European urology*. 2009 Dec 1;56(6):981-8.
  10. Zelhof B, Pickles M, Liney G, Gibbs P, Rodrigues G, Kraus S, Turnbull L. Correlation of diffusion-weighted magnetic resonance data with cellularity in prostate cancer. *BJU international*. 2009 Apr;103(7):883-8.
  11. Tamada T, Sone T, Jo Y, Toshimitsu S, Yamashita T, Yamamoto A, Tanimoto D, Ito K. Apparent diffusion coefficient values in peripheral and transition zones of the prostate: comparison between normal and malignant prostatic tissues and correlation with histologic grade. *Journal of Magnetic Resonance Imaging: An Official Journal of the International Society for Magnetic Resonance in Medicine*. 2008 Sep;28(3):720-6.
  12. Turkbey B, Shah VP, Pang Y, Bernardo M, Xu S, Kruecker J, Locklin J, Baccala Jr AA, Rastinehad AR, Merino MJ, Shih JH. Is apparent diffusion coefficient associated with clinical risk scores for prostate cancers that are visible on 3-T MR images?. *Radiology*. 2011 Feb;258(2):488-95.
  13. Ito Y, Nakanishi K, Narumi Y, Nishizawa Y, Tsukuma H. Clinical utility of apparent diffusion coefficient (ADC) values in patients with prostate cancer: can ADC values contribute to assess the aggressiveness of prostate cancer?. *Journal of magnetic resonance imaging*. 2011 Jan;33(1):167-72.
  14. Hambrock T, Somford DM, Huisman HJ, van Oort IM, Witjes JA, Hulsbergen-van de Kaa CA, Scheenen T, Barentsz JO. Relationship between apparent diffusion coefficients at 3.0-T MR imaging and Gleason grade in peripheral zone prostate cancer. *Radiology*. 2011 May;259(2):453-61.
  15. Villeirs GM, Oosterlinck W, Vanherreweghe E, De Meerleer GO. A qualitative approach to combined magnetic resonance imaging and spectroscopy in the diagnosis of prostate cancer. *European journal of radiology*. 2010 Feb 1;73(2):352-6.
  16. Scheenen TW, Klomp DW, Röhl SA, Fütterer JJ, Barentsz JO, Heerschap A. Fast acquisition-weighted three-dimensional proton MR spectroscopic imaging of the human prostate. *Magnetic Resonance in Medicine: An Official Journal of the International Society for Magnetic Resonance in Medicine*. 2004 Jul;52(1):80-8.
  17. Girouin N, Mège-Lechevallier F, Senes AT, Bissery A, Rabilloud M, Maréchal JM, Colombel M, Lyonnet D, Rouvière O. Prostate dynamic contrast-enhanced MRI with simple visual diagnostic criteria: is it reasonable?. *European radiology*. 2007 Jun 1;17(6):1498-509.
  18. Yoshizako T, Wada A, Hayashi T, Uchida K, Sumura M, Uchida N, Kitagaki H, Igawa M. Usefulness of diffusion-weighted imaging and dynamic contrast-enhanced magnetic resonance imaging in the diagnosis of prostate transition-zone cancer. *Acta radiologica*. 2008 Jan 1;49(10):1207-13.
  19. Hövels A, Heesakkers RA, Adang EM, Jager GJ, Strum S, Hoogeveen YL, Severens JL, Barentsz JO. The diagnostic accuracy of CT and MRI in the staging of pelvic lymph nodes in patients with prostate cancer: a meta-analysis. *Clinical radiology*. 2008 Apr 1;63(4):387-95.
  20. Haider MA, Chung P, Sweet J, Toi A, Jhaveri K, Ménard C, Warde P, Trachtenberg J, Lockwood G, Milosevic M. Dynamic contrast-enhanced magnetic resonance imaging for localization of recurrent prostate cancer after external beam radiotherapy. *International Journal of Radiation Oncology\* Biology\* Physics*. 2008 Feb 1;70(2):425-30.