

Sonographic Estimation of Gestational Age using Fetal Orbital Measurements

Awadia Gareeballah^{1*}, Elmigdad Abdalsmeea Salih Fadul², Naglaa Alsir Mohammed^{1,3}, Ibrahim Mohamed Mohamed Daoud⁴, Sara Khalifa⁴

¹Faculty of Radiology Science and Medical Imaging, AlzaiemAlazhari University, Khartoum, Sudan

²National Ribat University, Faculty of Radiological and Nuclear Medicine Science, Nile Street Burri, Postal Code 11111, Khartoum – Sudan

³Al-Ghad International Medical Sciences College KSA

⁴Alneeelen University –Sudan- Faculty of Medicine College of Medical Radiological Sciences, Sudan University of science and Technology, Khartoum, Sudan

*Corresponding author: Awadia Gareeballah

| Received: 11.05.2019 | Accepted: 16.05.2019 | Published: 21.05.2019

DOI: [10.36347/sjams.2019.v07i05.016](https://doi.org/10.36347/sjams.2019.v07i05.016)

Abstract

Original Research Article

This was cross sectional study done in Khartoum state- Sudan in the period from July to December 2018. The aimed of the study was to measure of Fetal Binocular Distance (BOD), Ocular Distance (OD) and Interocular Distance (IOD) in Second & Third Trimester of Pregnancy in correlation to Gestational Age using Ultrasonography. 107 normal singleton pregnant women in Second & Third trimester of Pregnancy with a mean age of (26.5 years) were included. The data were collected by data collection sheet including the study variables which were gestational age (last menstrual period, femur length, biparietal diameter head circumference, abdominal circumference), ocular diameter (OD), Binocular distance (BOD) in mm, interorbital diameter (IOD), fetal weight in gram after the verbal consent was taken from all pregnant women then analyzed by statistical package for social sciences. The study found strong significant correlations between BOD per mm, OD per mm and IOD per mm with gestational age (LMP, FL, BPD, AC and HC). BOD had greater values than did the IOD and OD. The BOD displayed a greater value of correlation coefficient ($r = 0.879, 0.884, 0.886, 0.877$ and 0.885 respectively), OD with above mention fetal biometry respectively ($r = 0.800, 0.800, 0.800, 0.796$ and 0.796 respectively) and IOD ($r = 0.593, 0.605, 0.591, 0.607, 0.796$ with above mention fetal biometry respectively) p value of all <0.01 . The study concluded fetal orbital measurement was interested and useful in predicting gestational age, therefore the study recommended using orbital measurements to estimate fetal age.

Key word: Ultrasound, BOD (Binocular Distance), IOD (Interocular Distance) and OD (Ocular Distane).

Copyright © 2019: This is an open-access article distributed under the terms of the Creative Commons Attribution license which permits unrestricted use, distribution, and reproduction in any medium for non-commercial use (NonCommercial, or CC-BY-NC) provided the original author and source are credited.

INTRODUCTION

Ocular ultrasound, also known as ocular echography, "echo," or a B-scan, is a quick, non-invasive test routinely used in clinical practice to assess the structural integrity and pathology of the eye. It can provide additional information not readily obtained by direct visualization of ocular tissues, and it is particularly useful in patients with pathology that prevents or obscures ophthalmoscopy (e.g., large corneal opacities, dense cataracts, or vitreous hemorrhage). The fetal face can be studied with ultrasound very early in gestation. Several elements of the normal anatomy (orbits, forehead) can be identified as early as the 12th week of gestation [1].

Before 14 weeks, the soft tissues of the face are too thin to be reliably imaged with current ultrasound equipment. After this time, forehead, orbits, nose, lips, and ears can be consistently identified and

studied in detail[1]. A systematic approach to the examination of the fetal face should include sagittal, axial, and coronal planes[1].

Orbital architecture has become increasingly important in the evaluation of gestational age assessment. Sonographic evaluation of the fetal orbits is best obtained in the axial or coronal views, where one can confirm the presence of both orbits, evaluating their sizes, shapes, and the distance between them. The sagittal view may help to evaluate abnormal anterior displacement of the globes (proptosis or exorbitism). The orbits should be symmetrical in size and the outer and inner interorbital distances within a normal range [2].

The Fetal orbital measurements are the most interesting and useful parameters in predicting gestational age, such as, Binocular distance (BOD), the ocular diameter and intraocular distance. (i.e. BOD)

draws maximum attention due to its accuracy and convenience. correlation was found to exist between binocular diameter and gestational age[3].

Objective

To estimate gestational age in second and third trimester of pregnancy using orbital measurements.

MATERIALS AND METHODS

This was a cross-sectional study deal with measurements of binocular distance and other orbital parameters and correlate with gestational age in second and third trimester of pregnancy in Sudanese. It was conducted at different medical centers of Sudan republic, during the period from July to September 2018. The target population amount for this study was 107 pregnant in Second and Third Trimester of Pregnancy. All women with normal singleton pregnancies in second and third trimester, with reliable LMP after 12th weeks of gestation and complete visualization of binocular distance were included while all patients with multiple pregnancies, fetal congenital anomaly, poly or oligohydramnios and pregnancy complicated by premature ruptures of the membrane were excluded from the study or with any abnormalities that may be effect fetal Binocular dimeter. The data were collected by data collection sheet design for study and including study variables.

The patient was examined in supine position, with the abdomen exposed after applying a sonic

coupling agent. When scanning inferior to or below the cerebellar plane, the orbits may be visualized. It is important to note that both fetal orbits (and eyes) are present and that the spacing between both orbits appears normal [4]. The fetal orbits are observed and measured in two planes: (1) a coronal scan posterior to the glabellar alveolar line and (2) a transverse scan at a level below the biparietal diameter (along the orbito-meatal line). In these views, the individual orbital rings, nasal structures, and maxillary processes can be identified. When the fetus is in an occipitoposterior position (fetal orbits directed up), orbital distances can also be determined. In this view, the orbital rings, lens, and nasal structures may be demonstrated. Measurements of the inner orbital distance (IOD) should be made from the medial border of the orbit to the opposite medial border, and the outer orbital (or binocular) distance (OOD) should be measured from the lateral border of one orbit to the opposite lateral wall [4].

RESULTS AND DISSCUSION

The study revealed that the minimum - maximum and mean of GA LMP,FL BPD,AC,HC ,Fetal weight, BOD, OD and IOD were 14.0 -38.28 and mean 26.21, 15.14-38 and mean 26.14, 14.85-36.85 and means 26.05, 14.57-37.42 and mean 25.87,15.14-37.42 and means 25.94 weeks, 109-3141 gram and mean 1132 kg, 20-66 mm and means 41.78mm,6-24 mm and mean 13.88 and 3-33mm with mean 14.02 mm respectively Table (1).

Table-1: Descriptive statistic for GA LMP, GA BPD, GA AC, GA HC and BOD, IOD, OD per mm.

Variables	N	Minimum	Maximum	Mean	Std. Deviation
GA FL	107	15.14	38.00	26.1469	6.37050
GA BPD	107	14.85	36.85	26.0543	6.27368
GA AC	107	14.57	37.42	25.8744	6.23540
GA HC	107	15.14	37.42	25.9429	6.34801
Weight	107	109	3142	1123.24	873.791
BOD\mm	107	20.0	66.0	41.786	10.0167
OD\mm	106	6.0	24.0	13.881	3.4110
IOD	106	3.00	33.00	14.0217	5.85045
Valid N (listwise)	106				

The study showed strong linear relationship between BOD per mm with all biometry (GA per weeks for LMP, FL, BPD, AC HC and fetal weight) the generally linear relationship between BOD and other

variables was very stronger ($R^2 = 0.77$), ($R^2=0.78$), ($R^2 = 0.78$), ($R^2 = 0.77$), ($R^2 = 0.78$) and ($R^2= 0.67$) respectively. Figure (1-6).

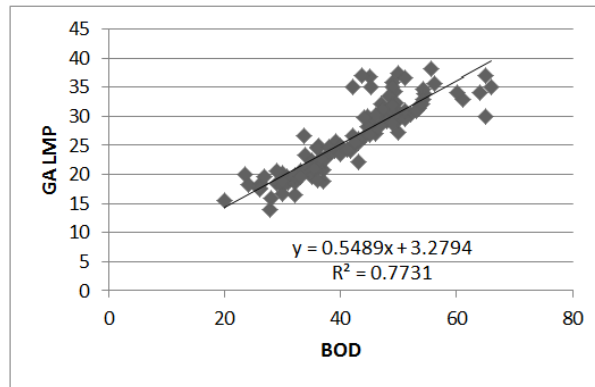


Fig-1: Scatterplot shows linear relationship between BOD and GA LMP ($R^2= 0.77$)

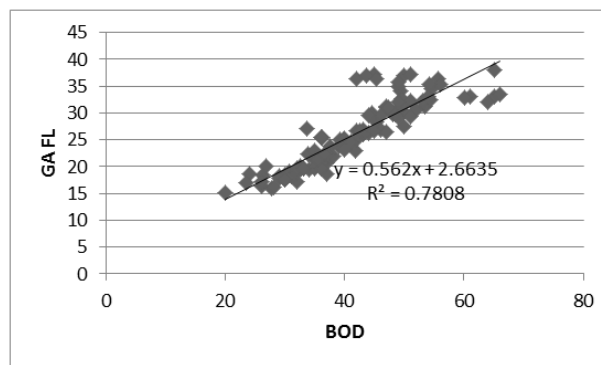


Fig-2: Scatterplot shows linear relationship between BOD and GA FL ($R^2= 0.78$)

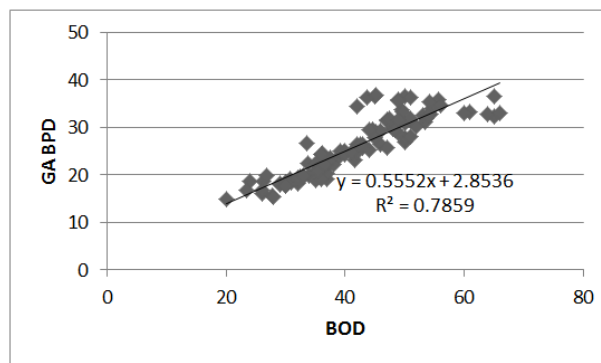


Fig-3: Scatterplot shows linear relationship between BOD and GA BPD ($R^2= 0.785$)

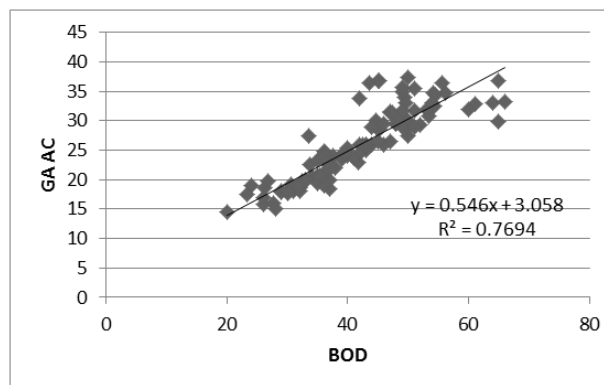


Fig-4: Scatterplot shows linear relationship between BOD and GA AC ($R^2= 0.77$)

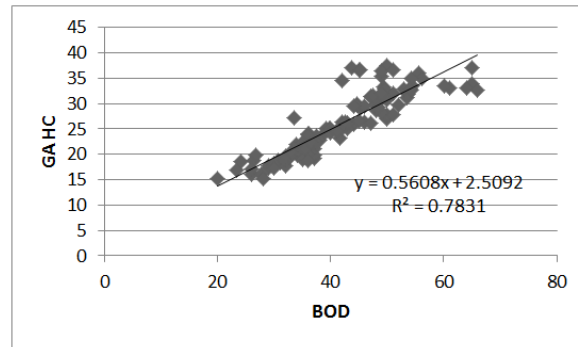


Fig-5: Scatterplot shows linear relationship between BOD and GA HC (R²= 0.78)

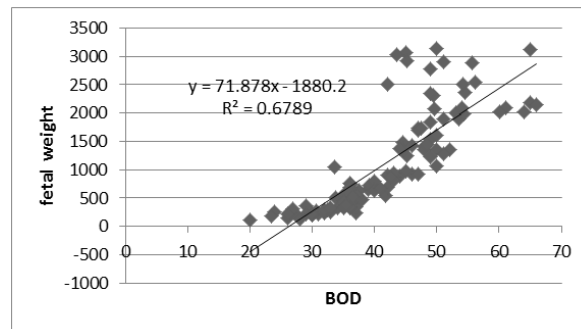


Fig-6: Scatterplot shows linear relationship between BOD and fetal weight (R²= 0.67)

Strong significant correlation between BOD per mm and the other parameters, OD per mm and the other parameters and between IOD per mm and other parameters (GA LMP, GA FL, GA BPD, GA AC and GA HC). BOD had greater values than did the IOD and OD. Interestingly, the BOD displayed a greater value of correlation coefficient ($r= 0.879, 0.884, 0.886, 0.877$ and 0.885 respectively), than did ocular distance OD with above mention fetal biometry respectively ($r= 0.800, 0.800, 0.800, 0.796$ and 0.796 respectively) and the OD had greater values of correlation coefficient than did the IOD ($r = 0.593, 0.605, 0.605, 0.591, 0.607$ and 0.796 respectively), p value of all <0.01 , the finding of this study agree with a variety of previous studies, one of them study done by ISLAM *et al.* [5]: The

correlation between BOD in cm and GA in weeks was highly significant ($r = 0.973; p < 0.001$), also these findings agree with Goldstein *et al.* [6] was observed a linear growth function between gestational age (GA) and orbital diameter ($r = 0.94; p < 0.00001$), Significant correlation was also found between femoral length (FL) and orbital diameter ($r = 0.95; p < 0.00001$ and orbital area ($r = 0.93; p < 0.00001$). A linear growth function was observed between orbital diameters and BPD ($r=0.94; p < 0.00001$) and head circumference ($r=0.95; p < 0.00001$). also this study in line with a study done by Velasco-Annis *et al.* using volumetric MRI reconstruction BOD in mm had the greatest correlation with GA per week ($r= 0.9552$)[6-8] Table (2).

Table-2: Correlation between GA LMP, GA BPD, GA AC, GA HC and BOD, IOD, OD per mm

		GA LMP	GA FL	GA BPD	GA AC	GA HC
BOD \mm	Pearson Correlation	.879**	.884**	.886**	.877**	.885**
	Sig. (2-tailed)	.000	.000	.000	.000	.000
OD \mm	Pearson Correlation	.800**	.800**	.800**	.796**	.796**
	Sig. (2-tailed)	.000	.000	.000	.000	.000
IOD \mm	Pearson Correlation	.593**	.605**	.605**	.591**	.607**
	Sig. (2-tailed)	.000	.000	.000	.000	.000

Multiple linear regression was done to predict for estimate of BOD using IOD and orbital diameter (OD) and shows that there was strong linear relationship ($R^2=1.00$) ($p < 0.01$) with standard error of estimation (0.000), as seen in the following regression formula:

$$BOD\ mm = 1x\ IOD + 2x\ OD + 1.06\ (R^2=1.00, \text{ standard error of estimate} = 0.000)[1].$$

From this formula the study reveal that the IOD equal to orbital distance (OD) each of them was $1/3$ BOD, This results go online with literature whom state that as a rule of thumb, the interorbital distance should be roughly equal to the ocular diameter however specific biometric charts are available[8,9]Table (3).

Table-3: Regression equation to predict BOD using IOD and OD per mm

Model	Unstandardized Coefficients		Standardized Coefficients	t	Sig.	R ²	Std. Error of the Estimate
	B	Std. Error	Beta				
1	(Constant)	1.066	.000		.000	1.000	0.0000
	IOD	1.000	.000	.581	2.892	.000	
	OD mm	2.000	.000	.678	3.373	.000	

a. Dependent Variable: BOD mm

CONCLUSION

The study concluded that excellent significant correlations was found to exist between binocular diameter, inter-ocular diameter, and orbital diameter considering standard parameters for predicting gestational age and it can be used as other parameters for estimation of GA.

The study clarify that significant relationship found between BOD, IOD and OD as demonstrate by the regression formulae which should be considered an optimal model for predicting BOD from IOD and OD

(R² = 1.00, P <0.001) with standard error of mean = 0.000:

$$\text{BOD mm} = 1 \times \text{IOD} + 2 \times \text{OD} + 1.06. \text{ (1)}$$

The study showed stronger correlation between BOD and GA LMP than between OD and IOD with GA LMP.

Recommendations

Beside that further researches advised with increases sample size to obtain more precise results.

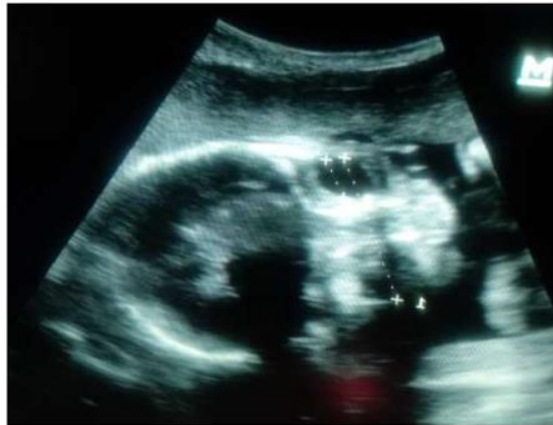

Image-1: Pregnant women (27) years, Frontal ultrasound view shows binocular distance (4.25 cm) and ocular diameter (1.12 cm) in 31 week of GA

REFERENCES

1. Benacerraf BR, Frigoletto Jr FD, Bieber FR. The fetal face: ultrasound examination. *Radiology*. 1984 Nov;153(2):495-7.
2. Carol M. Rumack, Stephanie R. Wilson, J. William Charboneau, MD, FACR Deborah Levine, MD, FACR. *Diagnostic Ultrasound*. 4th ed. Philadelphia, Mosby, Inc. 2005.
3. Betty Bates Tempkin. *Pocket Protocols For Ultrasound Scanning*, 2nd ed. Missouri, Elsevier Inc.2007.
4. Sandra L. Hagen-Ansert, *Textbook of Diagnostic Sonography*, 7th ed, volume one. Elsevier Mosby. 2012:1162.
5. Islam MM, Akter T, Islam S, Alam F, Goswami U, Al-Azad SU, Selim S. Ultrasonographic Evaluation of Foetal Binocular Distance in Second & Third Trimester of Pregnancy and Correlation with Gestation Age. *Journal of Current and Advance Medical Research*. 2016 Aug 20;3(1):10-5.
6. Goldstein I, Tamir A, Zimmer EZ, Itskovitz-Eldor J. Growth of the fetal orbit and lens in normal pregnancies. *Ultrasound in Obstetrics and Gynecology*. 1998 Sep 1;12(3):175-9.
7. Velasco-Annis C, Gholipour A, Afacan O, Prabhu SP, Estroff JA, Warfield SK. Normative biometrics for fetal ocular growth using volumetric MRI reconstruction. *Prenatal diagnosis*. 2015 Apr 1;35(4):400-8.
8. Paquette LB, Jackson HA, Tavaré CJ, Miller DA, Panigrahy A. In utero eye development documented by fetal MR imaging. *American Journal of Neuroradiology*. 2009 Oct 1;30(9):1787-91.
9. Rosati P, Guariglia L. Early transvaginal fetal orbital measurements: a screening tool for aneuploidy?. *Journal of ultrasound in medicine*. 2003 Nov;22(11):1201-5.