

First Metatarsal Chevron Percutaneous Osteotomy

El Mehdi Ouissaden*, Issa Fathi, Kharmaz Mohamed, Moulay Omar Lamrani, Ahmed El Bardouni, Mustapha Mahfoud, Mohamed Saleh Berrada

Service De Chirurgie Orthopédique Et Traumatologie, CHU Ibn Sina, Rabat, Morocco

DOI: 10.36347/sjams.2019.v07i09.013

| Received: 05.09.2019 | Accepted: 11.09.2019 | Published: 18.09.2019

*Corresponding author: El Mehdi Ouissaden

Abstract

Original Research Article

We present the results of a study involving 24 patients (30 feet) operated for hallux valgus by MICA technique between January 2010 and December 2017. This is a retrospective study. There are 14 women to 24 men with a mean age of 36 years. For all patients, a negative charge profile. The mean preoperative phalangeal valgus was 34.5° the metatarsus varus was average of 19.9° and the distal metatarsal articular angle of 27.7°. The results were evaluated in the Kitaoka classification. The phalangeal valgus was much improved with a mean value of 12.56° A correction of metatarsus varus (9.5°) and the distal metatarsal joint angle (8.34°) was found. The overall result included 90% very good and good results. There were 10.5% of complications (residual pain, stiffness, infection). Our results were compared with those obtained with the classic technique in the various series in the literature. The Scarf osteotomy without internal fixation yields similar results, but with a better correction of AADM and the advantage of using osteosynthesis. Cadaveric training is absolutely vital in avoiding unnecessary complications and minimizing the surgeon's learning curve. Available data about the minimally invasive procedure for minimally invasive surgical procedures for postoperative morbidity, reduction of stiffness, return to function and outcome requires further scientific scrutiny.

Keywords: Percutaneous osteotomy, MICA, hallux valgus.

Copyright © 2019: This is an open-access article distributed under the terms of the Creative Commons Attribution license which permits unrestricted use, distribution, and reproduction in any medium for non-commercial use (NonCommercial, or CC-BY-NC) provided the original author and source are credited.

INTRODUCTION

The interest of this study is to evaluate the clinical and radiological results of this technique and compare them with data from the literature. To demonstrate its reliability and reproducibility

METHODS

This is a retrospective study dealing with 30 cases of hallux valgus treated by percutaneous chevron osteotomy of the 1st metatarsal within the department of orthopedic traumatology surgery of Avicenne hospital of Rabat during a period of 7 years; from the month of January 2010 to December 2017. For the realization of this work; We have prepared a record of operations, divided into three parts: the first contains the anamnestic data of the patient, the second was devoted to the data of the radio-clinical examination and the therapeutic modalities (Figure 1-3), while the last part put highlight the evolution of our patients according to the clinical results, radiological and complications. The series consists of 30 patients with an average age of 36 at the time of the intervention with extremes ranging from 16 to 65 years. In our series

63.16% of our patients (20 cases) were men and 36.84% of women (10 cases). 10 of our patients (36.84%) have a family history of Hallux Valgus in the first degree. 14 patients had hallux valgus of idiopathic origin. 6 patients had a congenital hallux valgus. No secondary or recurrent hallux valgus was operated. This intervention involved 20 feet straight and 10 feet left. Only 6 patients had bilateral involvement The pain with regard to exostosis was the main symptom, it was present in 37 feet or 90.24% and absent at the level of 4 feet or 9.75% of cases. Metatarsalgia have been observed in all our patients. Present in 100% of patients (related to pain or deformity or their association). The unsightly appearance of deformity was a cause for concern in 18 of our patients, including all women. LGBT or fatigability walking disorders were found in 14 of our patients (36.84%); 71% of our feet were of Egyptian type, ie 29 cases, 27% were of Greek type or 11 feet and 2% were of square type or only one patient. 29 of our patients had soft tissue lesions. There is one case of bursitis and 28 feet with plantar calluses. The presence of a static disorder of the forefoot was objectified in 6 patients; all of whom suffered from flat feet. All our patients benefited from a standard

radiological assessment including a frontal and profile picture in load. For our series, the mean value of the M1P1 angle preoperatively was 34.47° with a standard deviation of 6.5° with a median of 34° and extremes ranging from 22° to 46°. For our series, an average M1M2 angle of 19.93° was observed with a standard deviation of 3.9 ° and extremes ranging from 12 to 28 ° with a median of 20°. The mean value of DMAA preoperatively was 27.64° with a standard deviation of 6.8° and extremes ranging from 14° to 38° with a median of 30°. Preoperatively, the mean value of the angle M1M5 was 32° with a standard deviation of 5.2° and extremes ranging from 20° to 42° and a median of 32°. The metatarsophalangeal joint congruence was assessed preoperatively: 13 cases had a congruent metatarsophalangeal joint, the rest had a luxated or subluxated joint. Signs of osteoarthritis (narrowing of the joint space and osteophytic reconstruction) of the MP joint and / or the cuneometatarsal joint were observed in 4 cases of our series. All of our patients had spinal anesthesia, with the exception of two patients who had a lower extremity block. The support and resumption of walking was immediate with total discharge shoe port in the front of the Barouk type foot for 4 weeks. After this period, the shoes are normal again.

RESULTS

The average decline in the series is 48 months. The subjective satisfaction assessment was conducted by asking patients what their opinion of the intervention was among the following:

- Very satisfied: 08 patients
- Satisfied: 20 patients
- Disappointed: two patients

The evaluation of the forearm functional score was performed in preoperative consultation and at last follow-up using the AOFAS score described by Kitaok. The results are noted out of 100. The preoperative mean value of the Kitaoka score was 55.54 / 100 with a standard deviation of 8.31 / 100 and extreme values ranging from 36/100 to 71/100. The mean value at the last Kitaoka score is 87.12 / 100 with a standard deviation of 6.27 / 100 and values ranging from 63/100 to 95/100. After the osteotomy of SCARF, all our patients benefited from a standard radiological assessment including a face and profile picture in load. Complications occurred in four patients, 9.75% of cases. Residual pain was reported by two patients (those who were disappointed), only one case of infection was observed, whereas the stiffness of the MTP joint was observed in one patient. In addition, there were no consolidation disorders at the osteotomy site, whether delayed consolidation or nonunion.

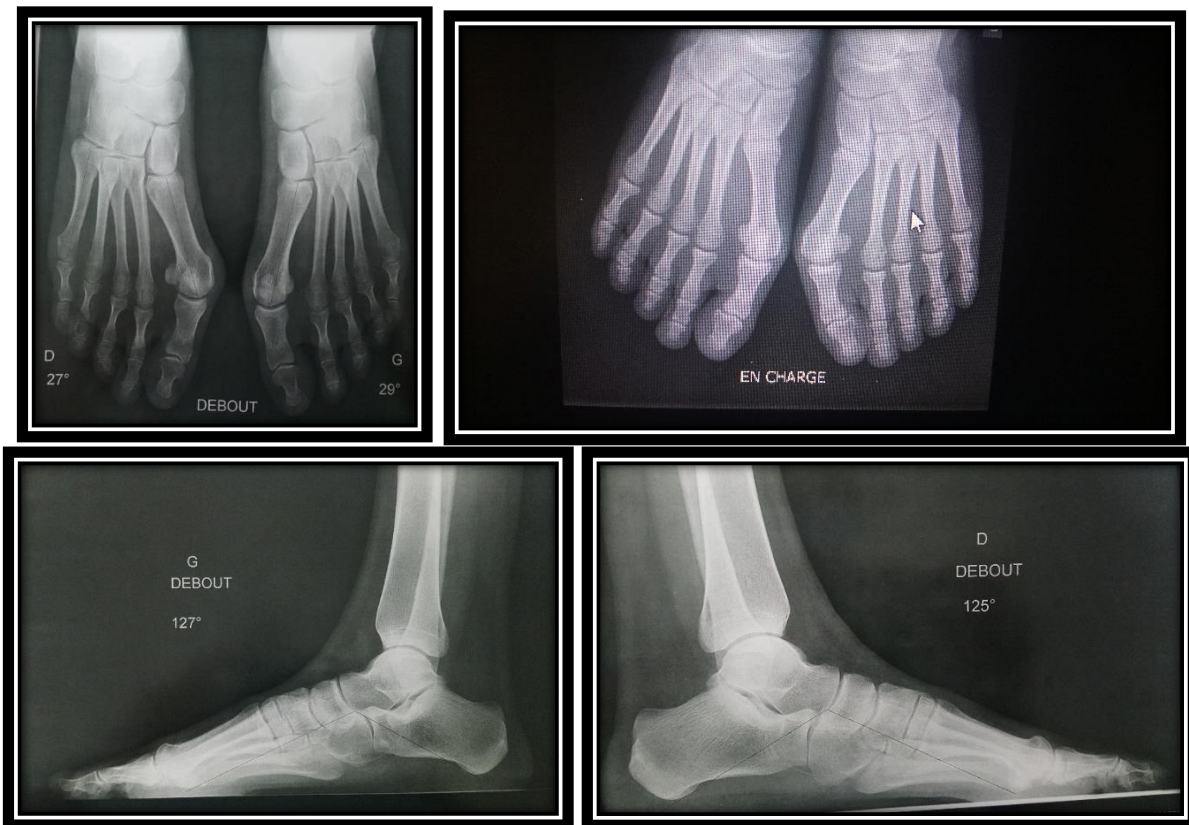


Fig-1 : X-ray view of foot (face/ profile: in charge with standing position)

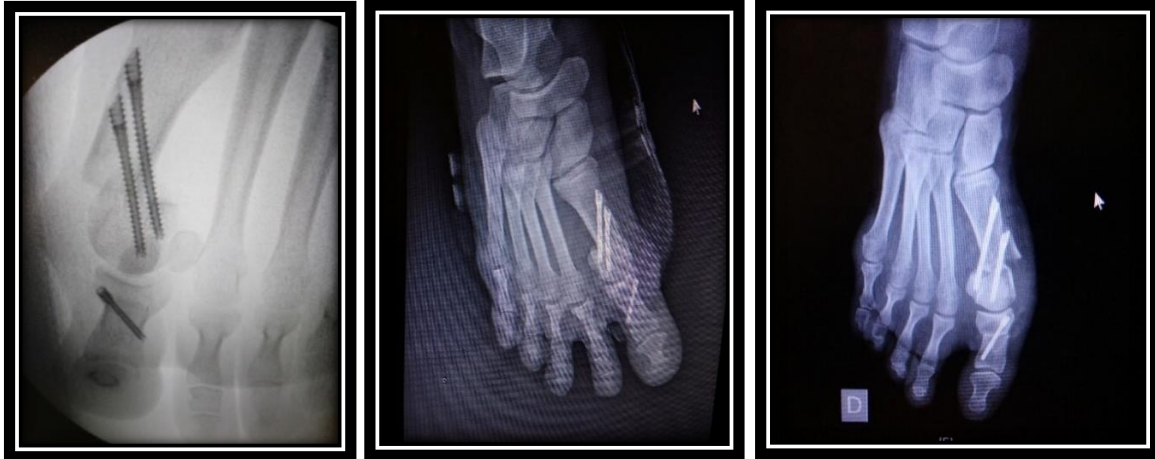

Fig-2: Post operative X-ray (face): First metatarsal chevron percutaneous osteotomy

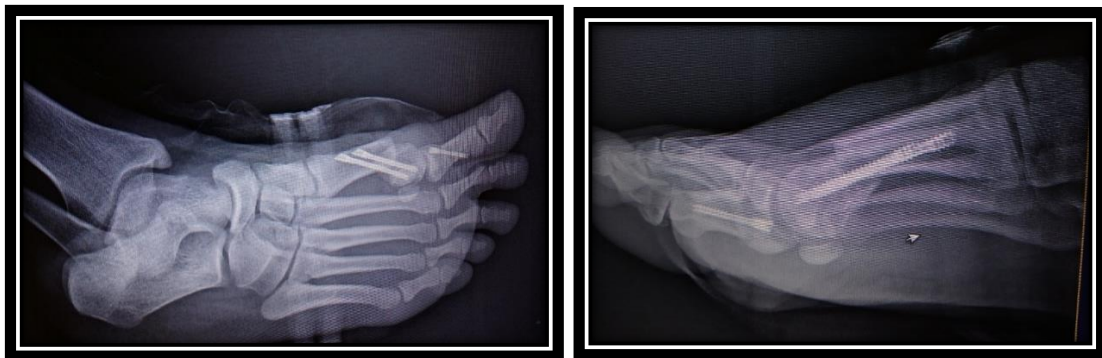


Fig-3: X-ray view (profile and ¾) of foot after chevron percutaneous osteotomy

DISCUSSION

Use of this technique is increasing in Europe [1, 2]. Vern and Redfern [3] and colleagues have presented their early results with the MICA technique at both the British and American Orthopedic Foot & Ankle Societies. In 2010, Redfern and Walker [4, 5] 21 presented early learning curve results for the MICA technique (including technical modifications) performed in 70 patients (83 osteotomies). Satisfaction was seen in both intermetatarsal and hallux valgus angles and Kitaoka [6, 7] scores at 3- to 12-month follow-up. Overall, 94% of patients were satisfied with the results of surgery. In this initial series, only 5 patients (7%) experienced movement of osteotomy during the early postoperative period (with only 2 patients requiring further corrective surgery). As a result of these cases, the technical fixation has been modified (tricortical fixation with proximal screw) to successfully avoid this problem. Metatarsalgia was observed in 4 patients, and 2 superficial wound infections, no deep infections, and no cases of osteonecrosis were seen. In 2013, Perera [8, 9] presented his early learning curve experience with the MICA technique in a comparative study of the MICA technique versus open chevron osteotomies (AOFAS 2013). These results were also very encouraging. Manchester-Oxford Foot Questionnaire and AOFAS scores [10, 11] were significantly better in the MICA

group than the open chevron group. Perera also observed a lower infection rate and less postoperative stiffness and pain in the MICA group than in the open chevron group, with no significant difference in correction achieved. The potential complications of the technical MICA are the same as those of any open technical hallux valgus and those of a burr percutaneously (eg, portal burn). The authors have not experienced any of these complications with the proposed technique, but without training and awareness of these potential risks, they are possible. The results thus far suggest that the technical MICA may be associated with a lower risk of infection, less stiffness (because the first MTPJ capsule is not violated as it is with open techniques), and less bread. No reports exist of osteonecrosis with the technical MICA. Beyond this, the techniques of undercorrection or overcorrection of the hallux valgus deformity remain and are user- and experience-dependent [12, 13]. Any surgeons wishing to perform the MICA technique must undergo specialist training in surgeons experienced with the technique to reduce the learning curve and potential complications.

CONCLUSION

Specific cadaveric training is mandatory for any surgeon considering performing minimally invasive surgical techniques. This training is absolutely vital in avoiding unnecessary complications and minimizing the

surgeon's learning curve. Available data suggest that the MICA technique is a safe alternative to open techniques for hallux valgus correction, although whether minimally invasive techniques such as this offer significant advantages for patients in terms of postoperative morbidity, reduction of stiffness, return to function, and outcome requires further scientific scrutiny as surgeons publish their data. Minimally invasive surgical techniques for correction of a wide variety of forefoot and hindfoot abnormalities are currently gaining popularity among European surgeons, and this is an interesting area of development.

Conflicts & Intérêts: None

REFERENCES

1. Wilson DW. Treatment of hallux valgus and bunions. *British journal of hospital medicine*. 1980 Dec;24(6):548-9.
2. Bösch P, Wanke S, Legenstein R. Hallux valgus correction by the method of Bösch: a new technique with a seven-to-ten-year follow-up. *Foot and ankle clinics*. 2000 Sep;5(3):485-498.
3. Hohmann G. Symptomatische oder physiologische behandlung des hallux valgus. *Munch Med Wsche*. 1921;33:1042-1045.
4. Reverdin J. The Deviation of Hallux Valgus and Its Treatment. De la deviation en dehors du gros orl (hallux valgus) et son traitement chirurgical. *InTrans International Medical Congress 1881*: 2, 408-412.
5. Isham SA. The Reverdin-Isham procedure for the correction of hallux abducto valgus. A distal metatarsal osteotomy procedure. *Clinics in podiatric medicine and surgery*. 1991 Jan;8(1):81-94.
6. de Prado M, Golanó P, Ripoll PL. Minimally invasive foot surgery: surgical techniques, indications, anatomical basis. *About Your Health*; 2009.
7. Isham SA, Nunez OE. The Reverdin-Isham procedure for the correction of hallux valgus. In Maffulli N, Easley M. (eds): *Minimally invasive surgery of the foot and ankle*. London: Springer-Verlag, 2011. 97-108.
8. Bauer T, Biau D, Lortat-Jacob A, Hardy P. Percutaneous hallux valgus correction using the Reverdin-Isham osteotomy. *Orthopaedics & Traumatology: surgery & research*. 2010 Jun 1;96(4):407-416.
9. Kadakia AR, Smerek JP, Myerson MS. Radiographic results after percutaneous distal metatarsal osteotomy for correction of hallux valgus deformity. *Foot & ankle international*. 2007 Mar;28(3):355-360.
10. Leemrijse T, Valtin B, Besse JL. Hallux valgus surgery in 2005. Conventional, mini-invasive or percutaneous surgery? Uni-or bilateral? Hospitalisation or one-day surgery?. *Revue de chirurgie orthopedique et reparatrice de l'appareil moteur*. 2008 Apr;94(2):111-127.
11. Magnan B, Montanari M, Bragantini A, Fieschi S, Bartolozzi P. Trattamento chirurgico dell'alluce valgo con tecnica "mini-invasiva" percutanea (PDO: percutaneous distal osteotomy). *Progressi in medicina e chirurgia del piede*. 1997;6:91-104.
12. Magnan B, Pezzè L, Rossi N, Bartolozzi P. Percutaneous distal metatarsal osteotomy for correction of hallux valgus. *JBJS*. 2005 Jun 1;87(6):1191-1199.
13. Giannini S, Ceccarelli F, Bevoni R, Vannini F. Hallux valgus surgery: the minimally invasive bunion correction (SERI). *Techniques in Foot & Ankle Surgery*. 2003 Mar 1;2(1):11-20.