

Neurofibromatosis Type I: Lisch's Nodule or Lisch's Social Handicap!!

Maryama El kaddoumi*, Ouafa Cherkaoui

Service d'ophtalmologie A, Hopital des Spécialités de Rabat, Université mohamed V, 23000, Morocco

DOI: [10.36347/sjams.2019.v07i09.062](https://doi.org/10.36347/sjams.2019.v07i09.062)

| Received: 17.09.2019 | Accepted: 26.09.2019 | Published: 30.09.2019

*Corresponding author: Maryama El Kaddoumi

Abstract

Original Research Article

The neurofibromatous is a disease that is part of the phacomatoses, uncommon whose diagnosis must meet strict criteria. Lisch nodules are a benign disease of the anterior segment. The cutaneous neurofibromas may have different locations and sizes and which may be the cause of a social handicap.

Keywords: Lisch nodules, neurofibroma, coffee-and-milk spots.

Copyright © 2019: This is an open-access article distributed under the terms of the Creative Commons Attribution license which permits unrestricted use, distribution, and reproduction in any medium for non-commercial use (NonCommercial, or CC-BY-NC) provided the original author and source are credited.

INTRODUCTION

The neurofibromatosa also called Recklinghausen's disease by the name of the German doctor, Friedrich Daniel von Recklinghausen, who is the first to describe this disease in 1881 There are two essential forms: neurofibromatosis type 1 and neurofibromatosis type 2 characterized by the presence "Café au lait" skin spot characteristic of type 1 neurofibromatosis. The association with tumors, especially with the glioma of the optic nerve, is very serious. Ophthalmological examination is an essential step in the diagnosis of the disease by searching for iris nodules called pathognomonic Lisch nodules of the disease

OBSERVATION

This is a 36-year-old patient with ATCD of chronic depression with attempted suicide on antidepressant for 10 years, who consults for ophthalmological opinion, the AV 10/10, eye tone at 14mmhg in ODG, the anterior segment presents no abnormalities or signs of ocular inflammation with the exception of the presence of Lisch nodules at the bilateral level (Figure-1), the fundus eye is strictly normal. In addition, the patient presents dermal spots with multiple milk coffee with subcutaneous neurofibromatomas (Figure-2).

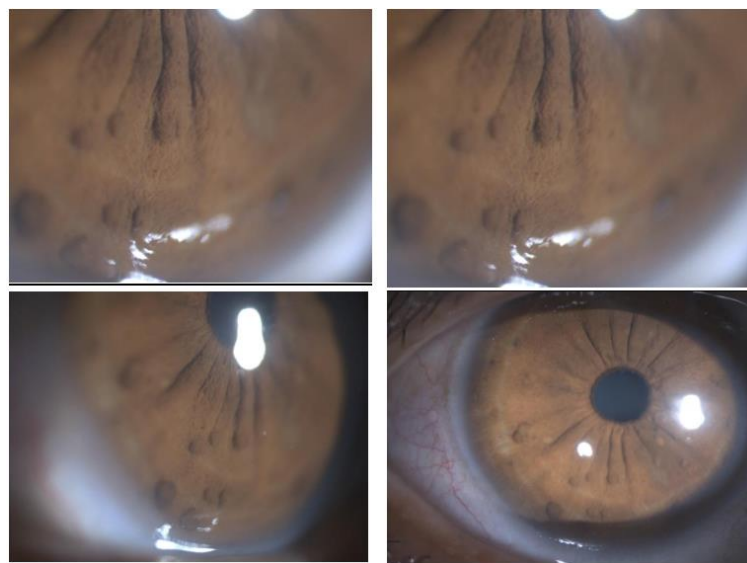


Fig-1: Lisch Nodule

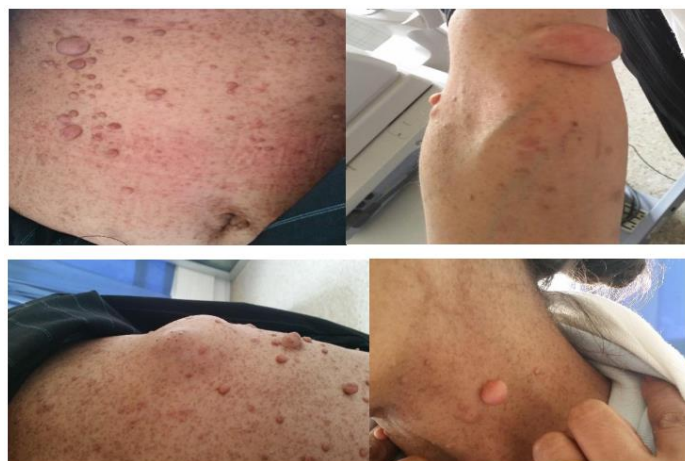

Fig-2: Multiple neurofibromas with milk coffee stains

The brain scan is performed in search of a glioma of the optic nerve, The dosage of catecholamines and metanephrines are normal. She has had several surgical ablations of neurofibromas. The social and psychological impact is very important, the patient refuses to marry, and is always struggling to find a job.

DISCUSSION

Von Recklinghausen disease or neurofibromatosis type I (NF1) is a disease belonging to the group of phacomatoses. It is an autosomal dominant pathology due to a spontaneous mutation of the NF1 gene encoding a protein, neurofibromin, with variable systemic symptomatology and high susceptibility to tumors, but 50% of the forms are sporadic [1].

On the ocular plane, the most frequent manifestation, which corresponds to a diagnostic criterion, is the nodules of Lisch, which corresponds on the histological plane. These nodules represent melanocyte hamartomas made of melanocytes containing pigments of variable intensity, clinically they correspond to small gelatinous masses, of variable color according to the color of the iris without predictive localization of variable size. The gliomas of the optic nerves can complicate the disease [2].

On the cutaneous level, coffee-milk spots are pathognomonic of the disease, especially when they are multiple, skin neurofibromas can reach large sizes with different localizations in the body [3, 4]

Other manifestations are long bone dysplasias, meningiomas, pheochromocytoma [5], cognitive disorders and the genesis of malignant tumors such as leukaemias, neuroblastomas, nephroblastomas and rhabdomyosarcomas [6].

We often forget to look for the psychic and socio-economic disability of patients suffering from this disease, their social reintegration and their cognitive-behavioral management is above all a priority.

CONCLUSION

No definite treatment can cure this disease, but the quality of life of patients can be improved by the destruction of skin neurofibromas by electro-coagulation laser, as well as conventional surgery for plexiform neurofibromas become too troublesome or too much deformity important of the spine. The prognosis of the disease depends on the presence or absence of tumor involvement.

Declaration: The patient gave her consent for us to use her own images.

REFERENCE

1. Hyman SL, Shores A, North KN. The nature and frequency of cognitive deficits in children with neurofibromatosis type 1. *Neurology*. 2005 Oct 11;65(7):1037-44.
2. JFO-11-2001-24-9-0181-5512-101019-ART10
3. Altarescu G, Brooks B, Kaplan Y, Eldar-Geva T, Margalioth EJ, Levy-Lahad E, Renbaum P. Single-sperm analysis for haplotype construction of de-novo paternal mutations: application to PGD for neurofibromatosis type 1. *Human Reproduction*. 2006 May 31;21(8):2047-51.
4. Gutmann DH, Wood DL, Collins FS. Identification of the neurofibromatosis type 1 gene product. *Proceedings of the National Academy of Sciences*. 1991 Nov 1;88(21):9658-9662.
5. Jett K, Friedman JM. Clinical and genetic aspects of neurofibromatosis 1. *Genetics in Medicine*. 2010 Jan;12(1):1-11.
6. Zeller J. Surveillance d'une neurofibromatose, un pronostique imprévisible. *La revue du praticien-médecine générale*, 1994;8:37-44.