

Research Article

Histomorphological Spectrum of Helicobacter Pylori Positive Gastric Biopsies – A 2 Year Prospective Study

Dr. Vanita Pandey, Dr. Richa Jindal, Dr. K. Mahesh Kumar*, Dr. Molly Joseph, Dr. Prof. Nirmal Kumar
Malla Reddy Institute of Medical Sciences, Jeedimetla, Hyderabad, Telangana 500055, India

***Corresponding author**

Dr. Kandukuri Mahesh Kumar

Email: doctormaheshgoud@gmail.com

Abstract: Helicobacter pylorus (H. pylori) a spiral, urease producing organism and is a important pathogenic factor in peptic ulcer disease (PUD). Extensive molecular studies suggest that the bacteria cause gastritis by stimulating production of proinflammatory cytokines and by directly injuring epithelial cells. Study was done to know the gastric mucosal histological features in H. pylori positive gastric biopsies and categorization of lesions, and also to know the association of H. pylori with various parameters such as age, sex, site, colonization of organisms, spicy diet, smoking and alcohol intake, Intestinal Metaplasia. A total of 261 gastric biopsies were received. Out of which 131 biopsies were positive for H. pylori were included in this study by using various clinical parameters. In our study, dominant age group was 30 – 60 yrs with 83 (63.4%) cases and H. pylori was associated with chronic gastritis -115 (87 %), Male to female sex ratio was 1.04: 1. Antrum was the predominant biopsied site which constituted 117 cases out of a total of 131 cases i.e. 87.3%. 14 biopsies were from gastric body i.e. 10.4% and 3 biopsies were from fundus region. Mild colonization was seen in 73 (54.5%) biopsies, moderate in 29 (21.6%) biopsies and severe in 32 (23.8%) biopsies, total being 134, as 3 patients had biopsies from 2 different sites. There were 2 (1.5%) cases associated with Gastric ulceration in our study. One case each was associated with granuloma formation and malignancy, in the background of chronic active gastritis.

Keywords: Helicobacter pylori, Chronic Gastritis, Intestinal Metaplasia, Peptic Ulcer disease, Acid Peptic Disease, cagA, Giemsa.

INTRODUCTION

Helicobacter pylorus (H. pylori) is part of a genus of bacteria that have adapted to the ecological niche provided by gastric mucus which is lethal to most bacteria. In 1982, Warren and Marshall isolated a spiral, urease producing organism (later identified as H. pylori) and provided the first insight into an important pathogenic factor in peptic ulcer disease (PUD). The most important etiologic association with chronic gastritis is chronic infection by the bacillus H. pylori. In addition to chronic gastritis, peptic ulcer disease and gastric carcinoma, H. pylori have a definitive etiological role in gastric MALT (mucosa associated lymphoid tissue) lymphoma. Helicobacter pylori are a non-spore, curvilinear gram-negative rod measuring approximately 3.5 x 0.5 µm. Extensive molecular studies suggest that the bacteria cause gastritis by stimulating production of proinflammatory cytokines and by directly injuring epithelial cells [1]. H. pylori infections occur worldwide; the age at which a patient becomes infected reflects local hygiene. A strong association between H. pylori and upper gastrointestinal disease and chronic gastritis has been reported. The strongest evidence for the pathogenic role of H. pylori in PUD is the marked decrease in recurrence rate of ulcers following the eradication of infection. Possible

routes of infection include either oral-oral, fecal-oral or iatrogenic spread with inadvertent use of unsterile pH probes and endoscopes. Pathogenesis includes direct damage to the host occurs via the production of urease and other enzymes. Some strains produce a soluble factor – vacuolating cytotoxin – encoded by the vacA gene which is present in strains. Vacuolating activity is associated with the protein encoded by cytotoxin-associated geneA (cagA) [2, 3]. Infection with cagA gene positive strains is associated with greater number of organisms in the tissue, more severe epithelial damage, greater acute and chronic inflammation, higher likelihood of peptic ulceration and increased risk for gastric cancer [4]. DNA region which is a marker of cytotoxicity has been identified, and is called “Pathogenicity Island”, which encodes proteins responsible for cytotoxicity, signal transduction and induction of cytokines [2]. The tests for detecting H.pylori include endoscopy followed by gastric biopsy and histological demonstration of organisms, biopsy with direct detection of urease activity in the tissue specimen and biopsy with culture of the H. pylori organism. Histopathology of gastric biopsy is accepted as the gold standard for H. pylori detection and also gives valuable information about inflammation of gastric mucosa, the presence of lymphoid follicles,

glandular atrophy, and intestinal Metaplasia with or without dysplastic change and finally the exclusion of carcinoma [5].

AIMS AND OBJECTIVES

- To study gastric mucosal histological features in H. pylori positive gastric biopsies and categorization of lesions.
- To study the association of H. pylori with various parameters such as age, sex, site, colonization of organisms, spicy diet, smoking and alcohol intake, Intestinal Metaplasia.

MATERIALS AND METHODS

A total of 261 gastric biopsies were received. Out of this, 134 biopsies were positive for H. pylori were included in this study. The following clinical parameters were noted:

- Age and sex of the patient.
- Clinical history with relevant specific information regarding Alcohol intake, Smoking and dietary habits including intake of increased salt, oily and spicy food.

- Relevant past history including autoimmune disorders, previous surgery.
- Clinical symptoms of reflux of gastric contents on lying down.
- Clinical diagnosis of the patient.
- Site of the biopsy.

The biopsies were performed by Gastroenterologist and put in properly labeled 10% formalin filled containers and sent for histopathological examination (HPE). Biopsies received by pathologists were processed by routine fixation, paraffin embedding, sectioning, taking 4 µm sections and Giemsa staining was done for identification of H. pylori. Sections of H. pylori positive gastric biopsies were examined to study the pathological changes in gastric mucosa. Grading of the lesions was done according to Sydney system of grading of chronic gastritis [6]. The histological variables studied included are 1) Chronic 2) Inflammation, 3) Activity, 4) Atrophy, 5) Intestinal Metaplasia 6) H. pylori density. Each being further classified as mild, moderate and severe.

Table-1: Grading guidelines for histological variables as per Sydney system [6]

Feature	Definition	Grading guideline
Chronic inflammation	Increase in lymphocytes and plasma cells in lamina propria	Mild, Moderate or Severe increase in density
Activity	Neutrophilic infiltration of the lamina propria, pits or surface epithelium	<1/3 rd of pits and surface infiltrated = mild 1/3 rd to 2/3 rd = moderate >2/3 rd = severe
Atrophy	Loss of specialised glands from either corpus or antrum	Mild, Moderate or Severe loss
Intestinal metaplasia	Intestinal metaplasia (all subtypes) of the epithelium	<1/3 rd of the mucosa involved = mild 1/3 rd to 2/3 rd = moderate >2/3 rd = severe
H.pylori	Density of Helicobacter-like organisms overlying epithelium	Scattered organisms covering <1/3 rd of surface=mild colonization Large clusters/continuous layer over 2/3 rd of surface=severe Intermediate numbers=moderate colonization

OBSERVATIONS AND RESULTS

Categorization Of Cases

Out of 261 gastric biopsies received during a period of 2 years, 131 biopsies were positive for H.

pylori, as indicated by Giemsa stain and formed the basis for our study. The histomorphological details of these cases were studied and categorized as follows: (Table 2, Figure 1,2,3,4,5)

Table-2: Categorization of lesions

LESIONS	NO. OF CASES
Chronic gastritis with activity (CAG)	115 (87.79%)
Chronic gastritis (CG)	13 (9.92%)
Chronic Gastritis with atrophy (CGA)	1 (0.76%)
Chronic gastritis with Intestinal metaplasia and atrophy (CGA with IM)	1 (0.76%)
Biopsy with no significant inflammation (Bx with NSI)	1 (0.76%)
Total	131 (100%)

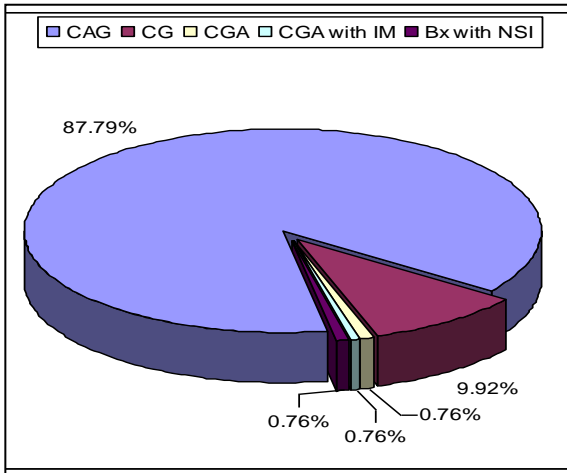


Fig. 1: Categorization of *H. pylori* positive gastric biopsies

It was also observed that almost all the biopsies which were *H. pylori* positive revealed chronic inflammation, 130 out of 131 i.e., (99.2%).

130 cases with features of Chronic Gastritis were classified as per Sydney system of grading of chronic gastritis. One biopsy with features of no significant inflammation was grouped separately. Categorization of cases with chronic gastritis is shown in Table-3, Figure-6.

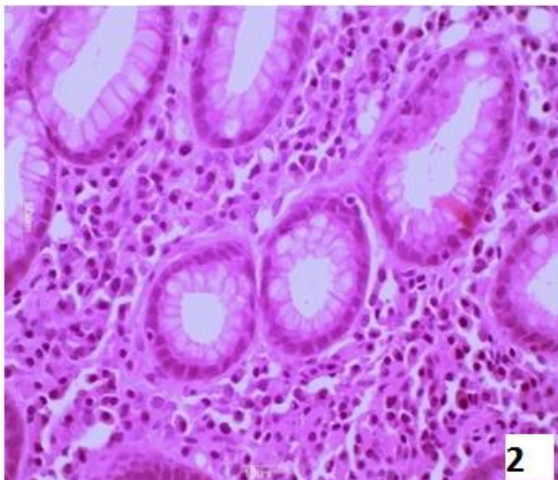


Fig-2: Photomicrograph showing chronic gastritis – increased cellularity of lamina propria with lymphocytes, plasma cells and polymorphs.

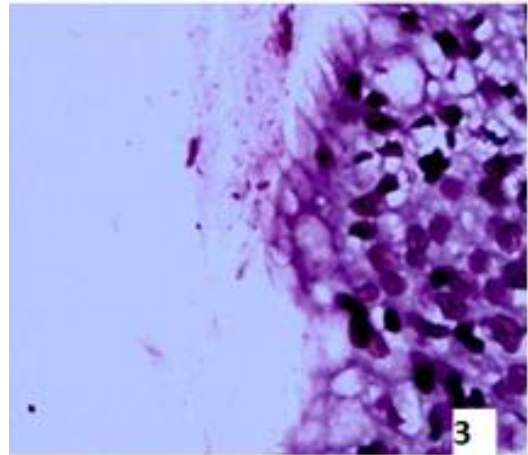


Fig-3: Photomicrograph showing mild colonization of *H. pylori* organisms – few, curved, spiral shaped bacilli seen entrapped in the mucous layer overlying the epithelium (Giemsa)

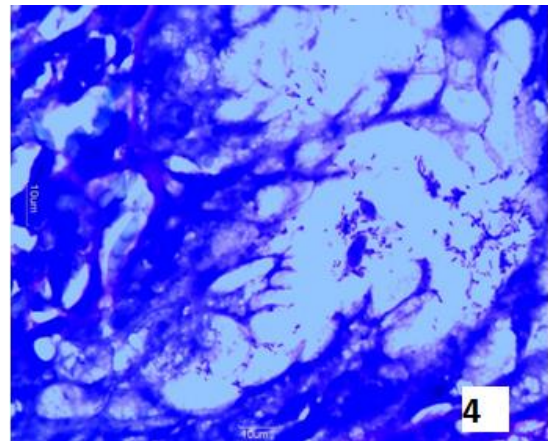


Fig-4: Photomicrograph showing severe colonization of *H. pylori* organisms – numerous, similar forms seen adjacent and attached to glandular epithelium (Giemsa)

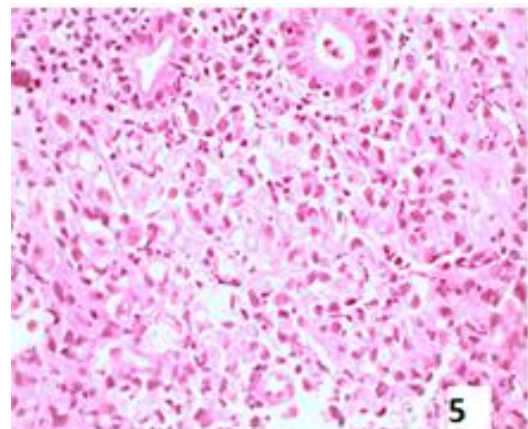


Fig-5: Photomicrograph demonstrating malignancy in the background of chronic active gastritis – infiltration of neoplastic cells with hyperchromatic nuclei, many were signet ring morphology, in the gastric mucosa

Table-3: Categorization of Chronic gastritis lesions

Chronic Gastritis Lesions	No. Of Cases
Chronic gastritis with activity (CAG)	115
Chronic gastritis (CG)	13
Chronic Gastritis with atrophy (CGA)	1
Chronic gastritis with Intestinal Metaplasia and atrophy (CGA with IM)	1
Total	130

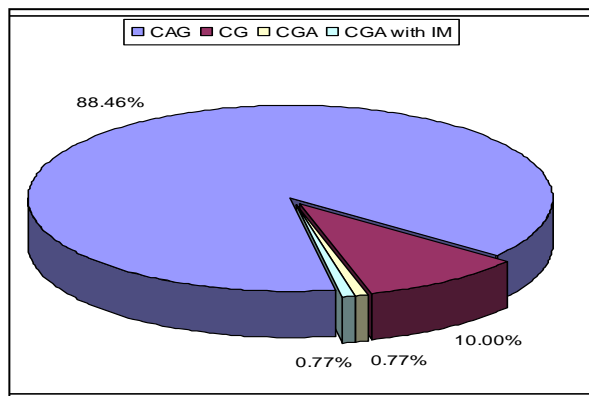


Fig-6: Categorization of Chronic gastritis cases

Out of the 131 cases, 115 cases were associated with activity and were further classified as -

Table 4: Age distribution of cases

	<30 YEARS	30-60 YEARS	>60 YEARS	TOTAL
No. of cases	38	83	10	131
Percentage	29	63.4	7.6	100

The severity of H. pylori infection in various age groups was studied.

Mild colonization was seen in 71 patients, moderate colonization was seen in 29 patients and severe colonization in 32 patients. Patients in the age group 30 – 60 yrs dominated the picture, with 47 (66.2%) showing mild colonization, 17 (58.6%) showing moderate and 20 (62.5%) showing severe colonization.

Twenty two out of 131 (15.3%) patients showed glandular atrophy of mild and moderate severity, in which 20 cases were with mild atrophy and 2 were with moderate atrophy. There was no case showing severe atrophy.

Only 10 patients out of 131 (7.6%) were associated with findings of intestinal metaplasia in our study. Intestinal metaplasia of varying severity from

Chronic active gastritis (CAG)- 86 (65.6%) , Chronic active gastritis with atrophy (CAG with Atrophy)- 17 (13%) , Chronic active gastritis with Intestinal Metaplasia (CAG with IM)- 8 (6.1%), Chronic active gastritis with ulceration (CAG with Ulceration)- 2 (1.5%), Chronic active gastritis with granulomas (CAG with Granulomas)- 1 (0.7%), Chronic active gastritis with Malignancy (CAG with Malignancy)- 1 (0.7%). It was observed that activity of varying severity was a major component, ie, (87.8%) of total cases. Glandular atrophy and Intestinal metaplasia were less frequently observed .Glandular atrophy was seen in 17 out of 115 cases with Chronic active gastritis while intestinal metaplasia was seen in was seen in 8 out of 115 cases. Ulcerations were seen in only 2 cases and granulomas and malignancy were still rarer associations constituting 1 case each in our study.

Age distribution

Age distribution of the patients, in <30 years, 30-60 years and >60 years groups was studied. In our study, dominant age group was 30 – 60 yrs with 83 (63.4%) cases, followed by 38 (29%) cases in <30 yrs age group and 10 (7.6%) cases in >60 yrs age group. Age range of the patients was 14-82 years. Mean age of presentation of H. pylori infected patients was 39.5 years.

mild to severe was seen in 8 patients of 30 – 60 yrs group. Only 1 patient each of <30 yrs and >60 yrs showed mild intestinal metaplasia.

Sex distribution

In our study, biopsies were taken from 67 male patients and 64 female patients. Thus, the sex ratio was 1.04: 1. Only 1 male, of these, showed different severity of colonization at different sites – antrum showing mild colonization and the body showing moderate colonization by H. pylori organisms. Mild colonization was seen in 39 males, 32 females; moderate in 12 males, 17 females and severe colonization was seen in 17 males and 15 females. The association of sex distribution with severity of colonization was statistically not significant (p=0.522, Chi-square test).

Out of 134, 117 biopsies were taken from antrum, 14 biopsies were from gastric body and 3 biopsies were from fundal region (Figure-7)

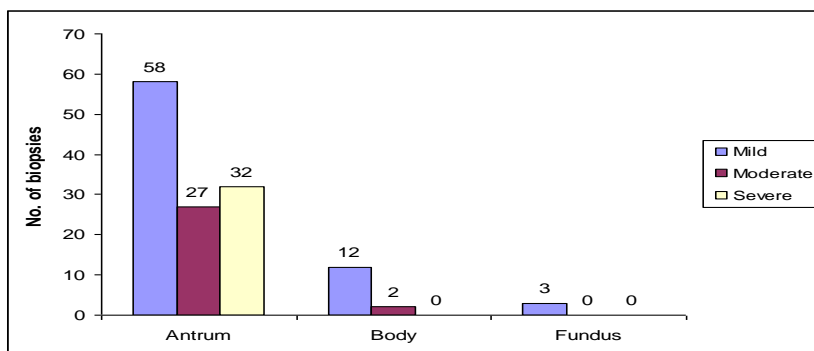


Fig-7: Association of biopsy site with the colonization of organism

Histological features

Histopathological features were graded according to the Sydney system of grading of chronic gastritis. The features taken into consideration were chronic inflammation, glandular atrophy, activity, intestinal metaplasia and the intensity of colonization.

Chronic inflammation:

Out of 134 biopsies, 35 were associated with mild chronic inflammation, 89 were associated with moderate inflammation and 9 were associated with severe chronic inflammation. One biopsy was not associated with any significant inflammation. Association of chronic inflammation with severity of colonization by *H. pylori* organisms was statistically not significant ($p=0.138$, Chi-square test).

Activity

Varying severity of activity was seen in 115 biopsies. No activity was seen in 19 biopsies. Mild activity was seen in 58 biopsies, moderate in 49 biopsies and severe activity was seen in 8 biopsies. Association of activity with severity of colonization of organisms was statistically significant ($p=0.000$, Chi-square test).

Atrophy

Glandular atrophy was seen in 22 biopsies – 20 showing mild and 2 showing moderate atrophy. Association of glandular atrophy with severity of

colonization by *H. pylori* organisms was statistically not significant ($p=0.379$, Chi-square test).

Eleven out of 134 biopsies showed intestinal metaplasia of varying severity – 8 with mild, 2 with moderate and 1 with severe intestinal metaplasia.

Association of intestinal metaplasia with severity of colonization by *H. pylori* organism was statistically not significant ($p=0.254$, Chi-square test).

Associated factors studied in detail with reference to gastric colonization by *H. pylori* organisms, were dietary habits including spicy food intake, alcohol intake, addiction to smoking and symptoms of gastroesophageal reflux (GERD).

Association of alcohol intake with severity of colonization by *H. pylori* organism was statistically not significant ($p=0.297$, Chi-square test).

Smoking was seen in reference to 29 biopsies. Association of smoking with severity of colonization by *H. pylori* organism was statistically not significant ($p=0.555$, Chi-square test).

Association of spicy food intake with severity of colonization by *H. pylori* organism was statistically not significant ($p=0.617$, Chi-square test). Association of spicy food intake with severity of colonization by *H. pylori* organism is shown in Table 5 and Fig.8

Table-5: Association of spicy food intake to the severity of colonization by *H. pylori* organisms

COLONIZATION	SPICY FOOD INTAKE		TOTAL
	YES	NO	
Mild	34	39	73
Moderate	11	18	29
Severe	16	16	32
Total	61	73	134

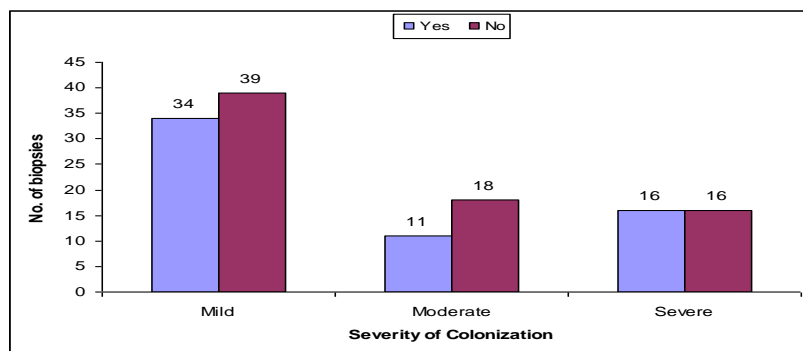


Fig-8: Association of spicy food intake to the severity of colonization by H. pylori organism

Association of gastroesophageal reflux (GERD) intake with severity of colonization by H. pylori organism was statistically not significant ($p=0.718$, Chi-square test).

DISCUSSION

In our study, a total of 261 Gastric biopsies were included, 134 (51.3%) gastric biopsies taken from 131 patients, positive for H.pylori on staining with Giemsa, were included in this study. Thus the positivity rate of H.pylori infection in our study was 51.3%. This is in correlation with a study conducted by Weill FX et al, who found that prevalence of H.pylori infection was 55.2% [7]. In various population based studies separately conducted by authors; Atisook K et al., Quieroz DMM & Luzza F, prevalence of H.pylori infection was found to be 40% and 41.7% respectively [5,8]. In another cross-sectional study conducted by Santos IS et al., on adult population in Southern Brazil, the prevalence rate of H.pylori infection was 63.4% [9]. In a study conducted by Petersson F et al., prevalence of H. pylori infection was found to be 40% of the entire population sample and only 1 subject out of these had positive H.pylori status with no gastritis [10]. Of these, 133 (99.2%) biopsies, had features of Chronic Gastritis and were classified according to Sydney system of grading of chronic gastritis. One biopsy (0.7%) showed the presence of H.pylori organisms only with no significant lesion. In a study conducted by Atisook K et al., of all the H.pylori positive gastric biopsies, 98.2% biopsies were associated with chronic gastritis and 1.8% was associated with no significant lesion [5]. In a study conducted by Hui PK et al. ages ranged from 17 – 93 years with a mean age of 59.6 years [11]. Weill FX et al found that overall prevalence of H.pylori infection was 55.2% increasing significantly with age from 36.1% at 18-19yrs to 63.7% at 50-59 yrs ($p=0.003$) [7] which is correlating with our study. Our study comprised of 67 male and 64 female patients, ratio being 1.04:1. So, there was no significant difference between the positivity rates according to the sex of the patients. Colonization of H. pylori was assessed as mild in 73 (54.5%) biopsies, moderate in 29 (21.6%) biopsies and severe in 32 (23.8%) biopsies. 3 patients amongst our study group had biopsies from 2 sites, one of them had

different colonization at both sites, antrum with mild and body with moderate colonization.

Antrum was the predominant biopsied site which constituted 117 cases out of a total of 131 cases i.e. 89.3%. 14 biopsies were from Gastric body i.e. 11.4% and 3 biopsies were from fundic region i.e. 1.5%. Amongst these 3 cases were biopsied from 2 sites antrum and fundus in 2 cases, antrum and body in 1 case. Out of 117 antral biopsies, 58 biopsies revealed mild colonization, 27 biopsies revealed moderate colonization and 32 biopsies showed severe colonization by H.pylori organisms. Out of 14 biopsies taken from body of stomach, 12 biopsies showed mild degree of colonization and 2 biopsies showed moderate colonization. None of the biopsies from body of stomach showed severe colonization. All the 3 biopsies from fundic region showed mild colonization by H.pylori organisms. This was consistent with the findings of a study conducted by Hackelsberger et al in which they noted a higher bacterial density and more notable chronic inflammation in antrum, compared with cardiac or corpus mucosa [12].

The histological parameters were studied and graded as per the Sydney system of Histological grading of Chronic Gastritis. Chronic inflammation was assessed on the basis of increase in lymphocytes and plasma cells in lamina propria. The degree of colonization by H.pylori organisms is directly proportional to the intensity of inflammation associated. Also, that in presence of intestinal metaplasia and gastric atrophy, intensity of colonization decreases.

Activity was defined as neutrophilic infiltration of the lamina propria, pits or surface epithelium. Activity of varying grades was seen in 115 out of 134 biopsies (85.8%). No activity was seen in 19 biopsies, mild activity was seen in 58 (43.3%) biopsies, moderate grade of activity was seen in 49 (36.6%) biopsies and severe activity was seen in 8 (5.9%) biopsies. In a study conducted by Hui PK et al, out of 180 endoscopic diagnoses of Gastritis with erosion, duodenal ulcer, gastric ulcers, 118 biopsies showed chronic active gastritis (65.5%) [11].

One of our cases revealed in addition to findings of chronic active gastritis, the presence of hyperplastic epithelium. Studies in support of such a finding have been conducted separately by Saito Y *et al* and Carneiro F *et al.* concluding that *H.pylori* colonization induces epithelial degenerative lesions and inflammation that lead to reactive foveolar hyperplastic changes and eventually to hyperplastic polyps [13, 14]. Hui PK *et al*, in another study, interpreted that epithelial tufting is a regenerative process after the epithelium is damaged by *H.pylori* [11].

Intestinal metaplasia was observed in 11 out of 134 biopsies (8.2%), 8 biopsies (5.9%) showed mild intestinal metaplasia, 6 out of these 8 cases were associated with mild colonization by *H.pylori* organisms, 2 biopsies were associated with severe grade of colonization. Two biopsies (1.5%) showed moderate intestinal metaplasia and were associated with mild colonization by organisms. 1 biopsy (0.7%) showed severe intestinal metaplasia and moderate colonization. 123 biopsies did not show intestinal metaplasia, degree of colonization being mild in 65, moderate in 28 and severe in 30 cases. In a study conducted by Testoni PA *et al.*, *H.pylori* organisms were identified in 211 out of 336 (62.8%) cases, whereas in 174 cases showing intestinal metaplasia, only 53 (30.4%) showed the presence of *H.pylori* [16]. Acidic glycoproteins secreted by metaplastic epithelium may provide a more hostile environment for *H.pylori* than the neutral glycoproteins of the normal mucosal layer. The replacement of the gastric epithelium and glandular tissue by intestinal type epithelium leads to lower numbers of specific receptors for *H.pylori*. Intestinal epithelium is more resistant to *H.pylori* infection than gastric epithelium because of relatively higher concentration of specific IgA antibodies [17]. One of the cases in our study revealed granuloma formation in addition to findings of chronic gastritis with activity. There was a well defined collection of histiocytes including epithelioid cells in the lamina propria surrounded by inflammatory cells, mainly mononuclear ones with few polymorphs. Ziehl Neelsen stain for Mycobacterium was negative. There were no other associated clinical findings in favour of Crohn's disease or sarcoidosis. There are few reported cases in literature of isolated granulomatous gastritis (IGG) associated with *H.pylori* infection. The association between chronic granulomatous gastritis (CGG) and *H.pylori* infection was first reported in 1989 by Dhillon *et al.* [18]. Kim YS *et al* reported 1 such case in a 46 yr old male patient, not associated with other systemic causes of Chronic granulomatous gastritis such as Crohn's, sarcoidosis, tuberculosis, malignancy, vasculitis or foreign body reaction, but associated with *H.pylori* infection. One of the cases in our study was associated with malignancy seen in the background of chronic active gastritis. Severe colonization was seen in 9 smokers and 23 nonsmokers. In the study conducted by Ogihara A *et al*, it was found that smoking was

negatively associated with *H.pylori* infection. Nonsmokers had an approximately 1.2 folds higher risk of *H.pylori* than current smokers. Past smokers were found to have a 0.97 fold lower risk than nonsmokers and the trend was significant ($p < 0.01$) [19]. In the same study conducted by Ogihara A *et al.* it was seen that drinking habit was negatively and dose dependently associated with *H.pylori* positivity. Subjects who never drank had an approximate 1.1 fold greater risk of *H.pylori* infection than current drinkers with a significant linear trend ($p=0.02$) [19]. Hermann B *et al.* and Luzza F *et al.* reported a preventive effect of alcohol consumption against active infection with *H.pylori* [20, 21]. In our study, history of gastroesophageal reflux was present in 32 (24.5%) patients and was absent in 99 (75.5%) patients. In a study conducted by Rajendra S *et al.* on 188 patients, out of which 135 were symptomatic for GERD, it was concluded that *H.pylori* was associated with a reduced severity of gastroesophageal reflux spectrum disease and the association was statistically significant ($p = 0.048$) [22].

CONCLUSION

To conclude, the positivity rate of *H.pylori* infection in our setting is 50% and the age group most commonly affected is 30-60 yrs. *H.pylori* infection is mostly seen in the background of chronic gastritis and is associated with activity in majority of them. Presence of glandular atrophy and intestinal metaplasia decrease the severity of colonization.

REFERENCES

1. Liu C, Crawford JM; The gastrointestinal system. Kumar, Abbas, Fausto. Robbins & Cotran, Pathological Basis of Disease, 7th ed. New Delhi: Elsevier; 2004: 813-814.
2. Dhawan PS; Application of newer information on *Helicobacter pylori* to the Indian setting. Indian J Gastroenterol 1997; 1: S16-S19.
3. Beckert S; Functional analysis of the *cag* pathogenicity island in *Helicobacter pylori* isolates from patients with gastritis, peptic ulcer and gastric cancer. Infect Immun, 2004; 72:1043.
4. Blaser MJ, Atherton JC; *Helicobacter pylori* persistence: biology and disease. J Clin Invest, 2004; 113: 321.
5. Atisook K, Kachinthorn U, Luengrojanakul P, Tanwadee T, Pakdirat P, Puapairoj A; Histology of gastritis and *Helicobacter pylori* infection in Thailand: a nationwide study of 3776 cases. *Helicobacter*, 2003; 8: 132-41.
6. Noffsinger E, Stemmermann N, Lantz E, Listrom B, Rilke O; The non-neoplastic stomach. Cecilie M Fenoglio Prieser, Gastrointestinal pathology an atlas and text by Lippincott, Williams & Wilkins, 1999; 175-191.
7. Weill FX, Margeridon S, Broutet N, Le Hello S, Neyret C, Megraud F; Seroepidemiology of

- Helicobacter pylori infection in Guadeloupe. Trans R Soc Trop Med Hyg, 2002; 96: 517-519.
8. Quieroz DMM, Luzza F; Epidemiology of Helicobacter pylori infection. Helicobacter, 2006; 11: 1-5.
 9. Santos IS, Bocio J, Santos AS, Valle NCJ, Halal CS, Bachilli MC, Lopes RD; Prevalence of Helicobacter pylori infection and associated factors among adults in Southern Brazil: demographic, lifestyle and environmental factors. Brazilian J Inf Dis, 2005; 9: 405-10.
 10. Petersson F, Borch K, Franzen LE; Prevalence of subtypes of intestinal metaplasia in the general population and in patients with autoimmune chronic atrophic gastritis. Scand J Gastroenterol, 2002; 37: 262-66.
 11. Hui PK, Chan WY, Cheung PS, Chan JK, Ng CS; Pathologic changes of gastric mucosa colonized by Helicobacter pylori. Hum Pathol, 1992; 23:548-56.
 12. Hackelsberger A, Platzer U, Nilius M, Schultze V, Gunther T, Dominguez-Munoz JE, Malfertheiner P; Age and Helicobacter pylori decrease mucosal surface hydrophobicity independently. Gut, 1998; 43: 465-469.
 13. Ohkusa T, Takashimizu I, Fujiki K, Suzuki S, Shimoi K, Horiuchi T, Tanizawa T; Disappearance of hyperplastic polyps in the stomach after eradication of Helicobacter pylori: a randomized, controlled trial. Annals of internal medicine, 1998;129(9):712-715.
 14. Carneiro F, Soares J, Cotter J, et al : Incidencia Y características de la infección por Helicobacter pylori en el Norte de Portugal. Rev Esp Enferms Dig 1992; 81: 95-96.
 15. Testoni PA, Bonassi U, Bagnolo F, Colombo E, Scelsi R; In diffuse atrophic gastritis, routine histology underestimates Helicobacter pylori infection. J Clin Gastroenterol, 2002; 35(3): 234-239.
 16. Valle J, Kekki M, Sipponen P, Ihamaki T, Siurala M; Long-term course and consequences of Helicobacter pylori gastritis: results of a 32-year follow-up study. Scand J Gastroenterol, 1996; 31: 546-550.
 17. Chen XY, Liu WZ, Shi Y, Zhang DZ, Xiao SD, Tytgat GNJ; Helicobacter pylori associated gastric diseases and lymphoid tissue hyperplasia in gastric antral mucosa. J Clin Pathol, 20002; 55: 133-137.
 18. Dhillon AP, Sawyerr A; Granulomatous associated with Campylobacter pylori. APIMS, 1989; 97: 723-27.
 19. Ogihara A, Kikuchi S, Haregawa A, Kurosawa M, Miki K, Kaneko E, Mizukoshi H; Relationship between Helicobacter pylori infection and smoking and drinking habits. Journal of Gastroenterology and Hepatology, 2000; 15: 271-276.
 20. Hermann B, Rothenbacher D, Bode G, Adler G; Relation of smoking and alcohol and coffee consumption to active Helicobacter infection: Crosssectional study. BMJ, 1997; 315: 1489-1492.
 21. Luzza F, Imeneo M, Maletta M, Paluccio G, Giaccotti A, Perticone F, Pallone F; Seroepidemiology of Helicobacter pylori infection and Hepatitis A in rural area: evidence against a common mode of transmission. Gut 1997; 41: 164-8.
 22. Rajendra S, Ackroyd R, Robertson IK, Ho JJ, Karim N, Kutty KM; Helicobacter pylori, ethnicity and the gastroesophageal reflux disease spectrum: a study from the East. Helicobacter, 2007; 12: 177-183.