

## **Research Article**

# **Quick repair of medium sized umbilical hernias with a self gripping preperitoneal mesh**

**Arkadiusz Peter Wysocki**

Logan Hospital, Corner Armstrong and Loganlea Roads, Meadowbrook, Queensland 4131, Australia

**\*Corresponding author**

A. Peter Wysocki

Email: [arek\\_p@ecn.net.au](mailto:arek_p@ecn.net.au)

---

**Abstract:** Mesh repair is indicated for medium sized umbilical hernias (larger than 2 – 4 cm). Preperitoneal placement of self gripping mesh would be expected to be difficult due to its self gripping property and the small working space. The author evaluated the time taken to place Covidien Parietex Pro Grip mesh in the preperitoneal plane during adult medium sized umbilical hernia repair. In results 13 primary umbilical hernias were repaired. Defects ranged between 3 cm and 4 cm. Median mesh diameter was 7 cm. Median time taken to place the mesh was 180 seconds. There have been no recurrences or surgical site complications. In conclusion with good outcomes, a short learning curve and easy placement, Parietex Pro Grip mesh is well suited to preperitoneal repair of adult medium sized primary umbilical hernias.

**Keywords:** umbilical hernia, repair, mesh

---

## **INTRODUCTION**

While exact epidemiological data is lacking, around a quarter of the adult population will have a clinical umbilical hernia[1]. Around 10% of umbilical hernias are repaired[1]. The European Hernia Society classifies umbilical hernias smaller than 2cm as small and those larger than 4cm as large[2]. In one large study, adult umbilical hernias smaller than 3cm repaired primarily had only a 6% recurrence rate at almost 6 years follow up[3]. Routine prosthetic repair is probably indicated for defects larger than 3 cm[1].

Parietex Pro Grip mesh (Covidien, Australia) is typically used for open inguinal hernioplasty[4]. It has also been used as an only mesh during incisional hernia repair[5]. The author has routinely used Pro Grip mesh in the preperitoneal plane as part of elective medium sized adult umbilical hernia repair since June 2011. Pro Grip is composed of absorbable poly lactic acid hooks on one surface of a lightweight monofilament polyester mesh. The hooks provide Velcro (Velcro Industries, Curaçao) type adhesion to both the mesh itself and soft tissue. This self fixation would be expected to make the mesh difficult to work with in a small space. This study was designed to document the time taken to place a flat Parietex Pro Grip mesh in the preperitoneal plane during medium sized primary elective adult umbilical hernia repair.

## **METHOD**

Fit patients with a symptomatic umbilical hernia are offered elective repair when seen in clinic. All defects smaller than 2cm at time of surgery are

repaired primarily. Until June 2011 the author repaired all defects larger than 2cm with preperitoneal PROLENE mesh (Ethicon, Australia) secured with transfascial PROLENE sutures (Ethicon, Australia). Parietex Pro Grip mesh (Covidien, Australia) became the author's choice of mesh from June 2011 for all defects larger than 2cm. The period of this study is from June 2011 to October 2014.

All mesh repairs were elective day case procedures under General Anaesthesia with routine Local Anaesthetic infiltration. Intravenous prophylactic antibiotics were routinely administered. Following a routine surgical approach, the defect was exposed and preperitoneal fat reduced. The preperitoneal plane was dissected using scissor or cut diathermy dissection for at least 2 cm on all sides of the defect. Peritoneal defects were closed with an absorbable suture. The cavity was irrigated. Unsecured Parietex Pro Grip mesh (Covidien, Australia) was placed in the preperitoneal plane. The hooks were placed facing up to the posterior rectus sheath. Drains were not used. The defect was closed horizontally over the top of the mesh with a no absorbable suture. Hydro dissection and enlargement of the defect were not performed. The medical record for all 13 patients was reviewed to determine whether there were any representations to the Emergency department or other medical or surgical services or clinics with a complication or recurrence.

## **RESULTS**

Over almost 3 and half years, 13 primary umbilical hernias were repaired by the author using

Parietex Pro Grip mesh (Covidien, Australia) at Logan public Hospital in Queensland, Australia. During this time another 51 primary umbilical hernia repairs were performed (mean size of defect 1.7cm) – these patients were excluded from this study. Defects ranged between 3 cm and 4 cm with four patients having two peri umbilical defects. Mesh diameter varied from 6cm to 9cm (median 7cm). Time taken to place the mesh

ranged from 75 seconds to 360 seconds (median 180 seconds) as illustrated in Graph 1.

Follow up data was available for only 6 patients (range 11 – 976 days). There have been no surgical site complications or recurrences. One patient presented with renal colic three years post operatively – the Computed Tomography scan (Figure 1) shows flat mesh which has not migrated.

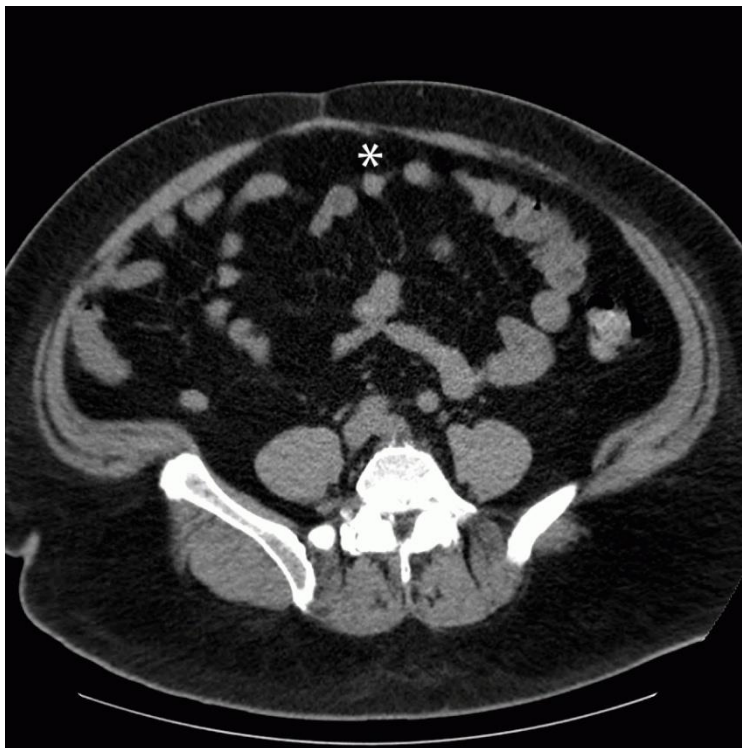
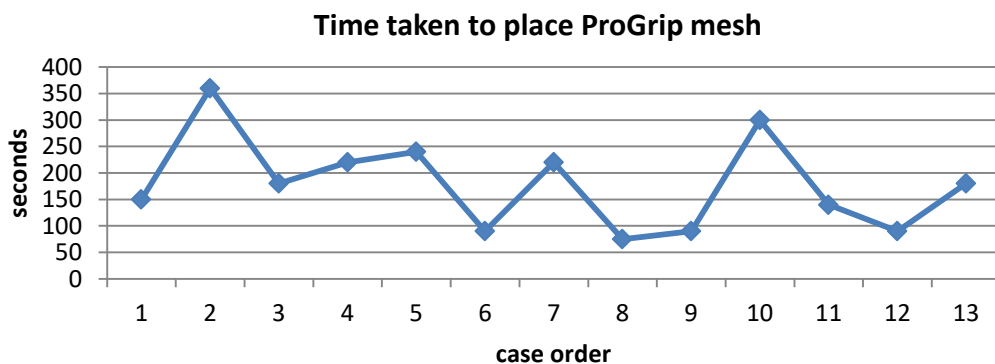


Fig- 1: Abdominal Computed Tomography scan showing flat preperitoneal mesh (\* asterisk)



Graph 1. Time taken to place Parietex Pro Grip mesh (Covidien, Australia).

**DISCUSSION**

This study demonstrates placing a self gripping mesh in the preperitoneal plane is not difficult or prolonged. By eliminating dissection of the anterior abdominal wall ventral to the defect, this technique may reduce the rate of seroma formation and Surgical Site infection. Prior to adopting Pro Grip, the author would

dissect out the preperitoneal pocket and then mobilise the fat off the anterior rectus sheath (this took approximately 2 minutes; unpublished data) to allow transfascial non absorbable suture mesh fixation (9 minutes; unpublished data). However, self fixation of Pro Grip means time and periumbilical perforators are

saved as this plane does not need to be opened as suture fixation is not necessary.

Development of adult umbilical hernias has been associated with obesity, multiparity, malignancy and ascites[6]. The ideal method of repairing umbilical hernias continues to be elusive. A recent meta analysis of three small randomised controlled studies concluded the use of mesh in repairing umbilical defects smaller than 4 cm is associated with one tenth the recurrence rate compared to primary repair [7]. Others have shown that primary repair of medium sized umbilical hernias is safe with only a 4% rate of recurrence [6]. Other authors have suggested the use of mesh may mask poor surgical technique [8]. The potential for enterotomy tarnishes the laparoscopic approach [9].

Self fixation of Pro Grip also results in mesh self adherence which impairs handling and may be anticipated as being difficult. However, with good retraction and handling the mesh with two nontoothed forceps, this step takes approximately three minutes. Placing Pro Grip during laparoscopic inguinal hernia repair has a learning curve of about 10 operations[10] and is probably shorter for umbilical hernias.

#### CONCLUSION

Using Covidien Parietex Pro Gripmesh to repair adult primary medium sized umbilical hernias is feasible, takes a short amount of time but requires further study.

#### REFERENCES

1. Earle DB, McLellan JA; Repair of umbilical and epigastric hernias. *The Surgical clinics of North America* 2013;93(5):1057-89
2. Muysoms FE, Miserez M, Berrevoet F, Campanelli G, Champault GG, Chelala E *et al.*; Classification of primary and incisional abdominal wall hernias. *Hernia* 2009;13(4):407-14
3. Dalenback J, Andersson C, Ribokas D, Rimbäck G; Long-term follow-up after elective adult umbilical hernia repair: low recurrence rates also after non-mesh repairs. *Hernia* 2013;17(4):493-7
4. Zhang C, Li F, Zhang H, Zhong W, Shi D, Zhao Y; Self-gripping versus sutured mesh for inguinal hernia repair: a systematic review and meta-analysis of current literature. *The Journal of surgical research* 2013;185(2):653-60
5. Hopsons S; Parietex ProGrip™ Self-Gripping Mesh for Open Incisional Hernia Repair. Secondary Parietex ProGrip™ Self-Gripping Mesh for Open Incisional Hernia Repair 2012. <https://www.youtube.com/watch?v=CFt1DUiBBL0>
6. Yao JJ, Pham T, Mokdad AE, Huerta S; Predictors of recurrence of umbilical hernias following primary tissue repair in obese veterans. *American journal of surgery* 2015
7. Aslani N, Brown CJ; Does mesh offer an advantage over tissue in the open repair of umbilical hernias? A systematic review and meta-analysis. *Hernia* 2010;14(5):455-62
8. Gardiner A, Drummond R, Stevenson R; Re: Long-term recurrence and chronic pain after repair for small umbilical or epigastric hernias: a regional cohort study. *The American Journal of Surgery* 2015
9. Malik AM; Laparoscopic versus open repair of para-umbilical hernia. Is it a good alternative? *JPMA The Journal of the Pakistan Medical Association* 2015;65(8):865-8
10. Erbella J, Erbella A; Laparoscopic Extraperitoneal Inguinal Hernia Repair Using a Novel Mesh with Self-Fixating Properties. *Surgical Science* 2013;4:3