

Original Research Article

Meckel's Diverticulum, Presentation and its Management at Basaveshwara Teaching and General Hospital

Dr Nitin Kalaskar¹, Dr Puneeth Thalasta²

¹Assistant Professor, Department of Surgery, M R Medical College, Kalaburagi. PIN: 585105

²Post Graduate, Department of Surgery, M R Medical college, Kalaburagi. PIN: 585105

***Corresponding author**

Dr Puneeth Thalasta

Email: puneeththalasta17@gmail.com

Abstract: Meckel's Diverticulum has an estimated prevalence of 1.2% of the population. Most cases are asymptomatic and the diagnosis is often made intra-operatively. Surgical resection is the treatment of choice in patients with symptomatic Meckel's Diverticulum or in cases of complication such as obstruction, bleeding or Meckel's diverticulitis. Some of the presentations may be in the form of ulceration, haemorrhage, intussusception, intestinal obstruction, perforation and very rarely, vesicodiverticular fistulae and tumours. However, the management of asymptomatic incidentally discovered Meckel's Diverticulum has been more controversial. We are presenting a study of five cases of Meckel's diverticulum with varied presentations during a span of 1 year in our institution of which three case presented as intestinal obstruction, one as obstructed hernia (Littre's hernia) and one as acute appendicitis.

Keywords: Meckel's Diverticulum, Littre's Hernia, intussusception.

INTRODUCTION

Meckel's diverticulum was first described in a paper published in 1809 by the German anatomist, Johann Friedrich Meckel, the younger (1781–1833), who described it as a remnant of the omphalo-mesenteric duct[1], although such an abnormality had been mentioned quite early by Fabricius Hildanus in 1598 and in 1671 by Lavater (who did not recognize its embryological origin). However, it was not until almost 100 years later that the understanding of Meckel's diverticulum increased with the discovery of ectopic gastric mucosae by Salzer and associated ulceration of ileum by Deetz[2]. In the fetal life, the omphalo-mesenteric duct connects the yolk sac to the intestinal tract and usually it obliterates in the 5th to 7th week of life. If obliteration fails, the congenital anomalies develop, leading to the residual fibrous cords, umbilical sinus, omphalo-mesenteric fistula, enterocyst and most commonly, Meckel's diverticulum. It represents the patent intestinal end of the vitello intestinal duct. It possesses all three coats of intestine. In 20% of the cases the mucosa contains heterotopic gastric, colonic, or pancreatic tissue. It presents in 2% of the population at a ratio of three male to one female. Its usual location is 30-60 cm from ileocecal valve. The presence of this heterotopic tissue may lead to other complications like haemorrhage, chronic peptic ulceration, and perforation.

It generally remains silent but it may present with life threatening complications like intestinal obstruction, perforation, haemorrhage[3], etc. These complications present with nonspecific symptoms which mimic common gastrointestinal disorders[4] like appendicitis, making diagnostic difficulty. Most of the cases are diagnosed intraoperatively.

Meckel's diverticulum is a true diverticulum containing all layers; it is usually situated on the antimesenteric border, approximately seen in 2% of population. Most patients are asymptomatic and the life time risk of the developing complications is 4-6%[5]. Haemorrhage is the most common complication in adults and the second most in children; it is due to presence of heterotopic gastric or pancreatic mucosa causing ulceration of adjacent ileal mucosa. Obstruction due to Meckel's diverticulum is the most common complication in children and second most common complication in adults[6]. Obstruction is due to volvulus or intussusception or Littre's hernia or adhesion and kinking or due to stricture secondary to chronic diverticulitis[7]. Complications of Meckel's diverticulum include haemorrhage, obstruction, diverticulitis and perforation and technetium 99 m pertechnetate scan is used for diagnosis which is highly sensitive and specific in both paediatric and adult

population[7,8]. Other diagnostic modalities include capsule endoscopy and angiography. If conservative methods fail to control haemorrhage diverticulectomy or ileal segment resection with end to end anastomosis are done. Perforation is due to diverticulitis or ulceration due to heterotopic mucosa or rarely due to foreign body (like fish bone, chicken bone, etc.).

Treatment of perforation is segmental resection with end to end anastomosis. Pathophysiology of diverticulitis is similar to that of acute appendicitis, with inflammation secondary to stasis (due to fecolith or parasites or foreign body) and bacterial infection[8,9]. It may also result from heterotopic mucosa. Usually, treatment is diverticulectomy.

We are reporting here a series of five cases of Meckel's diverticulum with varied presentations in 1 year which were operated on emergency:

- One case presented as intestinal obstruction because of intussusception with Meckel's diverticulum as a lead point with gangrenous bowel.
- The second case presented as intestinal obstruction with blind Meckel's diverticulitis adherent to urinary bladder with malrotation of intestines.
- Third case presented as a case of direct inguinal hernia involving Meckel's diverticulum measuring 4 cm in length. The diverticulum along with gangrenous ileal segment was resected and end to end anastomosis done with single layered suturing.
- Fourth case presented with symptoms of acute appendicitis with right iliac fossa McBurney's point tenderness which on table found to have Meckel's diverticulum with ileal perforation with normal appendix.
- Fifth case presented as acute intestinal obstruction with internal bowel- bowel herniation with gangrene.

MATERIALS AND METHODS

This clinical study was carried out on patients who presented with acute abdomen to casualty of Basaveshwar Teaching and General Hospital, Kalaburagi and were subjected to exploratory laparotomy and were found to have Meckel's diverticulum as an intraoperative finding from October 2015 to October 2016.

CASE SERIES

CASE 1

A 17 year old boy presented to the emergency with complaints of abdominal pain, distension of abdomen of 4 days duration associated with vomiting 3-

4 episodes. Pain was colicky type. On examination vitals were within normal limits, abdominal distension was present with increased bowel sounds (Borborygmi). A clinical diagnosis of intestinal obstruction was made and confirmed by plain erect X-ray abdomen (showed multiple air fluid levels) and ultrasound abdomen (was in favour of ileo-ileal intussusception). Diagnosis of small bowel obstruction was made and on laparotomy ileo-ileal intussusception with gangrenous bowel was noted, which on reduction showed a Meckel's diverticulum which in turn was acting as a lead point for intussusception. Resection and anastomosis of the gangrenous bowel involving a Meckel's diverticulum was done. Post-operative period was uneventful.

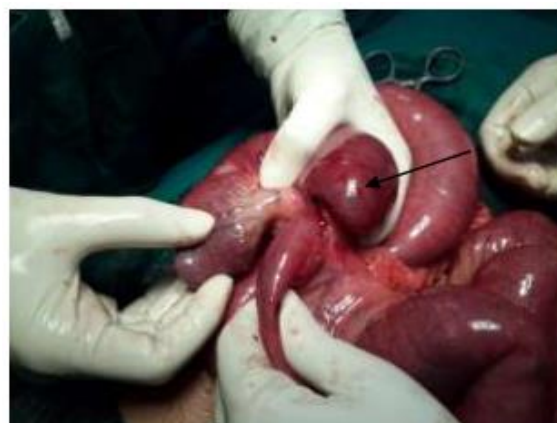

Fig-1: Ileo- ileal intussusception

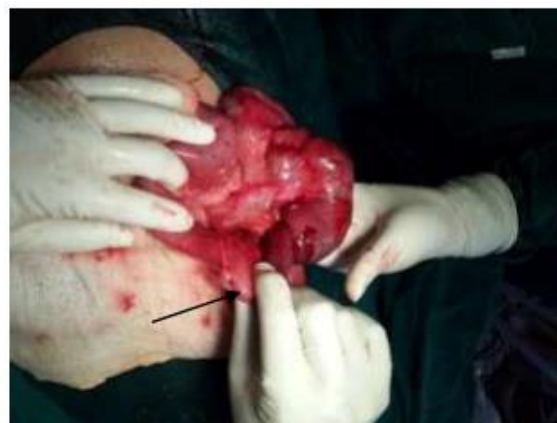

Fig-2: On partial reduction of intussusception buried Meckel's diverticulum with band was visualised

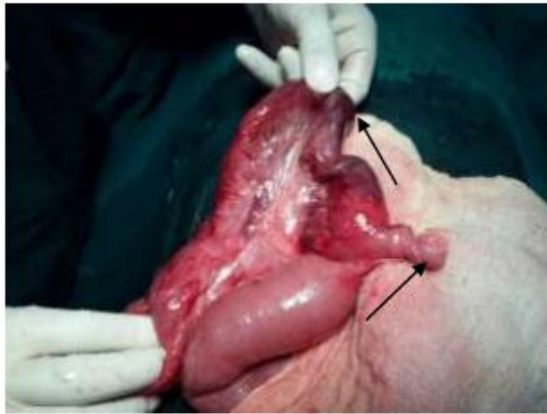

Fig-3: On complete reduction of intussusception gangrenous bowel visualised, Meckel's Diverticulum

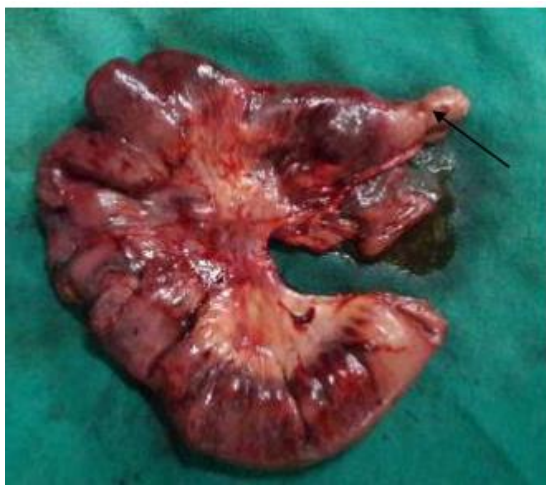

Fig-4: Meckel's Diverticulum

Resected specimen of gangrenous ileum along with Meckel's diverticulum.

CASE 2

A 16 year old male patient presented to emergency with abdominal pain, distension and vomiting since 3 days. Examination findings including ultrasound and erect X- ray abdomen were suggestive of acute intestinal obstruction. Patient was taken up for emergency exploratory laparotomy, which revealed an intestine like rotated tissue obstructing and strangulating ileum in right iliac fossa, that twisted coil was ending on the dome of bladder which on further exploration showed a blind Meckel's diverticulitis getting adherent to the dome of urinary bladder. This adherent Meckel's diverticulum was acting as a pivot for the coils to rotate around. Part of diverticulum adherent to the bladder was dissected and diverticulectomy was done along with derotation. Post - operative period was uneventful.

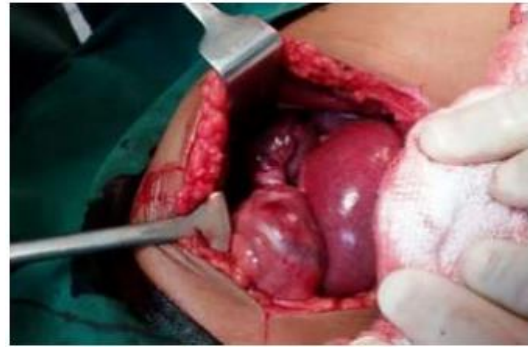

Fig-5: Intra operative picture of twisted meckels diverticulitis attached to dome of urinary bladder

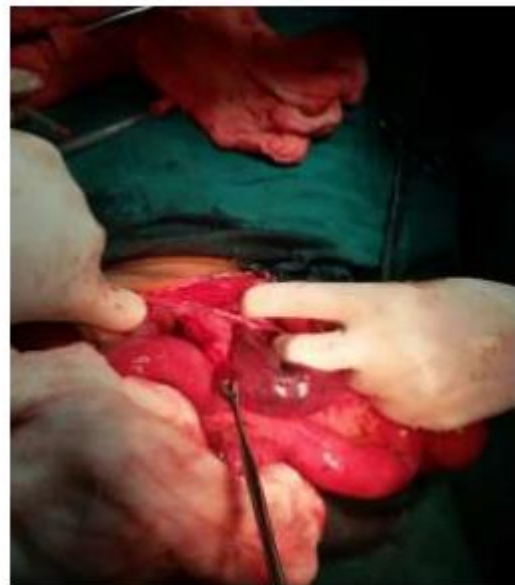

Fig-6: Intraoperative picture showing the point of twist that deliniates viable and strangulated part of meckels diverticulitis

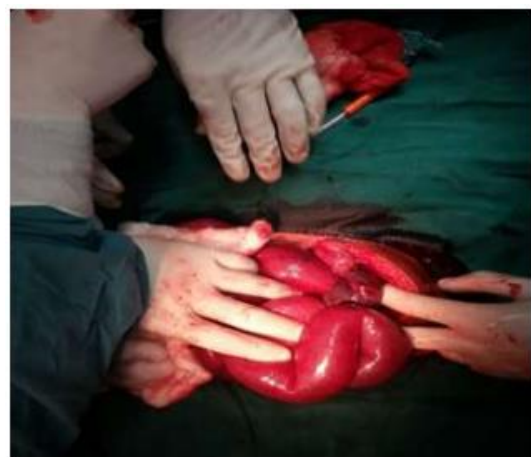

Fig-7: Intra operative picture showing excised meckels diverticulum attached to dome of urinary bladder

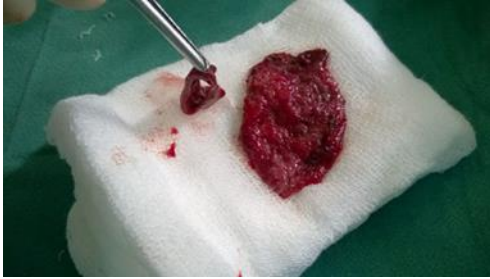

Fig-8: Opened meckel's diverticulum with variegated mucous membrane

CASE 3

A 60 year old male presented with complaints of swelling in left groin for past 20 years and asymptomatic for past 20 years, pain in the swelling associated with fever and redness over swelling for past 1 week and h/o constipation for past 4 days.

Examination revealed soft tender and painful swelling associated with erythema over swelling with local rise of temperature. Non reducible, no visible cough impulse.

Abdomen was mildly distended, soft, with no signs of peritonitis.

Erect X-ray abdomen and ultrasonography were suggestive of intestinal obstruction.

Inguinal incision was taken which was later converted into lower paramedian incision. A large direct hernia sac (pseudo sac) was dissected revealing a Meckel's diverticulum approximately 4 cm in length which was incarcerated and apex was necrosed. There was a posterior wall defect of 2×1 cm through which herniation of Meckel's diverticulum occurred. The diverticulum along with gangrenous ileal segment was resected and end to end anastomosis done with single layered suturing, the hernia was repaired without complication. Post-operative period was uneventful and discharged on post-operative day seven.

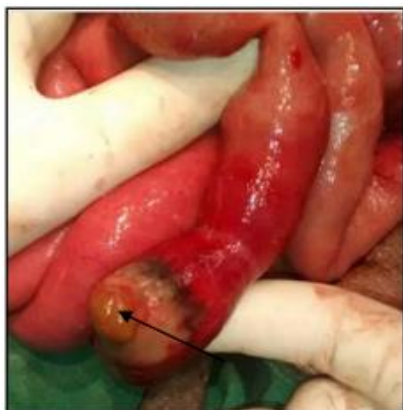

Fig-9: Incarcerated meckels diverticulum with necrosed tip

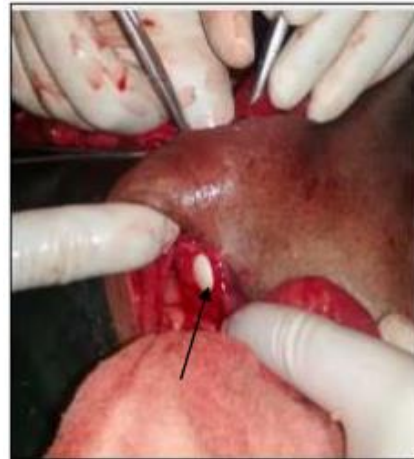

Fig-10: Defect in posterior wall

CASE 4

A 50 year old male presented to the casualty with complaints of pain abdomen and vomiting for 4 days and burning micturition since 2 days. On examination patient had right iliac fossa tenderness which was suggestive of acute appendicitis, ultrasonography was in favour of clinical examination i.e acute appendicitis. But, on opening the abdomen through right paramedian incision inflamed Meckel's diverticulum, gangrenous small bowel segment with perforation with normal appendix was visualised. Resection of the segment of a small bowel along with Meckel's diverticulum and end to end anastomosis was done. Post-operative period was uneventful.

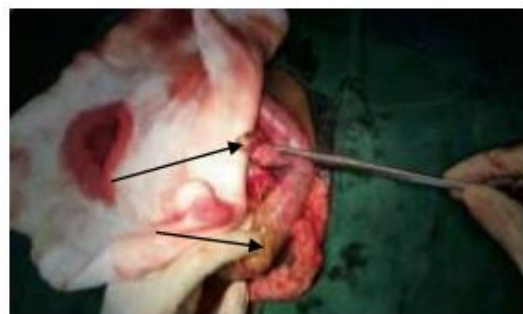


Fig-11: Meckel's Diverticulum, Perforated ileum

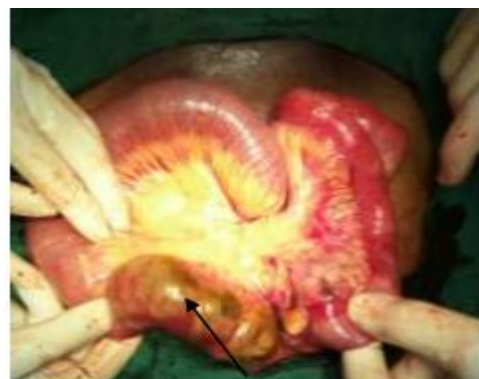

Fig-12: Gangrenous bowel

CASE 5:

A 11 year old boy presented to the casualty with complaints of pain abdomen and vomiting since 3 days. Clinical and radiological investigations were suggestive of small bowel obstruction. Patient was subjected for emergency laparotomy. Intra operatively multiple adhesions with severe bowel internal herniation with bowel gangrene and bowel wall oedema about 10 inches proximal to ileo- ceacal junction with Meckel's diverticulum visualised. Patient underwent derotation, resection of gangrenous bowel along with Meckel's diverticulum with colostomy and appendectomy.

RESULTS

This study includes five cases with various presentations of Meckel's diverticulum and its complications.

Table-1: Age of Presentation

AGE GROUP	NUMBER OF PATIENTS
10-20	3
21-30	0
31-40	0
41-50	1
51-60	1
61-70	0
70 and above	0
TOTAL	5

In the study majority of the patients who underwent surgery for complications arising from Meckel's diverticulum belonged to the age group of 10-20 years.

Table-2: Mode of Presentation

CLINICAL PRESENTATION	NUMBER OF PATIENTS
Intestinal Obstruction	3
Obstructed hernia	1
Acute appendicitis	1
TOTAL	5

In the study most of the patients presented with clinical symptoms of acute intestinal obstruction.

Table-3: Intraoperative Findings

FINDINGS	NUMBERS
INTUSSUSCEPTION	1
MECKEL'S DIVERTICULITIS	1
INTERNAL HERNIATION	1
HOLLOW VISCUS PERFORATION	1
OBSTRUCTED HERNIA	1
TOTAL	5

Out of the five cases, three of them had presented to the casualty with symptoms of acute intestinal obstruction among those:

- One patient had ileo-ileal intussusception with Meckel's diverticulum acting as a lead point.
- Another patient had an intestine like rotated tissue obstructing and strangulating ileum in right iliac fossa, that twisted coil was ending on the dome of bladder which on further exploration showed a blind Meckel's diverticulitis getting adherent to the dome of urinary bladder. This adherent Meckel's diverticulum was acting as a pivot for the coils to rotate around.
- Another child had multiple adhesions with severe bowel internal herniation with bowel gangrene and bowel wall oedema about 10 inches proximal to ileo- ceacal junction with Meckel's diverticulum.

Another patient who presented to the casualty with features of acute appendicitis was found to have inflamed Meckel's diverticulum, gangrenous small bowel segment with perforation with normal appendix.

Another patient who presented with symptoms of obstructed hernia was found to have a large direct hernia sac (pseudo sac) revealing a Meckel's diverticulum approximately 4 cm in length which was incarcerated with necrosed apex.

These intraoperative findings show the various presentations of Meckel's diverticulum and also shows that both clinical and radiological findings may be confusing and will be difficult to arrive at an exact diagnosis and exploratory laparotomy remains the main stay of treatment.

DISCUSSION

According to the well-known statement of Charles Mayo, 'Meckel's diverticulum is frequently suspected, often looked for and seldom found'. Preoperative diagnosis of symptomatic Meckel's diverticulum is difficult. This is particularly true in the patients presenting with the symptoms other than bleeding.

The preoperative diagnosis of Meckel's diverticulum is still an outstanding challenge we do often come across cases that are misdiagnosed or not diagnosed preoperatively. In doubtful cases, laparoscopy is a preferred diagnostic modality[10]. However, technetium-99m pertechnetate scan is the most common and accurate non-invasive investigation performed for these cases. Harper *et al.* introduced the scan in 1962 as a method of diagnosing Meckel's

diverticulum because of tracer's propensity to concentrate in ectopic gastric mucosa; but Jewett *et al.* were the first to apply it clinically[11].

Pre-operative diagnosis is rare in uncomplicated cases, and the diverticulum is usually observed incidentally, during other procedures for various reasons. "Rule of two" is characteristic for Meckel's diverticulum, which includes the prevalence in 2% of the population; it is usually diagnosed under the age of two; it is in two-inches size and 2 cm diameter, two feet proximal to the ileo-caecal valve, twice frequent in men, and symptomatic in 2% of the patients[12,13].

The management of symptomatic Meckel's diverticulum comprises surgical resection. A wedge resection of the Meckel's diverticulum is generally carried out, and occasionally some ileum is resected by end-to-end anastomosis, diverticulectomy for Meckel's diverticulum found incidentally has been criticized. The results of surgical excision are generally excellent. Among the patients operated on for complications of Meckel's diverticulum, the cumulative incidence of early post-operative complications was 12%, including mainly wound infection (3%), prolonged ileus (3%), and anastomotic leak (2%). The mortality rate was 1.5%. The cumulative incidence of late post-operative complications during a 20 years follow-up was 7%. Incidental diverticulectomies are safer, with an overall rate of morbidity of 2% and a mortality of 1%[14]. Due to the difficulty of diagnosing a pathologic Meckel's diverticulum pre-operatively, many surgeons recommend prophylactic diverticulectomy in those found incidentally. This recommendation is based on lower morbidity rates when compared to the resection of pathologic diverticula[15].

CONCLUSION

A preoperative diagnosis of a complicated Meckel's diverticulum may be challenging because of the overlapping clinical and imaging features of other acute surgical and inflammatory conditions of the abdomen. An adequate knowledge of embryological, clinical, pathologic and radiologic characteristics of Meckel's diverticulum will aid the early and accurate diagnosis of complicated cases.

The present study of five cases of Meckel's diverticulum with varied presentations highlights its importance in many aspects. It is difficult to make a pre-operative clinical diagnosis and most of the times it is an intra-operative diagnosis. In suspected appendicitis during surgery, exploration of small bowel should be done to rule out Meckel's diverticulum, especially when the appendix appears normal.

In our study majority of the patients belonged to the age group of 10-20 years with the most common presentation was that of acute intestinal obstruction.

The optimum management of an asymptomatic Meckel's diverticulum discovered at laparotomy for a separate indication still remains unclear.

REFERENCES

1. Meckel JF. Uber die divertikel am darmkanal. Arch Physiol 1809; 9:421-53.
2. Stone PA, Hofeldt MJ, Lohan JA, Kessel JW, Flaherty SK. A rare case of massive gastrointestinal haemorrhage caused by Meckel's diverticulum in a 53-year-old man. W V Med J 2005;101:64-6.
3. Kuwajerwala NK, Silva YJ. Meckels diverticulum. eMed J 2002;3:7.
4. Yahchouchy EK, Marano AF, Etienne JC, Fingerhut AL. Meckel's diverticulum. J Am Coll Surg. 2001;192:658-62.
5. Raymond P. Adjunctive procedure in intestinal surgery. Mastery of Surgery. 5th ed. Wolters Kulwer Health/Lippincott Williams & Wilkins :Philadelphia; 2007. p. 1392-3.
6. Peranteau WH, Smink DS. Appendix, Meckel's and other Small Bowel Diverticula: Maingot's Abdominal Operations. 12th ed. New York: McGraw Hill Professional; 2013. p. 643-4.
7. Horn F, Trnka J, Simicková M, Duchaj B, Makaiová I. Symptomatic Meckel's diverticulum in children. Rozhl Chir 2007;86:480-2.
8. Sagar J, Kumar V, Shah DK. Meckel's diverticulum: A systematic review. J R Soc Med 2006;99:501-5.
9. Chirdan LB, Yusufu LM, Ameh EA, Shehu SM. Meckel's diverticulitis due to Taenia saginata: Case report. East Afr Med J 2001;78:107-8.
10. Shalaby RY, Soliman SM, Fawy M, Samaha A. Laparoscopic management of Meckel's diverticulum in children. J Pediatr Surg 2005;40:562-7.
11. Jewett TC Jr, Duszynski DO, Allen JE. The visualization of Meckel's diverticulum with 99mTc-pertechnetate. Surgery 1970;68:567-70.
12. Altaf A, Aref H. A case report: Cecal volvulus caused by Meckel's diverticulum. Int J Surg Case Rep 2014;5:1200-2.
13. Murruste M, Rajaste G, Kase K. Torsion of Meckel's diverticulum as a cause of small bowel obstruction: A case report. World J Gastrointest Surg 2014;6:204-7.
14. Cartenese C, Petitti T, Marineli E, Pignateli A, Maestingnetti D, Zuccarino M. Ferrozzi: Intestinal obstruction caused by torted gangrenous Meckel's

diverticulum encircling ileum. World J Gastrointest Surg 2001;27:106-9.

15. Seth A, Seth J. Axial torsion as a rare and unusual complication of a Meckel's diverticulum: A case report and review of the literature. J Med Case Rep 2011;5:118.