

Original Research Article

Frequency of Magnetic Resonance Imaging findings of Tuberculous Spondylitis in a Tertiary care Hospital of South India.

Dr. Nadeem Ahmed

Associate Professor, Department of Radiodiagnosis, Kakatiya Medical College, MGM Hospital, Warangal, 506002, Telangana, India

*Corresponding author

Dr. Nadeem Ahmed

Email: nadeem1975@rediffmail.com

Abstract: Tuberculous (TB) spondylitis is one of the commonest presentations of skeletal TB causing considerable morbidity due to its potential of causing deformity and neurological sequelae. Magnetic Resonance Imaging (MRI) is the diagnostic modality of choice to detect early TB and to know the extent of the disease. The objective of this study was to find out the frequency and pattern of various lesions of TB spondylitis on MRI. This was a prospective study in patients diagnosed as TB spondylitis. Axial and sagittal T1 weighted, T2 weighted and contrast enhanced T1 weighted images were studied. The frequency and pattern of different lesions of TB spondylitis causing abnormal signals in spinal and paraspinal areas was analysed. A slight female preponderance was seen with 52% females versus 48% males. Maximum cases were in 20 to 40 years age group. Most common region of involvement was thoracic vertebrae (38%) followed by cervical vertebrae (24%). Contiguous vertebral involvement was seen in 94% cases, disc involvement in 68% cases, paraspinal involvement in 76%, epidural involvement in 74% cases posterior element involvement in 18% cases, and deformity in 14% of the cases. About 76% discs showed peripheral pattern of enhancement. MRI features of Spinal TB are contiguous involvement of 2 vertebrae along with disc involvement, skip lesions and paraspinal collections. It also gives important information of involvement of spinal cord and extent of the disease. Hence early detection can lead to prompt treatment and can prevent complications.

Keywords: Magnetic Resonance Imaging, tuberculous spondylitis, post gadolinium, imaging features, Potts Spine.

INTRODUCTION:

Tuberculous spondylitis or Potts spine refers to an infection by *Mycobacterium tuberculosis* of one or more components of the spine namely the vertebrae, intervertebral discs, paraspinal soft tissue and the epidural space [1]. Incidence and prevalence of tuberculosis are high in developing countries like India. Spine tuberculosis is the commonest form of skeletal TB and constitutes 50% of all cases of TB of bones and joints and 0.5 to 1.5% of all cases of TB [2]. Patients usually present with backache, low grade fever, gibbus formation and sometimes with neurological deficits like paraplegia [3]. Hence spinal TB can lead to serious morbidity including permanent neurologic deficits and severe deformity. Tuberculous spondylitis is a curable disease and if early diagnosis and treatment are given it would avoid permanent deformities and neurological deficits [4].

It is usually the result of hematogenous dissemination from primary focus usually in the lungs

abdomen or lymph nodes [5]. The central type of vertebral TB spreads along the Batsons plexus of veins while paradiscal infection spreads through the arteries and the diagnosis can be delayed because of the indolent nature of the infection [6]. Magnetic resonance imaging is the modality of choice for diagnosis and finding the extent of the disease [7]. It is superior to plain radiography and CT scan in early diagnosis of TB, to detect marrow involvement, paravertebral extension and epidural involvement. MRI has the advantage of better contrast resolution for bone and soft tissues and examination in multiple planes [8]. In spinal TB MRI offers an excellent view of contiguous vertebral involvement, skip lesions, paraspinal collections, Sub ligamentous spread, spinal cord involvement and extent of epidural pus in patients with neurological deficits. Further response to treatment can be monitored [9, 10]. The objective of the present study was to analyze the magnetic resonance imaging features of TB spondylitis and to determine the frequencies of various types of

spinal and paraspinal lesions associated with TB spondylitis.

MATERIAL AND METHODS:

This was a descriptive prospective study done on patients in the department of radiodiagnosis at Kasturba medical college Manipal over a period of 3 years. All patients presenting with suspected or diagnosed tuberculous spondylitis based on clinical, radiological or microbiological evidence were included in the study. All MRI scans were performed on GE Signa 0.5 tesla MRI Scan. Sagittal, axial and coronal images were obtained with T1 and T2 weighted images by using spin echo and fast spin echo technique. Post contrast (Gandolinium DTPA 0.1 mmol/kg I.V) T1 weighted images were obtained in both sagittal and axial planes for better contrast resolution. Relevant data of each patient was collected and recorded in predesigned proforma. Patients having history of trauma to the spine, cases of old prolapsed disc, metastasis or with previous surgery were excluded from the study. MRI of cervical, thoracic and lumbar region was performed. Data was entered and analysed on SPSS 10 software. Frequencies and percentages were computed for gender, age, region of involvement, and different patterns of TB spondylitis.

RESULTS:

A total of 50 patients were included in this study out of which 24(48%) were males and 26(52%) were females. Table-1 shows the age distribution of our cases. Age of the patients ranged from 3 to 82 years with maximum number of cases in the age group of 20-40 years. Table-2 shows the clinical presentation of our cases. Backache(70%), paraspinal spasm(44%), fever(18%), limitation of mobility(26%) postural abnormalities(8%), neurological deficit(14%) and loss of bladder control(10%) were the presenting clinical symptoms and signs. ESR was raised in 38(76%) of the cases. Chest radiography showed involvement in

16(32%) cases. The disease process involved one spinal location in 7(14%) cases and multiple involvements in 43(86%) cases. Table-3 shows the region of the spine involved. Involvement was seen throughout the vertebral column with maximum involvement of the thoracic vertebra in 19 cases (38%) (figure 1) followed by cervical (24%) and lumbar(16%) vertebrae.(figure 2 and 3).The process involving 2 contiguous vertebrae was the most common pattern of involvement. (n=47 cases 94%). Skip lesions were seen in 6% of our cases. In the 50 patients studied by MRI 108 vertebrae were involved by the disease process. Table-4 shows the various lesions of tuberculous spondylitis seen on MRI. The most common pattern of signal intensity changes was hypo intensity on T1 weighted image in 92 vertebrae (85.16%) and hyperintensities on T2 weighted images in 93 vertebrae (86.11%). A hypo intense signal on T2 weighted images was seen in 10 vertebrae (9.3%). Intermediate signal intensity was seen in 15 vertebrae (13.8%) on T1 weighted images and 5 vertebrae (4.6%) on T2 weighted images. Disc space reduction was seen in 38 patients (76%) of our study of which 34(68%) showed features of discitis. In those cases in which contrast was given 72% of the involved discs showed peripheral pattern of enhancement. Contrast enhanced studies were done in 44 cases (88%). In 12 cases diffuse/in homogenous enhancement was noted. Peripheral enhancement was seen in 10 cases (22%) and mixed pattern was observed in 28 cases (56%) cases. Paraspinal abscesses were noted in 38 cases.(76%). Epidural abscess was noted in 74% of our cases. Out of the 108 vertebrae studied posterior element involvement was seen in 20 vertebrae (18%). Extension of the disease process to involve the adjacent ribs was seen in 3 (6%) cases. Deformity/dislocation was noted in 7(14%) of our cases. These included atlanto axial subluxation 1 case (2%), gibbus formation 5 cases (10%) and scoliosis 1 case (2%). Cord changes were seen in 6(12%) cases.

Table-1: Shows age distribution of patients of tuberculous spondylitis

Age distribution(years)	No of cases	Percentage (%)
0-10	1	2
11-20	5	10
21-30	12	24
31-40	14	28
41-50	5	10
51-60	7	14
61-70	3	6
71-80	2	4
81-90	1	2

Table-2: Shows region of involvement of spine with TB spondylitis

Region of spine	No of cases	Percentage
Cervical	12	24
Cervicodorsal	4	8
Dorsal	19	38
Dorsolumbar	3	6
Lumbar	8	16
Lumbosacral	4	8

Table-3: Shows clinical presentation of cases of TB spondylitis

Clinical features	No of patients	Percentage (%)
Backache/neck pain	35	70
Fever	9	18
Postural abnormalities	4	8
Paraspinal spasm	22	44
Limitation of mobility	13	26
Neurological deficit(sensory/motor)	7	14
Loss of bladder control	5	10

Table-4: Frequency and percentage of various lesions of tuberculous spondylitis on MRI

Spinal lesions	Frequency (108 vertebrae)	Percentage
Contiguous vertebral involvement	101	94%
Single vertebral involvement	15	14%
Skip lesions	7	6%
Disc space reduction	82	76%
Discitis	73	68%
Paraspinal abscess	82	76%
Epidural abscess	79	74%
Cord signal intensity change	13	12%
Posterior element involvement	19	18%
Rib involvement	7	6%
Atlantoaxial subluxation	2	2%
Gibbus formation	11	10%
Scoliosis	2	2%
Spread below ALL	65	60%

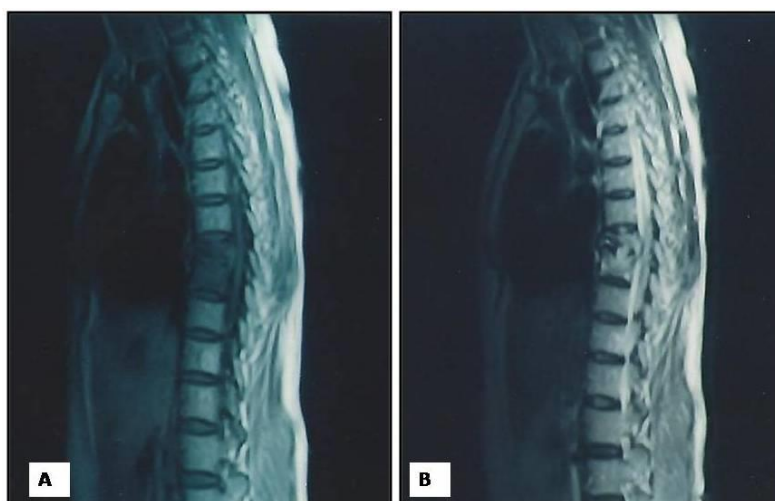

Fig 1 A and 1B -Sagittal T1W Image showing signal in D8 and D9 vertebrae with collapse of D9 vertebral body and D8-D9 intervertebral disc space. Sagittal T2W Image showing hyperintensity of the involved vertebrae and disc with anterior indentation of the thecal sac.

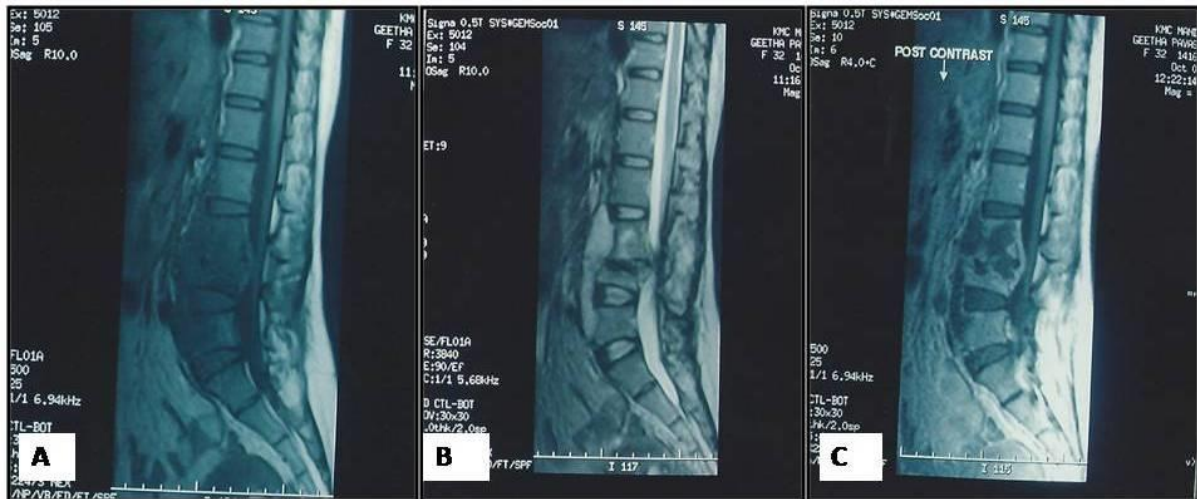


Fig 2A, 2B and 2C: Sagittal T1W and T2W images showing involvement of L3 and L4 vertebral bodies and intervertebral disc with compression over the thecal sac. Post contrast sagittal T1W image showing peripheral enhancement.

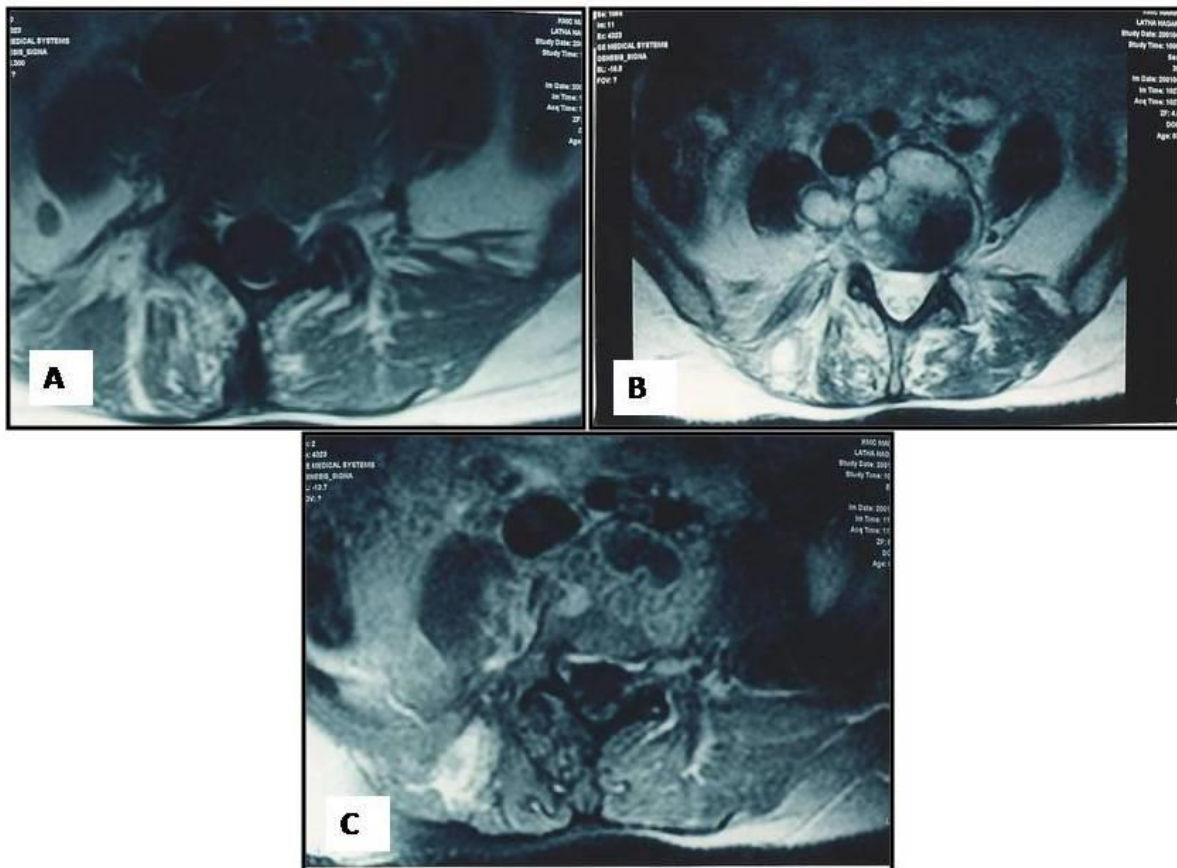


Fig 3A, 3B and 3C: Axial T1W image showing hypointense L5 vertebral body with loss of cortical definition. Hypointense lesions in right paravertebral soft tissue and paraspinal muscles. Lesions showing uniform hyperintense signal on T2WI. Post contrast T1WI shows rim enhancement of the involved tissues.

DISCUSSION:

Tuberculous spondylitis is caused by Mycobacterium Tuberculosis and its features were first described by Sir Pervical Pott in 1782 [11]. The basic pathology in TB spondylitis is a combination of

osteomyelitis and arthritis involving more than one vertebra [3]. In adults disc disease is secondary to the spread of infection from the vertebral body whereas in children it may be a primary site as the disc is vascularised [6]. MRI features of Potts spine are

abnormal signal intensities appearing hypointense on T1 weighted and hyperintense on T2 weighted sequences with heterogenous enhancement of vertebral bodies, reduction in disc height, destruction of 2 adjacent vertebral bodies and opposing end plates, destruction of intervening disc, occurrence of pre, para and epidural abscesses and vertebral body collapse [12]. Jung *et al.*; [13] stated that thin and smooth enhancement of abscess wall and well defined paraspinal abnormal signal is more in favour of tubercular abscess. Pyogenic and fungal spondylitis metastasis and lymphoma are close differential diagnosis for TB. Differentiating TB from these is important since the line of management is different. Early intervention helps in minimizing the residual spinal deformity and permanent neurological deficit. MRI plays an important role in diagnosis of TB with a high sensitivity and specificity as compared to other imaging modalities [12]. MRI has the advantage of improved contrast resolution for bone and soft tissues along with versatility of direct imaging in multiple planes [12].

This study on TB spondylitis showed a slight female preponderance with 52% females versus 48% males. Maximum number of patients in our study was in the 20 to 40 years age group. Similar findings have been reported by other studies from the developing world [9]. However many studies from the developed countries have shown male preponderance and majority patients in the older age group [13, 14]. This could be because TB is more common in our country affecting at a younger age due to poor nutrition, overcrowding and poor hygiene especially in the deprived socioeconomic group. In the developed countries the disease is AIDS related or is seen with other immunosuppressed conditions and diabetes [15]. The most common complaint was backache and limitation of mobility. Neurologic deficit was noted in 26% of our cases and 14% had loss of bladder control. Fever was seen only in 18% of our cases. These findings are in concordance with those reported by Yao *et al.*; and Le Page *et al.*; [16, 17]. The commonest region involved in our study was thoracic (38%) followed by cervical (24%) and lumbar (16%) region. Many studies have reported thoracic vertebrae to be the commonest site of involvement [5, 18]. Thoracic vertebrae are commonly involved because they get infected from the lungs via the hematogenous route. This is contrary to finding of Sinan *et al.*; where involvement was greater in lumbar spine [4]. The incidence of involvement of cervical spine was higher in our study as compared to others. Yao *et al.*; stated that involvement of cervical spine was more common in nonwhites [16]. A study from Mumbai has reported 30% involvement of cervical spine [19]. ESR was raised in 76% of the patients and chest involvement in 32% patients. Similar findings have been reported by Yao *et al.*; [16].

In 50 patients in whom MRI was done 108 vertebrae were involved. The most common pattern of signal intensity change was hypointense on T1 weighted and hyperintensity on T2 weighted image. However hypo intensity. Intermediate signal intensity was seen in 15 cases (13.8%) on T1 weighted image and 5(4.6%) on T2 image weighted image. Several studies have shown hypo intensity on T1 weighted images and hyperintensity on T2 weighted images [5, 18] Kim *et al.*; noted intermediate signal of involved tissues in T1 and T2 weighted images in 9% and 4.5% of their cases respectively [20]. Contiguous involvement of 2 or more vertebrae is seen in spinal TB by hematogenous spread through the one vertebral artery feeding 2 adjacent vertebrae. Contiguous vertebral involvement was seen in 94% of our cases and skip lesions were seen in 6% cases. Sumera *et al.*; found this pattern in 96.4% of their cases which is comparable to our study [2]. Sharif *et al.*; has reported incidence of skip lesions in TB spondylitis as 4% and our study is in agreement with their findings.[21]. In 86% of our cases multiple vertebral involvements was seen. Single vertebral involvement was noted in 14% cases while Kim *et al.*; have noted it in 5% cases [20] and Loke *et al.*; [22] in 7% of their cases. This discrepancy could be due to endemicity of TB in our population. It is likely that single vertebral body involvement represents an early stage of the disease. Most cases present with advanced disease due to insidious onset. In our study the disc space reduction was found in 38 cases (76%) and 34 (68%) showed features of discitis. Desai *et al.*; found discitis and disc space reduction in 50% of their cases [19] while Sharif Moore *et al.*; in 75% [21] and Zaidi *et al.*; in 77.3% [5] of their cases which is similar to our study. Few studies have reported spondylitis without disc involvement. This less aggressive behaviour has been attributed to lack of proteolytic enzymes in mycobacterium as compared to pyogenic infections resulting in relative preservation of the intervertebral disc. Paraspinal abscess was seen in 76% of our cases. Alotman *et al.*; have reported it in 80% of their cases [23] while Sumera *et al.*; have reported in 92% of their cases. [2] Epidural abscess was noted in 74% of our cases. Al Mulhim *et al.*; found epidural abscess in 61%, of their cases [24]. In those cases with paraspinal extension Muhlim *et al.*; [24] noted that 85% had an associated epidural component. Our findings are in agreement with their observations. Even though neurological deficit and epidural abscess were noted in a considerable number of our patients cord signal intensity changes on T2 weighted images were observed in only 6 cases (12%). Kuker *et al.*; found out focal hyperintensity in the spinal cord on T2 weighted images in only 1 out of 8 cases (12%) of epidural abscess [25]. They stated that lack of abnormal signal with good recovery post treatment indicates functional compromise of the cord. Out of the 108 vertebrae

involved posterior element involvement was seen in 20(18%) of them. Huma *et al.*; have reported posterior element involvement in 18% of vertebrae [5] while Desai *et al.*; in 12% cases [19]. The presence of posterior element involvement is a significant finding since these patients are more likely to have neurological involvement and require laminectomy. Extension of disease process to involve the adjacent rib on MRI was seen in 6% of our cases. Deformity/dislocation was noted in 14% of our cases including atlantoaxial subluxation (2%) gibbus formation (10%) and scoliosis in (2%) cases. These are common sequelae of spine TB. Gibbus deformity is considered specific for TB spondylitis and occurs due to anterior wedge compression of contiguous vertebrae as noted by Roos *et al.*; [8]. Gadolinium MRI is useful in characterising TB spondylitis. The presence of reactivation and abscess versus cellulitis is often diagnosed with confidence only after contrast study. In this study post contrast T1 weighted images showed heterogenous contrast enhancement or rim enhancement. This is due to presence of phlegmon and greatly improves our confidence to diagnose TB. This observation is in agreement with many other studies [13].

This study shows that MRI imaging is an invaluable and sensitive tool to detect spinal TB. The spectrum of MRI findings in TB spondylitis in this study is similar to other studies. It is a sensitive tool for diagnosis of spinal TB.

CONCLUSION:

Clinical manifestations of TB spondylitis that is fever, backache and focal tenderness are often insidious. Diagnosis of infection of spine requires a high index of suspicion. MRI is the image modality of choice for spinal TB and is more sensitive than methods. It provides diagnosis earlier than conventional methods conferring the benefits of earlier detection and treatment. MRI also gives information about the involvement of spinal cord and extent of epidural pus and posterior element involvement in patients with neurologic deficit. MRI with contrast helps in differentiating TB from other causes and to know the extent of the disease. Serial MRI can be useful to know the response to treatment and regression of the disease. Hence early MRI screening of patients suffering from backache and clinical suspicion of TB is suggested. Early diagnosis can prevent the morbidity associated with this curable disease.

REFERENCES:

1. Sharif HS, Morgan JL, Al Shahed MS, Al Thagafi MY. Role of CT and MR imaging in the management of tuberculous spondylitis. *Radiologic Clinics of North America*. 1995 Jul; 33(4):787-804.
2. Tabassum S, Haider S. Frequency of magnetic resonance imaging patterns of tuberculous spondylitis in a public sector hospital. *Pakistan journal of medical sciences*. 2016 Jan; 32(1):171.
3. Sivalingam J, Kumar A. Spinal Tuberculosis Resembling Neoplastic Lesions on MRI. *Journal of clinical and diagnostic research: JCDR*. 2015 Nov; 9(11):TC01.
4. Sinan T, Al-Khawari H, Ismail M, Ben-Nakhi A, Sheikh M. Spinal tuberculosis: CT and MRI feature. *Annals of Saudi medicine*. 2003 Dec; 24(6):437-41.
5. Zaidi H, Akram MH, Wala MS. Frequency and magnetic resonance imaging patterns of tuberculous spondylitis lesions in adults. *J Coll Physicians Surg Pak*. 2010 May 1; 20(5):303-6.
6. Kumar R. Spinal tuberculosis: with reference to the children of northern India. *Child's Nervous System*. 2005 Jan 1; 21(1):19-26.
7. Akman S, Sirvanci M, Talu U, Gogus A, Hamzaoglu A. Magnetic resonance imaging of tuberculous spondylitis. *Orthopedics*. 2003 Jan 1; 26(1):69-73.
8. Roos DA, Persijn VEL, Meerten V, Bloem JC, Bluemm RG. *AJR*. 1986;146:79-86.
9. Kostov K, Petrov I. Tuberculous spondylitis—analysis of 22 cases. *Acta Neurol Belg*. 2009 Jun 1; 109(2):127-31.
10. Polley P, Dunn R. Noncontiguous spinal tuberculosis: incidence and management. *European Spine Journal*. 2009 Aug 1; 18(8):1096-101.
11. Thrush A, Enzmann D. MR imaging of infectious spondylitis. *American journal of neuroradiology*. 1990 Nov 1; 11(6):1171-80.
12. Khattry N, Thulkar S, Das A, Khan SA, Bakhshi S. Spinal tuberculosis mimicking malignancy: atypical imaging features. *The Indian Journal of Pediatrics*. 2007 Mar 1; 74(3):297-8.
13. Jung NY, Jee WH, Ha KY, Park CK, Byun JY. Discrimination of tuberculous spondylitis from pyogenic spondylitis on MRI. *American Journal of Roentgenology*. 2004 Jun;182(6):1405-10
14. Chang MC, Wu HT, Lee CH, Liu CL, Chen TH. Tuberculous spondylitis and pyogenic spondylitis: comparative magnetic resonance imaging features. *Spine*. 2006 Apr 1; 31(7):782-8.
15. Khalequzzaman SI, Hoque HW. Tuberculosis of Spine Magnetic Resonance Imaging (MRI) Evaluation of 42 Cases. *Medicine Today*. 2013 May 18; 24(2):59-62.
16. Yao DC, Sartoris DJ. Musculoskeletal Tuberculosis. *Radiol Clin North Am*. 1995; 33(4):679-684.
17. Le Page L, Feydy A, Rillardon L, Dufour V, Le Hénanff A, Tubach F, Belmatoug N, Zarrouk V, Guigui P, Fantin B. Spinal tuberculosis: a longitudinal study with clinical, laboratory, and imaging outcomes. *In Seminars in arthritis and rheumatism* 2006 Oct 31 (Vol. 36, No. 2, pp. 124-129). WB Saunders.

18. Kotze DJ, Erasmus LJ. MRI findings in proven Mycobacterium tuberculosis (TB) spondylitis. South African Journal of Radiology. 2006 Feb 21; 10(2):6.
19. Desai SS: Early diagnosis of spinal TB by MRI. J Bone Joint Surg.1994; 76-863-869.
20. Kim NH, Lee HM, Suh JS. Magnetic Resonance Imaging for the diagnosis of TB Spondylitis. Spine 1994;19:2451-5
21. Sharif HS. Role of MR imaging in the management of spinal infections. AJR. American journal of roentgenology. 1992 Jun; 158(6):1333-45.
22. Loke TK, Ma HT, Chan CS. Magnetic resonance imaging of tuberculous spinal infection. Australasian radiology. 1997 Feb 1; 41(1):7-12.
23. Allothman A, Memish ZA, Awada A, Al Mahmood S, Al Sadoon S, Rahman MM, Khan MY. Tuberculous spondylitis: analysis of 69 cases from Saudi Arabia. Spine. 2001 Dec 15; 26(24):E565-70.
24. Al-Mulhim FA, Ibrahim EM, El-Hassan AY, Moharram HM. Magnetic resonance imaging of tuberculous spondylitis. Spine. 1995 Nov 1; 20(21):2287-92.
25. Küker W, Mull M, Mayfrank L, Töpfer R, Thron A. Epidural spinal infection: Variability of clinical and magnetic resonance imaging findings. Spine. 1997 Mar 1; 22(5):544-50.