

Original Research Article

**Morphometric study of the lumbar spinal canal and lumbar stenosis in Sudanese**Mohammed Ahamed Ahamed Abuelnour<sup>1</sup>, Nuha Salah Mohammed Hamdan<sup>2</sup><sup>1</sup>Department of human anatomy- Faculty of medicine & health sciences Gadarif University- Gadarif- Sudan<sup>2</sup>MSc in Human Anatomy- Department of human anatomy- Faculty of medicine - Ribat National University- Khartoum- Sudan**\*Corresponding author**

Mohammed Ahamed Ahamed Abuelnour

Email: [abuelnour88@yahoo.com](mailto:abuelnour88@yahoo.com)

---

**Abstract:** The lumbar canal stenosis is the narrowing of the spinal lumbar canal, which was associated with lower back pain and motor defects of lower limbs. The determination of normal antero posterior diameter of the lumbar spinal canal is essential in a reliable evaluation of lumbar stenosis. In this research we measured the anteroposterior diameter of the lumbar spinal canal in the normal adults and stenosis, patients, then the measurements was compared at different lumbar vertebral levels, and the causes of lumbar spinal canal stenosis was also investigated in this study. This is a prospective study conducted over a period of 23 month [ January 2013 – November 2014] using magnetic resonance imaging [MRI] in (100 samples ) 50 normal adults and 52 stenosis patients , where measurements of the antero posterior diameter of lumbar vertebral canal were made, and the results were recorded and the significance obtained was evaluate using Student t-test . The result showed that the incidences of lumbar spinal stenosis it's an age and gender dependent, the measurements of the antero posterior diameter revealed that the males lumbar spinal canal were slightly wider than those of the females, explaining the high incidence of lumbar stenosis in females compared with males. Although the mean value of measurements significantly increased steadily from L1 toward L5, the result of analysis of lumbar stenosis showed that the lumbar stenosis occur more frequently at the level of L5, due to degeneration and intervertebral disc herniation indicating the aging is the main factor in causes of the lumbar stenosis.

**Keywords:** Lumbar Vertebrae, Stenosis, Measurements, Morphometric.

---

**INTRODUCTION**

Lumbar spinal stenosis [LSS] is a medical condition in which the spinal canal narrows and compresses the spinal cord and nerves at the level of the lumbar vertebra. This is usually due to the common occurrence of spinal degeneration that occurs with aging. Sometime caused by spinal disc herniation, osteoporosis or a tumor. In the cervical [neck] and lumbar [low back] regions, it can be a congenital condition to varying degrees [1]. It is also a common symptom for those who suffer from various skeletal dysplasias such as with pseudo chondroplasia and achondroplasia at an early age. Spinal stenosis may affect the cervical or thoracic region in which case it is known as cervical spinal stenosis or thoracic spinal stenosis. In some cases, it may be present in all three places in the same patient. Lumbar spinal stenosis results in low back pain as well as pain or abnormal sensations in the legs, thighs, feet or buttocks, or loss of bladder and bowel control [2]. Understanding the meaning of signs and symptoms for the clinical syndrome of lumbar stenosis requires an understanding

of what the syndrome is, and the prevalence of the condition. A recent review on lumbar stenosis in the Journal of the American Medical Association's "Rational Clinical Examination Series[3]emphasized that the syndrome can be considered when lower extremity pain occurs in combination with back pain. This syndrome occurs in 12% of older community dwelling men and up to 21% of those in retirement communities [4] about 80% of people in industrial cities complain of low back pain and about 8 on each 11 people in USA had lumbar spinal stenosis [8].

In Rwanda 97% of causes of low back pain from mechanical process and about 70% from herniated intervertebral disc, spinal stenosis and fractures[9], and in Sudan many people complain of low back pain and one of the causes of this pain is spinal stenosis .The first symptoms of stenosis include bouts of low back or neck pain. After a few months or years, this may progress to claudication. The pain may be radicular, following the classic neurological pathways. This occurs as the spinal nerves or spinal cord becomes

increasingly trapped in a smaller space within the canal. It's difficult to determine whether pain in the elderly is caused by lack of blood supply or stenosis; testing can usually differentiate between them but patients have both vascular disease in the legs and spinal stenosis [5]. Low backache is a common problem which affects all classes of society; rich and poor, white and black, males and females. One of the causes of low backache is stenosis of the lumbar spinal canal, a condition in which the anteroposterior and lateral dimensions of the bony canal are less than normal for the relevant age and sex of the individuals [6].

Subsequently, there were many radiologic or anatomic morphologic studies regarding the size of the spinal canal in western and African countries [7, 17], to our knowledge, there has been no report in the literature about morphometric of the lumbar spinal canal in Sudanese.

The aim of the present study primarily is to determine the normal ranges of the antero posterior diameter of the lumbar spinal canal in normal adult Sudanese population. And study the causes of lumbar spinal stenosis in Sudanese people.

#### MATERIALS AND METHODS

The magnetic resonance imaging [MRI] of lumbar vertebral canal in 50 normal adult and 52 of patients suffering from the lower back pain and a degree of lower limb motor defect were used to study the measurements of the antero posterior diameter, in the period between January 2013 - November 2014. Using the computer system [Image Pulse], the antero posterior diameter of the lumbar canal was measured as a distance from the vertebral body to the point where the pedicles are fused at the most narrow area of the vertebral canal. For the sake of consistency, all measurements were taken by one observer and results were recorded as the mean  $\pm$ SD. To evaluate the significance of the results obtained, Student t-test were carried out; the results are considered significant if  $P \leq 0.05$ .

#### RESULTS AND DISCUSSIONS

To investigate the normal variations of the lumbar spinal canal, the anteroposterior diameter of the lumbar spinal canal was measured at the different levels of the lumbar vertebrae, and the results of the measurements were reported as the mean for each vertebral level separately in both males and females. The results show that the measurements for L1 was [17.89] mm , L2 [18.30 mm] , L3 [18.60 mm], L4 [18.66], L5 [20.19 mm] in males ,And the measurements for L1 [17.13 mm] L2 [18.20 mm], L3 [18.28 mm] L4 [ 18.48 mm ], L5 [19.16 mm] in females . These measurements introduced the average of the normal diameter of the lumbar spinal canal for males

and females respectively. [Fig-1] and the distance less than [11 mm] was considered as lumbar spinal stenosis. These results indicate that the anteroposterior diameter of the lumbar spinal vertebrae increased toward the caudal in both males and females, thus the fifth lumbar vertebra shows the largest diameter. The male vertebra show greater anteroposterior diameter compared with their partner females vertebra. Then the lumbar stenosis evaluated at the different levels of the lumbar vertebrae, and the incidence of stenosis in males and females was detected. The results show that the females represent higher incidence of lumbar stenosis compared with the males [Fig-2].

To evaluate the lumbar spinal stenosis the occurrences of the stenosis at each lumbar vertebra was detected in both males and females. the results indicates that , the lumbar spinal stenosis for males was 18 %,22%,29%,56%, and 80 % for L1,L2,L3,L4, and L5 respectively, and 24%, 36%, 44%, 62%, and 63% for L1,L2,L3,L4, and L5 respectively in females Fig [3].

The L5 represents the largest anteroposterior diameter and a common site of lumbar stenosis in both males and females. To explain the result the causes of the lumbar spinal stenosis was investigated, the result shows that the intervertebral disc herniation is the common causes of the lumbar spinal stenosis, and congenital stenosis and thickness of the posterior intervertebral ligament was detected as causes of lumbar spinal stenosis Fig [4].

The degenerative diseases has been reported as an age dependent diseases, we investigate whether the age is a dependent causative of the lumbar spinal stenosis, the result shows that there was a significant correlation between the age and spinal lumbar stenosis Fig [5].

The lumbar vertebrae have large kidney-shaped vertebral bodies, they have no costal articular surface but they have extensive spinous processes as well as pedicles and laminae, and the shape of the lumbar vertebral canal varies from oval to triangular. As a consequence of these characteristics the lumbar vertebrae are different from the other vertebrae [19].

The lumbar spinal canal contains the conus medullaris and the cauda equina within a dural sac as well as epidural vessels with a variable amount of fat outside the dura The bony wall of the canal is unyielding and there is a normally a certain minimal free space between the canal and the contents. This space allows for the free movement of the contents of the canal without tension or pressure during these movements. Therefore, the normal size of the canal is important. An abnormal reduction in the size of the lumbar spinal canal could predispose the individual to

lower back pain [20,17]. Anatomical narrowing of the lumbar vertebral canal and intervertebral foramina has been reported as the cause of compression of the cauda equina and the emerging nerve roots [21, 22]. Narrowing of the spinal canal may be developmental or it may be a result of degenerative changes many morphologic studies of the lumbar spinal canal have been concluded according to age, sex and race.

In 1977, Eisenstein reported the variations of the spinal canal in the Caucasian, African Zulu Negroid and South Negroid and concluded that the lumbar spinal canal was marginally less capacious in the Negroid than in the Caucasian. [16]. Amonoo-Kufi measured the mid-sagittal diameter of the Nigerian lumbar spinal canal and correlated the size of the canal with that of other black populations studied by Eisenstein [17]. The mid-sagittal diameter of the lumbar spinal canal was generally greater in the Nigerian male than in the black South African male.

The lowest normal limits of the antero posterior dimension of the lumbar canal in Chinese are 11 mm [18]. Magnetic resonance images [MRI] was used for evaluation of lumbar spinal stenosis, and this include, the incidence of stenosis, level of stenosis, causes and age of patients with lumbar stenosis. From the above results, the lumbar spinal stenosis occurred in female more than male and that explained from the measurements of antero posterior diameter of females, which is narrower than males, which predispose female to stenosis more than males. In the males, there is a steady widening of the diameter from the first lumbar vertebra to the fifth lumbar vertebra. The mean female antero posterior diameters were slightly narrower than those of the male and this explain the incidence of stenosis in female more than male, and the values of measurements from L1 to L5 were slightly convergent

which predispose female to the congenital stenosis or stenosis in more than one level.

Spinal stenosis [narrowing] is a common condition that occurs when the spinal canal, which contains nerve roots and spinal cord, becomes compressed. This causes a [pinching] of spinal cord and/or nerve roots, which lead to pain, cramping, weakness or numbness. Depending on where the narrowing takes place, you may feel these symptoms in the lower back and leg, shoulder, and arms. Usually, the narrowing caused by osteoarthritis, or “wear and tear” arthritis, of the spinal column and discs between the vertebrae [the bones of the back]. It may also cause by a thickening of the Ligaments in the back, as well as by a bulging of the discs that separate the vertebrae. Symptoms of Spinal stenosis often start slowly and get worse over time. Pain in the legs may become so severe that walking even for short distances is unbearable.[8] After about the fourth decade of life the spinal canal becomes narrowed by aging. Osteoarthritic changes in the joints of the articular processes with the formation of osteophytes, together with degenerative changes in the intervertebral discs and the formation of large osteophytes between the vertebral bodies, can lead to narrowing of the spinal canal and intervertebral foramina.

This study showed that, the people above forty years age predispose to stenosis this explain the relationship between aging and spinal stenosis. In congenital stenosis the spinal canal was originally small, significant stenosis in the cauda equina area can lead to neurologic compression, as indicated in this study the females lumbar spinal canal is originally smaller compared with males canals symptoms vary from mild discomfort in the lower back to severe pain radiating down the leg with the inability to walk.[23].

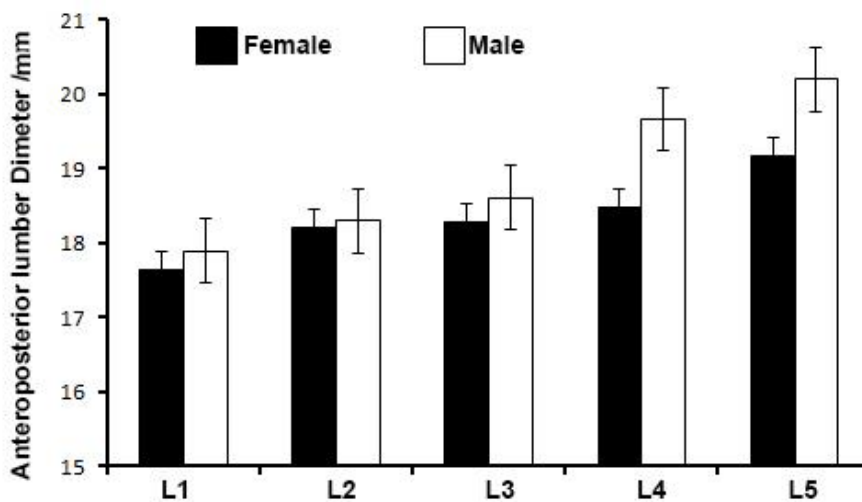


Fig 1 shows: the measurements of antero posterior diameter of lumbar spinal canal

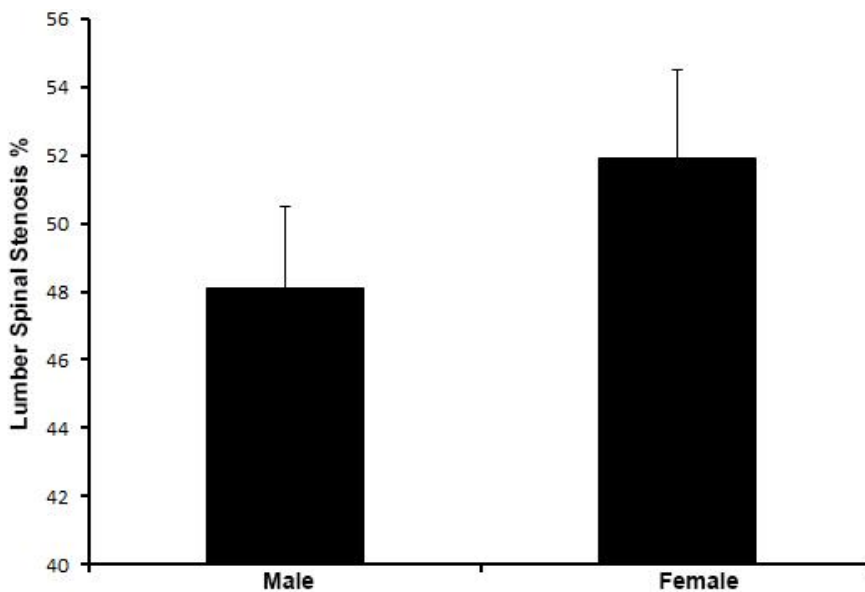


Fig 2 shows the gender distributions of the lumber spinal stenosis.

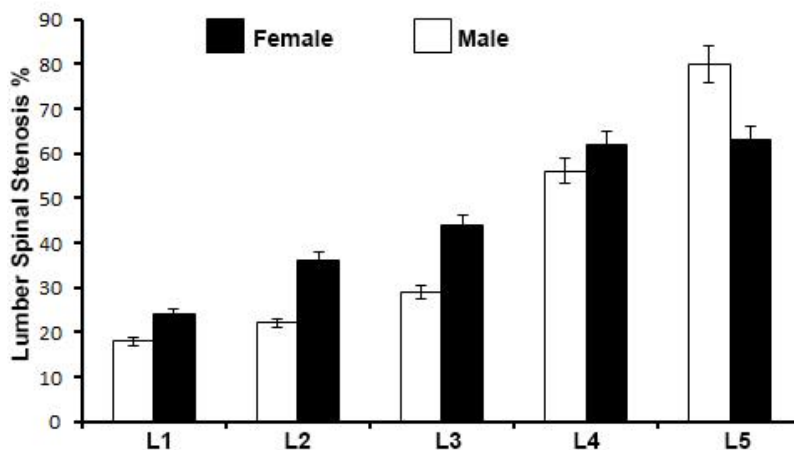


Fig 3 shows: the levels of lumbar spinal canal stenosis in Sudanese males and females.

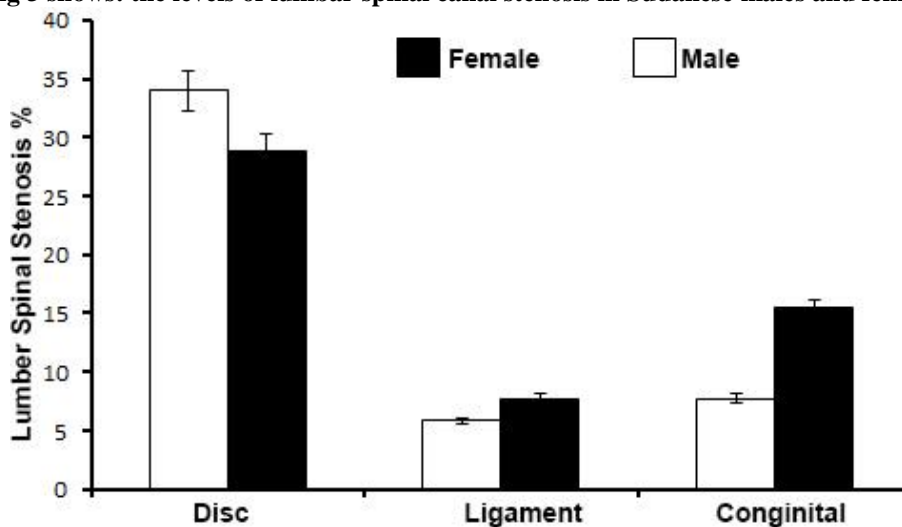


Fig 4 shows: causes of lumbar spinal stenosis

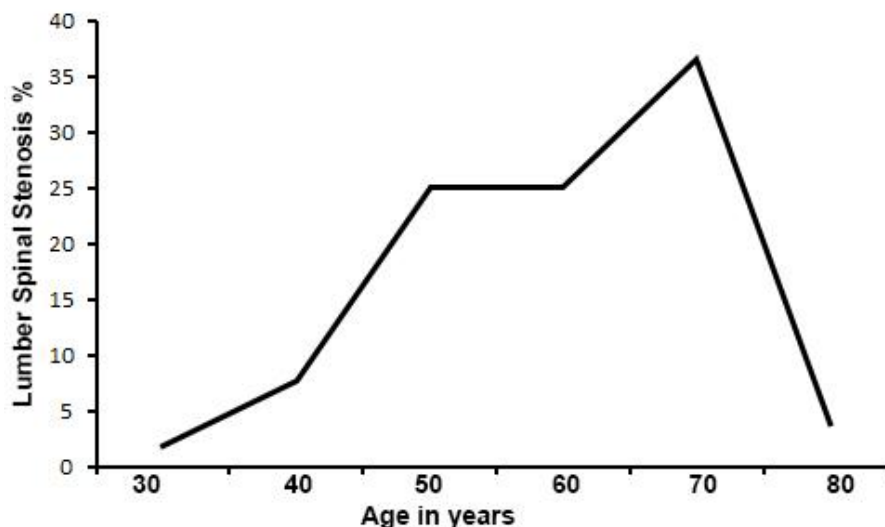


Fig 5 shows: correlations between ages and spinal lumbar stenosis:-

### CONCLUSION

Our results conclude that, the antero posterior diameter of the lumbar spinal canal is the radiological criteria of spinal canal stenosis should be computed from measurements less than the normal one. The lumbar stenosis is more common in females than male and people above 40 years old predispose to lumbar stenosis commonly in the lower three lumbar vertebrae. The congenital stenosis occurs in females.

### REFERENCES

- Vogt MT, Cawthon PM, Kang JD, Donaldson WF, Cauley JA, Nevitt MC. Prevalence of symptoms of cervical and lumbar stenosis among participants in the Osteoporotic Fractures in Men Study. *Spine*. 2006 Jun 1; 31(13):1445-51.
- Hicks GE, Gaines JM, Shardell M, Simonsick EM. Associations of back and leg pain with health status and functional capacity of older adults: findings from the retirement community back pain study. *Arthritis Care & Research*. 2008 Sep 15; 59(9):1306-13.
- Genevay S, Atlas SJ .A radicular syndrome from developmental narrowing of the lumbar vertebral canal. *J Bone Joint Surg* 2010; 36B: 230-37.
- Postacchini F, RIPANI M, CARPANO S. Morphometry of the Lumbar Vertebrae: An Anatomic Study in Two Caucasoid Ethnic Groups. *Clinical orthopaedics and related research*. 1983 Jan 1; 172:296-303.
- Anick Sung Shawie. Lumbar spinal canal stenosis. *JAAOS*; 2010.
- David Tibbutt DM, Low back pain, *SSMJ* vol 3 issue 4; 2008.
- Sachs B, Frankel V, Progressive and kyphotic rigidity of the spine. *J Nerv Ment Dis* 1900;27: 1-15
- Verbiest H. A radicular syndrome from developmental narrowing of the lumbar vertebral canal. *Bone & Joint Journal*. 1954 May 1; 36(2):230-7.
- Porter RW, Hibbert CS, Wicks MA. The spinal canal in symptomatic lumbar disc lesions. *Bone & Joint Journal*. 1978 Nov 1; 60(4):485-7.
- Rothman Rh and Semeone FA, ed, *The Spine*. Philadelphia: Saunders. p. 518. 1982.
- Djurasovic M, Glassman SD, Carreon LY, Dimar JR. Contemporary management of symptomatic lumbar spinal stenosis. *Orthopedic Clinics of North America*. 2010 Apr 30; 41(2):183-91.
- JOHNSON KE, ROSÉAN I, UDÉAN A. The natural course of lumbar spinal stenosis. *Clinical orthopaedics and related research*. 1992 Jun 1; 279:82-6.
- Eisenstein ST. The morphometry and pathological anatomy of the lumbar spine in South African negroes and caucasoids with specific reference to spinal stenosis. *Bone & Joint Journal*. 1977 May 1; 59(2):173-80.
- Amonoo-Kuofi HS. Maximum and minimum lumbar interpedicular distances in normal adult Nigerians. *Journal of anatomy*. 1982 Sep; 135(Pt 2):225.
- Amonoo-Kuofi HS. The sagittal diameter of the lumbar vertebral canal in normal adult Nigerians. *Journal of anatomy*. 1985 Jan; 140(Pt 1):69.
- Lee HM, Kim NH, Kim HJ, Chung IH. Morphometric study of the lumbar spinal canal in the Korean population. *Spine*. 1995 Aug 1; 20(15):1679-84.
- Moore KL [Ed]: *Clinically Oriented Anatomy*, 3rd Ed. Baltimore, Williams & Wilkins, A Waverly Company. 1992, pp 332.

18. Tacarl O, Demirantl A, Nasz K, Altindag O. Morphology of the Lumbar Spinal Canal in Normal Adult. *Yonsei medical journal*. 2003; 44(4):679-85.
19. Piera V, Rodriguez A, Cobos A, Hernandez R, Cobos P. Morphology of the lumbar vertebral canal. *Cells Tissues Organs*. 1988 Jul 1; 131(1):35-40.
20. Sengupta DK, Herkowitz HN. Lumbar spinal stenosis. *Orthopedic Clinics*. 2003 Apr 1; 34(2):281-95.
21. Singh K, Samartzis D, Vaccaro AR, Nassr A, Andersson GB, Yoon ST, Phillips FM, Goldberg EJ, An HS. Congenital lumbar spinal stenosis: a prospective, control-matched, cohort radiographic analysis. *The Spine Journal*. 2005 Dec 31; 5(6):615-22.
22. Scoles PV, Linton AE, Latimer B, Levy ME, Digiovanni BF. Vertebral body and posterior element morphology: the normal spine in middle life. *Spine*. 1988 Oct 1; 13(10):1082-6.
23. Venner RM, Crock HV. Clinical studies of isolated disc resorption in the lumbar spine. *Bone & Joint Journal*. 1981 Nov 1; 63(4):491-4.