

Case Report

Refractory hypokalemia as initial manifestation of Cushing's syndrome complicating pregnancy

Ritu Karoli¹, Jalees Fatima², Manisha Katiyar³, Parul Gupta⁴

^{1,2}Department of Medicine, ^{3,4}Department of Obstetrics and Gynecology, Era's Lucknow Medical College, Sarfarazganj, Hardoi Road, Lucknow UP 226003, India

*Corresponding author

Dr Ritu Karoli

Email: ritu.karoli@rediffmail.com

Abstract: A pregnancy complicated by Cushing's syndrome is a high-risk obstetric condition. The overlap in clinical features with pregnancy, as well as its rare occurrence, makes the diagnosis of Cushing's syndrome difficult and often leads to late detection. Hereby, we are reporting a pregnant patient with Cushing's syndrome who presented with metabolic alkalosis and severe hypokalemia diagnosed to have adrenal adenoma. Adrenalectomy remains to be the definitive cure for Cushing's syndrome secondary to an adrenal adenoma.

Keywords: Adrenalectomy, Cushing's syndrome, pregnancy

INTRODUCTION

Cushing's syndrome is a rare disease occurs in about 2/1,000,000 of general population [1]. During pregnancy it is furthermore rarer clinical entity since high incidence of ovulatory failure due to hypercortisolism and hyperandrogenism associated with Cushing's syndrome suppresses gonadotropin secretion and impair both ovarian and endometrial functions. Cushing's syndrome in pregnancy poses a diagnostic challenge to obstetricians and physicians not only because of its rare occurrence but also due to overlapping clinical features with preeclampsia and gestational diabetes. It is associated with severe maternal and fetal complications, such as spontaneous abortion, perinatal death, prematurity, maternal hypertension, diabetes, fractures and opportunistic infections [2-4]. These patients have high risk pregnancies. Hence, a high degree of clinical suspicion is required for early identification and appropriate management of this condition for better pregnancy outcome.

Hereby, we are reporting a pregnant patient who presented with classical features of Cushing's syndrome along with metabolic alkalosis and severe refractory hypokalemia.

DESCRIPTION OF THE PATIENT

A 30-year old female, gravida 3 para 2 patient with 27 weeks 3 days duration of pregnancy was

admitted in antenatal ward of our institution with chief complains of generalized body swelling and severe breathlessness on exertion for 1 month. She was referred from a primary care centre as a case of gestational diabetes.

She had tachycardia and hypertension pulse rate 112/min, 170/110mmHg. She had 82% oxygen saturation at room air with deranged blood sugar levels (278mg/dl and 248mg/dl) for which medical consultation was immediately sought. Physical examination revealed moon face, extensive purple striae throughout the abdomen, arms (Figure 1) and the inner thighs, bruising over pressure areas, a dorsocervical fat pad, acne and hirsutism. The body mass index (BMI) was 29.5kg/m². Admission biochemistry indicated mild hyponatremia and severe hypokalemia (134 and 1.6 mmol/L, respectively). Arterial blood gas analysis was suggestive of metabolic alkalosis. Her renal and liver profile along with Calcium, Phosphorus and Magnesium levels were all within normal limits. Haematological parameters were also normal except haemoglobin which was 9.6gm/dl.

Her last two pregnancies had been uncomplicated with first delivery carried out vaginally 3yrs back. Baby was a girl, alive and healthy. Her next spontaneous vaginal delivery was preterm intrauterine death 18 months back. There was no history of any chronic illness in her or family.

Hypertension, diabetes, extensive purplish stria and Cushingoid habitus along with severe hypokalemia and metabolic alkalosis pointed towards presence of hypercortisolemia. The biochemical screening was also consistent with Cushing's syndrome. Basal urine free cortisol was 2357micgms/24hrs (normal range: 40-250µg/24h). Urinary catecholamines, metanephrines and normetanephrine along with serum aldosterone were normal. The serum cortisol levels were neither suppressed with overnight dexamethasone suppression test (single dose of 8 mg of dexamethasone) nor with low dose dexamethasone suppression test (0.5mg of dexamethasone per os every 6h for 2 days). The plasma adrenocorticotropin hormone (ACTH) value was 2pmol/L at 08:00 am (normal: 2-11pmol/L).

In our patient, pituitary gland pathology or ectopic cause of Cushing's syndrome was unlikely owing to the low plasma ACTH levels. Bilateral adrenal hyperplasia and adrenal adenoma were considered to be

the most likely cause of her condition. An ultrasound (US) of the adrenal glands was obtained, but on account of her obesity no special findings could be delineated. Adrenal computed tomography (CT) scans could not be obtained at that point of time due to gestation. She was started antihypertensive therapy as methyldopa and Labetalol and later Niphedipine was added. Hypokalemia persisted about a week, requiring intravenous potassium supply up to 180 mEq per day. Blood sugars were managed with regular and intermediate acting insulin's. She delivered preterm at 28 weeks due to severe preeclampsia and fetal distress. The infant expired after 2 hours. Blood pressure was controlled after delivery.

Post-delivery, an abdominal CT scan (Figure 2) disclosed a left adrenal mass (4x3cm), while pituitary magnetic resonance imaging (MRI) scan was normal. She underwent left adrenalectomy and improved.

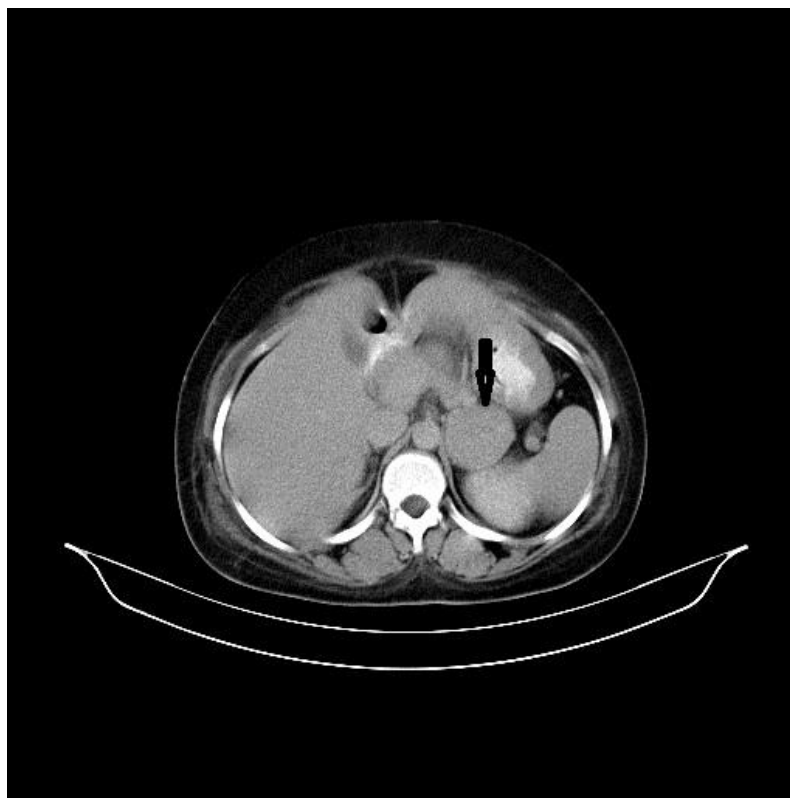


Fig 1: Computed tomography abdomen showing left adrenal mass (arrow)

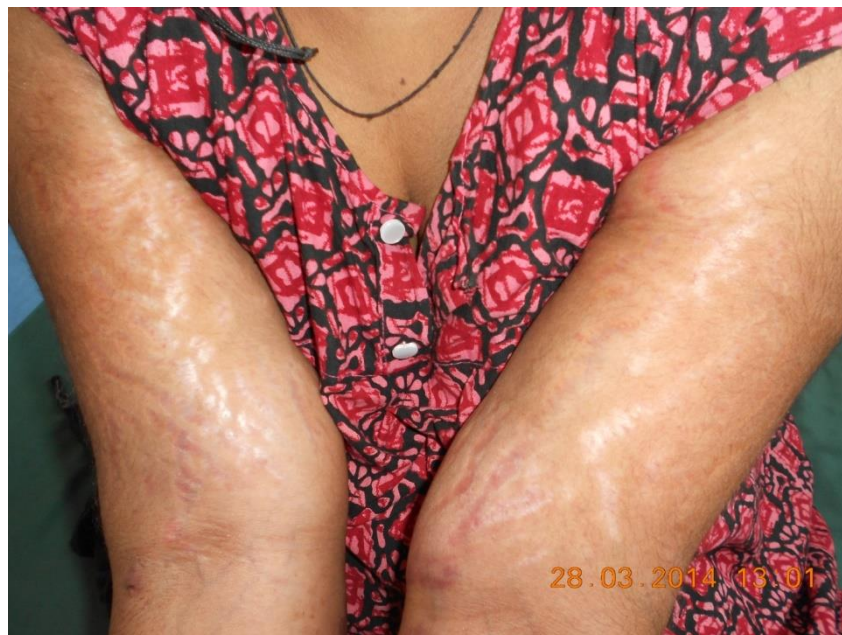

Fig 2: Extensive purplish striae

DISCUSSION

Cushing syndrome is rare in pregnancy because hypercortisolism and hyperandrogenism often induces ovulatory dysfunction leading to menstrual disturbance and infertility. The most common cause of Cushing syndrome during pregnancy is adrenal adenoma, followed by pituitary etiology, and adrenal carcinoma. This may be attributed to the fact that patients with an adrenal adenoma are most likely to be purely Cortisol producing, thus their ovulatory function remains relatively unaffected [5, 6].

Suspicion of presence of Cushing syndrome in pregnancy is difficult for the obstetricians because of the two reasons. Firstly, Cushing syndrome being rare in pregnancy so not commonly thought of, secondly this syndrome can easily be confused with complications of pregnancy such as gestational diabetes and pre-eclampsia, which usually present with the same symptoms as Cushing's syndrome. Normal changes in hypo thalamic pituitary axis take place during pregnancy that because upto three times increase in serum Cortisol, plasma ACTH and UFC levels, which further complicate the use of biochemical screening process for Cushing's syndrome [7]. However, the circadian rhythm of cortisol and ACTH secretion is preserved.

Cushing's syndrome in pregnancy is usually associated with an increased incidence of pregnancy related complications such as abortion, premature labor, intrauterine growth retardation, glucose intolerance, cardiac failure, pulmonary edema, hypertension, and myopathy, pre-eclampsia, poor wound healing and responsible for higher maternal and fetal morbidity [8, 9].

Our patient presented with severe hypokalemia and metabolic alkalosis which are more commonly associated with presence of ectopic Cushing's syndrome a paraneoplastic manifestation of malignancies such as small cell carcinoma lung, carcinoids or medullary carcinoma thyroid. Her low ACTH level, normal cranial MRI and HRCT (high resolution computed tomography) thorax ruled out possibility of ACTH dependent Cushing's syndrome. Our patient had severe hypercortisolism and low normal aldosterone levels. Under normal conditions the mineralocorticoid effect of cortisol is insignificant, the renal enzyme 11- β -hydroxysteroid dehydrogenase provides mineralocorticoid receptor specificity for aldosterone by metabolizing cortisol to their 11-dehydro derivatives (cortisone) compounds that do not bind to the mineralocorticoid receptor. In states of severe hypercortisolism decreased enzyme activity allows glucocorticoids to act as mineralocorticoids and produce hypertension, hypokalemia, and metabolic alkalosis with low levels of aldosterone.

Our patient was also diagnosed to have an adrenal adenoma as CT abdomen did not show any evidence of invasion into surrounding structures and histopathologically tumor was well differentiated with no vascular or capsular invasion. After adrenalectomy, she was clinically improved also.

As far as treatment of Cushing syndrome is concerned, Lindsay *et al.*; [4] suggested that surgical treatment is the mainstay of therapy of Cushing syndrome in pregnancy, with medical treatments (ketocaonazole, metyrapone and aminoglutethimide) constituting the second choice. Even after detection of

Cushing syndrome, its management remains controversial especially in the early third trimester of pregnancy [10]. Due to the rarity of the pathology, however, no generally accepted treatment guidelines are available.

CONCLUSION

A pregnancy complicated by Cushing syndrome is a high-risk obstetric condition. The overlap in clinical features with pregnancy, as well as its rare occurrence, makes the diagnosis of Cushing's syndrome difficult and often leads to late detection. A high index of clinical suspicion for Cushing's syndrome in pregnancy is required for early intervention and prevention of maternal and fetal morbidity and mortality. Adrenalectomy remains to be the definitive cure for Cushing's syndrome secondary to an adrenal adenoma.

REFERENCES:

1. Lo KW, Lau TK. Cushing's syndrome in pregnancy secondary to adrenal adenoma. *Gynecologic and obstetric investigation*. 1998 Apr 3; 45(3):209-12.
2. Kita M, Sakalidou M, Saratzis A, Ioannis S, Avramides A. Cushing's syndrome in pregnancy: report of a case and review of the literature. *HORMONES-ATHENS*. 2007; 6(3):242.
3. Lindsay JR, Jonklaas J, Oldfield EH, Nieman LK. Cushing's syndrome during pregnancy: personal experience and review of the literature. *The Journal of Clinical Endocrinology & Metabolism*. 2005 May 1; 90(5):3077-83.
4. Lindsay JR, Nieman LK. The hypothalamic-pituitary-adrenal axis in pregnancy: challenges in disease detection and treatment. *Endocrine Reviews*. 2005 Oct 1; 26(6):775-99.
5. Lekarev O, New MI. Adrenal disease in pregnancy. *Best Pract Res Clin Endocrinol Metab* 2011; 25:959-73.
6. Chico A, Manzanares JM, Halperin I, de Osaba MJ, Adelantado J, Webb SM. Cushing's disease and pregnancy: report of six cases. *European Journal of Obstetrics & Gynecology and Reproductive Biology*. 1996 Jan 31; 64(1):143-6.
7. Carr BR, Parker CR, Madden JD, MacDonald PC, Porter JC. Maternal plasma adrenocorticotropin and cortisol relationships throughout human pregnancy. *American journal of obstetrics and gynecology*. 1981 Feb 15; 139(4):416-22.
8. Sheeler LR. Cushing's syndrome and pregnancy. *Endocrinol Metab Clin North Am*, 1994 ;23: 619 627.
9. Guillaume B, Sanson ML, Billaud L, Bertagna X, Laudat MH, Luton JP. Cushing's syndrome and pregnancy: aetiologies and prognosis in twenty-two patients. *The European journal of medicine*. 1992 May; 1(2):83-9.
10. Shaw JA, Pearson DW, Krukowski ZH, Fisher PM, Bevan JS. Cushing's syndrome during pregnancy: curative adrenalectomy at 31 weeks gestation. *European Journal of Obstetrics & Gynecology and Reproductive Biology*. 2002 Nov 15; 105(2):189-91.