

Case Report

Cutaneous Bronchogenic Cyst- A Rare Presentation

Gupta Meenu¹, Chattopadhyay Prasenjit², Roy Chowdhury Anadi³, Singha Roy Debojyoti⁴.

Department of pathology¹, Department of Plastic surgery², R.G. Kar Medical College and Hospital, Kolkata

*Corresponding author

Gupta Meenu

Email: drmeenu43@gmail.com

Abstract: Cutaneous bronchogenic cysts are congenital cyst, developing from the primitive foregut. They are more common on suprasternal area, but are found on various locations like scapular, neck and even forming sinus on the abdominal wall. They are more common in males than females. Here we report an adult patient having a long standing history of suprasternal cutaneous bronchogenic cyst, which ruptured spontaneously, treated by simple excision.

Keywords: Bronchogenic cyst, adult, Congenital cyst

INTRODUCTION

Bronchogenic cyst is rare congenital anomalies that usually occur in chest or mediastinum but occasionally in the skin. On the skin they are close to the suprasternal notch or over the manubrium sterni (upper part of sternum) [1].

They are developmental anomaly of the tracheobronchial tree in the 6th week of gestation [1, 2]. Clinically it is often misdiagnosed and proper diagnosis can only be made after histopathological examination. It

is important to distinguish it from various cutaneous cysts occurring in neck. In this report we describe a case of ruptured cutaneous bronchogenic cyst in a 32-year-old male.

CASE REPORT

A 32-year-old male with a long standing history of painless swelling over the upper part of sternum, presented with an increase in size and intermittent discharge from the swelling.

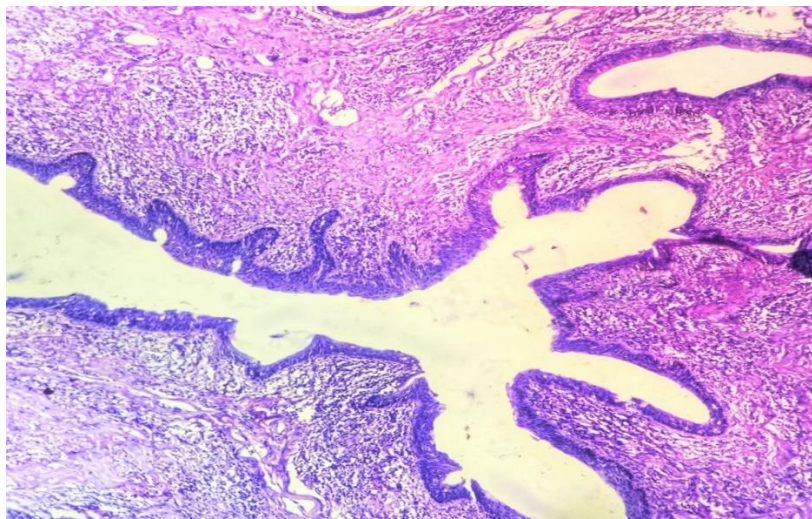


Fig 1: The cyst was lined by ciliated pseudostratified columnar epithelium (H&E staining, 200 X)

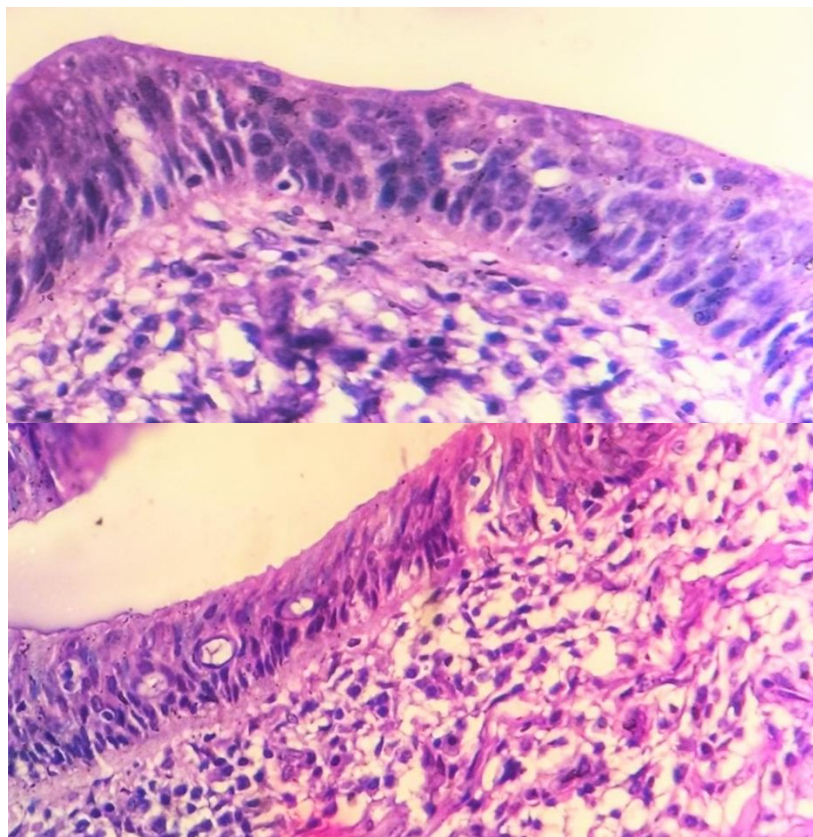


Fig 2 & 3: Pseudostratified ciliated epithelium. (H & E staining; 400 X)

A physical examination revealed an ulcerated area over the swelling without active discharge. No other swelling could be found. Total surgical excision of the skin lesion was performed under local anesthesia. On gross examination it was a single partially skin covered tissue piece measuring (3.5 *3 *1.5) cm, an ulcerated area was noted in the center of the tissue. Histologically shows irregular dilated glands lined by respiratory epithelium with surrounding mesenchymal elements and areas of chronic inflammatory cells. (Fig 1, Fig 2, Fig 3)

DISCUSSION

A total of 86 cutaneous or subcutaneous bronchogenic cysts have been reported [4]. A bronchogenic cyst is a congenital anomaly of the embryogenic foregut. At the 6th week of gestation, the foregut divides into dorsal esophagus and ventral trachea [5]. The ventral trachea then divides into tracheobronchial tree. Bronchogenic cysts in the subcutaneous tissue of the anterior chest wall occur either by anterior migration of an intrathoracic bronchogenic cyst or by a pinching off of the fusing sternal bars on the developing lung parenchyma [7].

They are asymptomatic, and some of them have a fistulous opening that drains mucoid material [7]. More commonly located over the suprasternal notch or manubrium sterni. Other areas have also been reported like scapular area, shoulder, and chin and back [8]. The lesions are most commonly seen in the pediatric population and rarely present in adults. Males are four times more affected than females [4, 6].

Histologically the lining epithelium is pseudostratified ciliated cuboidal to columnar cell. It may also form folds or papillary projections into the lumen. Goblet cells are usually present and the stroma includes smooth muscle, mucous glands or cartilage. Sometimes a mixed inflammatory infiltrate is also present [1, 2, 9].

The differential diagnosis of congenital cervical cysts in children include branchial cleft cysts, bronchogenic cysts, epidermal inclusion cysts, thymic cysts, thyroid cysts, cystic teratomas, thyroglossal duct cysts, and cystic hygromas [9, 10]. If only ciliated cysts are considered, the differential narrows to branchial cyst, bronchogenic cyst, thyroglossal duct cyst, thymic cyst. Thyroglossal duct cyst is confirmed histologically

by presence of thyroid follicles [11]. Thymic cyst is believed to arise from embryonic remnants of thymopharyngeal duct and may present in neck. They microscopically resemble bronchogenic cyst but lack goblet cells and contain thymic tissue. When compared to branchial cyst it is difficult to distinguish but branchial cleft cysts typically have a lining of squamous epithelium, although ciliated columnar cells may be present. Lymphoid follicles are also seen [12]. The treatment of cutaneous bronchogenic cysts is resection, which provides relief of symptoms and prevents future infection. Recurrence after complete excision is unusual [12].

REFERENCES:

1. Patterson JW. Practical Skin Pathology: A Diagnostic Approach: A Volume in the Pattern Recognition Series. Elsevier Health Sciences; 2013 May 7.
2. Leon Barnes et al. Surgical pathology of head and neck. Pg no 1503.
3. James W Paterson et al. Weedon's Skin Pathology. Pg no 521.
4. Shah SK, Stayer SE, Hicks MJ, Brandt ML. Suprasternal bronchogenic cyst. Journal of pediatric surgery. 2008 Nov 30; 43(11):2115-7.
5. Rodgers BM, Harman PK, Johnson AM. Bronchopulmonary foregut malformations. The spectrum of anomalies. Annals of surgery. 1986 May; 203(5):517.
6. Ustundag E, Iseri M, Keskin G, Yayla B, Muezzinoglu B. Cervical bronchogenic cysts in head and neck region: review of the literature. Journal of Laryngology & Otology. 2005 Jun 1; 119(06):419-23.
7. Park HS, Son HJ, Kang MJ. Cutaneous bronchogenic cyst over the sternum. Korean Journal of Pathology. 2004; 38:333-6.
8. Bagwell CE, Schiffman RJ. Subcutaneous bronchogenic cysts. Journal of pediatric surgery. 1988 Nov 30; 23(11):993-5.
9. Fraga S, Helwig EB, Rosen SH. Bronchogenic cysts in the skin and subcutaneous tissue. American journal of clinical pathology. 1971 Aug 1; 56(2):230-8.
10. Pujary K, Pujary P, Shetty R, Hazarika P, Rao L. Congenital cervical bronchogenic cyst. International journal of pediatric otorhinolaryngology. 2001 Feb 28; 57(2):145-8.
11. Coleman WR, Homer RS, Kaplan RP. Branchial cleft heterotopia of the lower neck. Journal of cutaneous pathology. 1989 Dec 1; 16(6):353-8.
12. Coleman WR, Homer RS, Kaplan RP. Branchial cleft heterotopia of the lower neck. Journal of cutaneous pathology. 1989 Dec 1; 16(6):353-8.
13. Dong Ha Kim, Hyun Kyu Kim, et al. A Case of Cutaneous Bronchogenic Cyst Presenting with Lymphoid Follicles. Ann Dermatol 2011 Aug; 23(3): 392–395.
14. Sun J, Yuan T, Deng H. Cutaneous bronchogenic cyst in the left scapular region of a boy. World J Pediatr. 2014 Nov 15; 10(4):365-7.
15. Kim PS, Cataletto M, Garnet DJ, Alexeeva V, Selbs E, Katz DS, Coren CV. Unusual presentation of a cutaneous bronchogenic cyst in an asymptomatic neonate. Journal of pediatric surgery. 2012 Jul 31; 47(7):e9-12.
16. Kim NR, Kim HH, Suh YL. Cutaneous bronchogenic cyst of the abdominal wall. Pathology international. 2001 Dec 1; 51(12):970-3.