

## Successful Reproductive Outcome Following Challenging Surgical Management of Mullerian Anomalies

Dr. Jesmine Banu<sup>1\*</sup>, Dr. Nighat Sultana<sup>2</sup>, Dr. Mostafa Tarique<sup>3</sup>, Dr. Nastaran Laskar<sup>3</sup>, Dr. Chowdhury Faisal Alamgir<sup>4</sup>, Dr. Maliha Darmini<sup>5</sup>, Dr. Surya Jahan Rolly<sup>6</sup>

<sup>1</sup>Professor & Chairman, Department of Reproductive Endocrinology and Infertility, Bangabandhu Sheikh Mujib Medical University, Dhaka, Bangladesh

<sup>2</sup>Consultant, Department of Obstetrics and Gynaecology, Bangabandhu Sheikh Mujib Medical University, Dhaka, Bangladesh

<sup>3</sup>Medical Resident, Department of Reproductive Endocrinology and Infertility, Bangabandhu Sheikh Mujib Medical University, Dhaka, Bangladesh

<sup>4</sup>Clinical Assistant, Department of Urology, New Cross Hospital, The Royal Wolverhampton NHS Trust, United Kingdom

<sup>5</sup>Clinical Assistant, Department of Gynecology, New Cross Hospital, The Royal Wolverhampton NHS Trust, United Kingdom

<sup>6</sup>Medical Officer, Department of Reproductive Endocrinology and Infertility, Bangabandhu Sheikh Mujib Medical University, Dhaka, Bangladesh

DOI: [10.36347/sjams.2023.v1i102.002](https://doi.org/10.36347/sjams.2023.v1i102.002)

| Received: 26.12.2022 | Accepted: 30.01.2023 | Published: 02.02.2023

\*Corresponding author: Dr. Jesmine Banu

Professor & Chairman, Department of Reproductive Endocrinology and Infertility, Bangabandhu Sheikh Mujib Medical University, Dhaka, Bangladesh

### Abstract

### Original Research Article

**Background:** Mullerian duct anomalies consist of a set of structural malformations of reproductive organ resulting from abnormal development of the paramesonephric or Müllerian ducts. The prevalence of these anomalies ranges from 0.001 to 10% in the general population and from 8-10% in women with an adverse reproductive history. The aim of this study was to diagnose different type of mullerian anomalies and to evaluate the reproductive outcome that occurs as a result of surgical management of malformation of genital tract. **Methods:** A prospective observational study of mullarian anomalies and its diagnosis & reproductive outcome was observed by using data from women with congenital anomalies attended in OPD either with complains or incidental diagnosis with HSG, during laparoscopy at tertiary care center. Total 100 women with different types of mullarian anomalies were included in study. **Results:** Most common utero-vaginal anomaly seen in present study was septate uterus with on basis of clinical examination. Out of 100 patient (35)35% were diagnosed mullerian agenesis. Cervico vaginal agenesis (15)15%, Septate uterus 28(28%), Bicornuate uterus 7(7%), Transverse vaginal septum 5 %, unicornuate 5%, Didelphi's with longitudinal vaginal septum 2%, Microperforate Hymen 3(3%). Among all patients 26 patients were pregnant. Among primary amenorrhea 35 patient of mullerian agenesis after progressive non-surgical vaginal dilatation 22 patient had no coital difficulty. 5 patients were need vaginoplasty. Among 15 patients of cervicovaginal agenesis 6 become menstruating, 2 were pregnant, 6 patient failed anastomosis, needed total abdominal hysterectomy 3 patients on oral pill. Among 5 transverse vaginal septum, 5 having regular menstration among 2 become pregnant. Among other mullarian anomalies after challenging surgical management 22 patient become pregnant. **Conclusion:** Present study shows prevalence of congenital malformation of female reproductive tract is 0.83% at our tertiary care center. Utero-vaginal anomalies are a morphologically diverse group of developmental disorders. Establishing an accurate diagnosis is essential for planning treatment and management strategies. The surgical approach for correction of utero-vaginal anomalies is specific to the type of malformation and may vary in a specific group but classified mullarian anomalies after challenging surgical management had a good reproductive outcome in this study.

**Keywords:** Mullerian Anomalies, Reproductive outcome, Amenorrhoea.

Copyright © 2023 The Author(s): This is an open-access article distributed under the terms of the Creative Commons Attribution 4.0 International License (CC BY-NC 4.0) which permits unrestricted use, distribution, and reproduction in any medium for non-commercial use provided the original author and source are credited.

## INTRODUCTION

Mullerian duct anomalies consist of a set of structural malformations of reproductive organ resulting from abnormal development of the

paramesonephric or Müllerian ducts. The prevalence of these anomalies ranges from 0.001 to 10% in the general population and from 8-10% in women with an adverse reproductive history [1, 2]. The embryological development of the female reproductive system is

**Citation:** Jesmine Banu, Nighat Sultana, Mostafa Tarique, Nastaran Laskar, Chowdhury Faisal Alamgir, Maliha Darmini, Surya Jahan Rolly. Successful Reproductive Outcome Following Challenging Surgical Management of Mullerian Anomalies. Sch J App Med Sci, 2023 Feb 11(2): 269-274.

closely related to the development of the urinary system, and anomalies in both systems may occur in up to 25% of these patients [3]. Other associated malformations may affect the gas-trointestinal tract (12%) or musculoskeletal system (10-12%) [3]. The karyotypes are normal (46 XX) in 92% of the women with Müllerian anomalies and abnormal (sex chromosome mosaicism) in 8% of these women. The majority of these developmental abnormalities is infrequent and sporadic, and is thus attributed to polygenic and multifactorial causes [4]. A recent study attributed persistence of the in-uterine septum to a deficiency in the antiapoptotic protein Bcl [2], which is responsible for the process of apoptosis and absorption of the septum [5]. Diagnosis was based on imaging studies that had low diagnostic accuracy. It was focused mainly on the anomalies of the uterus. Less is known about the anomalies of the cervix or the vagina in isolation or in combination with the utero- cervical and vaginal malformations. Improved diagnostic modalities and incorporation of surgical expertise and assisted reproductive technology have improved the outcome further. Successful development of the Müllerian system is essential for normal menstrual function, sexual function and finally the reproductive function [7, 8]. A wide range of malformations have been observed affecting the genital organs either in isolation or in combination with other organs. Interestingly in the present days, major changes have been observed in all the areas of management of Müllerian abnormalities. The ESHRE–ESGE consensus on the classification of female genital tract congenital anomalies [9, 10].

Developmental anomalies of the Müllerian duct system represent an interesting field of disorders in obstetrics and gynaecology as they can affect any of the reproductive organs from Fallopian tubes to the hymen. Aberration in the development of Müllerian ducts result in abnormalities of internal reproductive structures as well as ambiguity of the external genitalia. Early establishment of accurate diagnosis is important for planning management and complications in genital organs. The surgical option for correction of Müllerian duct anomalies is individualized on the type of malformation. The value of a given surgical procedure should be assessed in term of Healthy sexual relation and achieve successful reproductive outcomes. Development of the female genital tract is a complex process dependent upon a series of events involving Cellular differentiation, Migration, Fusion and Canalization. Failure of any one of these processes results in different types of anomalies of the vagina and uterus. Two paired Müllerian ducts ultimately develop into: fallopian tubes, uterus, cervix, and the upper two thirds of the vagina [3] phases of development as follows: **Organogenesis:** One or both Müllerian ducts may not develop fully, resulting in: uterine agenesis or hypoplasia (bilateral) or unicornuate uterus (unilateral). a. **Fusion:** Lateral fusion of the lower segments of the paired Müllerian ducts form the uterus, cervix, and

upper vagina. Failure of fusion results in bicornuate or didelphys uterus. b. **Vertical fusion:** fusion of the ascending sinovaginal bulb with the descending Müllerian system forms a normal patent vagina incomplete vertical fusion results in an imperforate hymen c. **Septal resorption:** After the lower Müllerian ducts fuse, a central septum is present, which subsequently must be resorbed to form a single uterine cavity and cervix. Failure of resorption is the cause of septate uterus. Although teratogenic exposures such as thalidomide, diethylstilbestrol (DES), and radiation have been linked with these abnormalities, the vast majority are likely related to polygenetic and familial factors.

Müllerian ductal anomalies are associated with functioning ovaries and age appropriate external genitalia. They are present in 1-10% of unselected population, 2-8% of infertile women, and 5-30% recurrent pregnancy loss. Incidence of MD According to AFS Unicornuate 10% and Uterine didelphys-8%, Bicornuate uterus 26%, Septate uterus 36%, Arcuate Uterus 18%. Because of the wide variations in clinical presentations, Müllerian duct anomalies may be difficult to diagnose. But various investigations like HSG, TVS, 3-D USG, laparo-hysteroscopy, and MRI helps to diagnose more cases nowadays [11]. After an accurate diagnosis is rendered, many treatment options exist, and they are usually tailored to the specific utero-vaginal anomaly.

The aim of this study was to diagnose different type of Müllerian anomalies and to evaluate the reproductive outcome following surgical management of malformation of genital tract.

## METHODS

This prospective observational study was conducted at Bangabandhu Sheikh Mujib Medical University (BSMMU), Dhaka during the period of July 2017 to June 2022. Patient having congenital abnormalities of female genital tract attending in the OPD of Reproductive Endocrinology and infertility department at BSMMU are the study population. Total 100 women of gynecological cases with different types of congenital anomalies enrolled in this study from clinical history, examination and relevant investigations and disorder of sexual development cases were excluded from the study. Women with congenital anomalies attended our department either with complains like primary amenorrhea, cyclical abdominal pain, dyspareunia, infertility, recurrent abortion and women with incidental diagnosis during ultrasound, HSG during laparoscopy were included.

### Statistical Analysis

All data were recorded systematically in preformed data collection form and qualitative data was expressed as frequency distribution and percentage.

Statistical analysis was performed by using SPSS 23 (Statistical Package for Social Sciences) for windows

version 10. Probability value <0.05 was considered as level of significance.

## RESULTS

**Table 1: Various modalities of diagnosis**

	No. of patients	P (%)
Hysterosalpingograpy	39	39%
Ultrasonography	90	90%
MRI	50	50%
Hysteroscopy and laparoscopy	85	85%

All women underwent clinical examination and relevant investigations USG, MRI, were done in every patient to assess the uterus, any other pelvic pathology and to exclude the renal abnormalities. Some

cases needed HSG. Then Patients under went different investigations like USG n=90, HSG (n=39), Hysteroscopy and laparoscopy (n=85), MRI (n=50) according to need as diagnostic modalities.

**Table 2: Different anomalies of female genital tract**

Type of anomaly	N	P (%)
Mullarian agenesis	35	35%
Unicornuate uterus	5	5%
Septate uterus	28	28%
Transverse vaginal septum	5	5%
Cervical agenesis	15	15%
Bicornuate uterus	7	7%
Didelphys uterus with Longitudinal septum	2	2%
Micro perforate hymen	3	3%

Most common utero-vaginal anomaly seen in present study was septate uterus with on basis of clinical examination and confirms with TVS out of 100 patients (35)35% were diagnosed mullerian agenesis. Cervico vaginal agenesis (15)15%, Septate uterus 28(28%), Bicornuate uterus 7(7%), Transverse vaginal septum 5%, unicornuate 5%, Didelphi's with

longitudinal vaginal septum 2%, Microperforate Hymen 3(3%) and then surgical management followed by pregnancy outcome were observed and their outcomes were studied. Among 100 patients of mullerian anomalies 55 patients presented with primary amenorrhea.

**Table 3: Reproductive outcome of non-surgical vaginal dilatation and surgical reconstruction of mullerian anomalies**

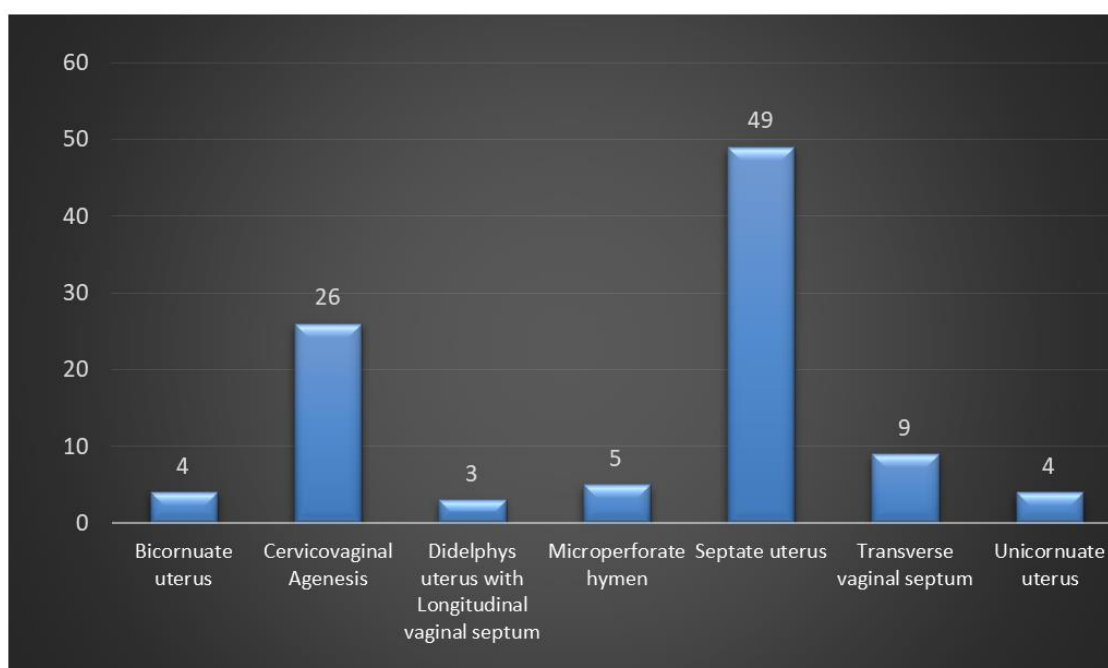
	Surgery Procedure	Reproductive outcome
Mullarian agenesis (n=35)	Progressive non-surgical vaginal dilatation	22(62.9%) patients had no coital difficulty
		5(14.3%)patients need vaginoplasty
		4 (11.4%) were divorced
		4 (11.4%) patients did not continue treatment
Cervicovaginal Agenesis / Dysgenesis (n= 15)	Cervico vaginal anastomosis (with sillican cathter.)	6(40%) become menstrating
		6(40%) failed anastomosis
		3(20%) needed abdominal hysterectomy
		2(13.3%) become pregnant
Transverse vaginal septum (n=5)	Excision of Transverse vaginal septum	3(20%) patients on oral pill
		5(100%) patients having regular menstruation
Unicornuate uterus (n=5)	Surgical excision was done	2(40%) patients become pregnant
		2(40%) with non-communicating functioning horn.
Septate uterus (n=28)	Hysteroscopic septoplasty	1(20%) become pregnant
		15(53.6%) patients become pregnant
		5(17.9%) patients did abortion
Bicornuate uterus (n=7)	Abdominal metroplasty	8(28.6%) patients were not pregnant
		2(28.6%) patients become pregnant
Didelphys uterus with Longitudinal vaginal septum (n=2)	Excision of Longitudinal vaginal septum	2(100%) patients become pregnant
Microperforate hymen (n=3)	Excision of Microperforate hymen	2(66.67%)patients become pregnant

In table 3 we found 35 patients of mullarian agenesis after progressive non-surgical vaginal dilatation. Among all patients 22 patients had no coital difficulty. 5 patients were need vaginoplasty. 4 patients were divorced and 4 patients did not continue treatment.

15 cervicovaginal agenesis and after surgical correction 6 patients become menstruating, 6 patients failed anastomosis, needed total abdominal hysterectomy, 3 patients on oral pill.

Among 5 transverse vaginal septum, 5 having regular menstration among 2 become pregnant. Among other mullarian anamolies after challenging surgical management 24 patients become pregnant.

Out of 28 cases of septate uterus 3 cases were presented with history of recurrent pregnancy Loss and 3 with unexplained infertility remaining 22 were presented with primary or secondary infertility, which were surgically corrected. Among them 15 patients during flow up period after septoplasty were pregnant and continue up to term and 5 were aborted. 8 not become pregnant. In early adolescent age group, the most common anomalies were Transverse vaginal septum and imperforate hymen in the present study. Only 1 5 case of cervico vaginal dysgenesis was found. In present study, 5 patients of unicornuate uterus among them 2 with non-communicating functioning horn presented with dysmerrhoea surgical excision was done. Dysmerrhoea was corrected.



**Figure 1: Surgical correction of mullerian anomalies among patients**

We found majority (49%) of our patients had done septate uterus. We also found cervicovaginal agenesis 26%, transverse vaginal septum 9%.

**Table 4: Total pregnancy outcome among patients**

	No. of surgically corrected patients	No. of pregnancy	Percentage
<i>Cervicovaginal Agenesis</i>	15	2	45.61%
<i>Transverse vaginal septum</i>	5	2	
<i>Septate uterus</i>	28	15	
<i>Unicornuate uterus</i>	2	2	
<i>Bicornuate uterus</i>	2	2	
<i>Didelphys uterus with Longitudinal vaginal septum</i>	3	2	
<i>Microperforate hymen</i>	2	1	
<b>Total</b>	<b>57</b>	<b>26</b>	

In table 4 we showed the pregnancy outcome of patients. Among all patients 45.61% became

pregnant after surgery. Majority of patients became pregnant after septate uterus surgery.

**Table 5: Results summary of our patients with congenital anomalies(N=57)**

Results summary	N	P (%)
<i>Pregnant</i>	26	45.6%
<i>Menstruating</i>	55	96.5%
<i>Relief of pain</i>	55	96.5%

Table 5 summarized the results of our patients. We found 45.6% pregnant women, 96.5% women menstruating and 96.5% patients relieved from pain.

**Table 6: Treatment summary of congenital anomalies of genital tract (N=100)**

Treatment summary	N	P (%)
<i>Surgical treatment required</i>	62	62%
<i>Non-surgical treatment required</i>	30	30%
<i>Treatment refused</i>	8	8%

Here, table 6 summarized the treatment among our patients with congenital anomalies of genital tract. We found 62% patients required surgical treatment, 30% required non-surgical treatment and 8% refused to do treatment.

## DISCUSSION

In present study, most common age group for congenital anomalies is between 16-35 years, while the most common age group for congenital anomalies of comparable to study done by Meiling Hua *et al.*, who reported mean maternal age of patients around 29 years [12]. Primary amenorrhea, abdominal pain and hematocolpos are most common presenting symptoms seen in patient with transverse vaginal septum and cervicovaginal dysgenes, non communicating functioning horn of unicornuate uterus which was also observed by Ben Temime R *et al.*, [12, 13]. Mullerian duct anomalies can be diagnosed by clinical examination, by using HSG, 2D-USG, 3D USG, MRI and hystero-laparoscopy. Bermejo *et al.*, reported 3D ultrasound as a useful complementary tool than 2D ultrasound in the diagnosis of uterine malformations. In doubtful cases, MRI should be performed, particularly for the assessment of the cervix and vagina [14]. At present combined use of laparoscopy and hysteroscopy is the gold standard for diagnosis of septate uterus. Minto *et al.*, has also reported ultrasound as the initial investigation for all patients with simple Mullerian anomalies.

The commonest anomaly seen in present study among primary amenorrhea, mullarian agenesis is 35 % followed by cervicovaginal anomaly 15% in reproductive age group, transverse vaginal septum are 5%. Grimbizis Gf *et al.*, also reported septate uterus (35%) as the most common utero-vaginal anomaly followed by bicornuate uterus (25%). In this study. Septate uterus 28(28%), Bicornuate uterus 7(7%), Transverse vaginal septum 5%, unicornuate 5%, Didelphi's with longitudinal vaginal septum 2%, Microperforate Hymen 3(3%) prevalence of septate uterus more or less same.

In present study 62% cases required surgical correction with excellent reproductive outcome and 26(45.6%) patients were pregnant after surgical correction which was comparable to study conducted by others [17]. Restoration of normal uterine architecture and preservation of fertility are the goals of surgical treatment. However normal or near normal architecture cannot be always achieved.

## CONCLUSION

Utero-vaginal anomalies are morphologically diverse group of developmental disorders that involve the internal female reproductive tract. Establishing an accurate diagnosis is essential for planning treatment and management strategies. The surgical approach for correction of utero vaginal anomalies is specific to the type of malformation and may vary in a specific group. For most surgical procedures, the critical test of the procedure's value is the patient's postoperative ability to have healthy sexual relation and achieve successful reproductive outcomes. In present study 62% cases required surgical correction with excellent reproductive outcome and 26(45.06%) patients achieved pregnancy after surgical correction.

## REFERENCES

1. Strissel, P. L., Oppelt, P., Cupisti, S., Stiegler, E., Beckmann, M. W., & Strick, R. (2009). Assessment of pituitary and steroid hormones and members of the TGF- $\beta$  superfamily for ovarian function in patients with congenital uterus and vaginal aplasia (MRKH Syndrome). *Hormone and metabolic research*, 41(05), 408-413.
2. Amesse, L. S., & Pfaff-Amesse, T. (2007). Congenital anomalies of reproductive tract. In: Falcone T, Hurd WW, eds. *Clinical Reproductive Medicine and Surgery*. 1st ed. Mosby: New York, NY; 171-190.
3. Moore, K. L., Persaud, T. V., & Torchia, M. G. (2016). Before we are born: essentials of embryology and birth defects. *Elsevier Health Sci*.
4. Ashton, D., Amin, H. K., Richart, R. M., & Neuwirth, R. S. (1988). The incidence of

- asymptomatic uterine anomalies in women undergoing transcervical tubal sterilization. *Obstetrics & Gynecology*, 72(1), 28-30.
5. Jurkovic, D., Gruboeck, K., Tailor, A., & Nicolaides, K. H. (1997). Ultrasound screening for congenital uterine anomalies. *BJOG: An International Journal of Obstetrics & Gynaecology*, 104(11), 1320-1321.
  6. Raga, F., Bauset, C., Remohi, J., Bonilla-Musoles, F., Simón, C., & Pellicer, A. (1997). Reproductive impact of congenital Müllerian anomalies. *Human Reproduction (Oxford, England)*, 12(10), 2277-2281.
  7. Simón, C., Martínez, L., Pardo, F., Tortajada, M., & Pellicer, A. (1991). Müllerian defects in women with normal reproductive outcome. *Fertility and sterility*, 56(6), 1192-1193.
  8. Acién, P. (1993). Reproductive performance of women with uterine malformations. *Human Reproduction*, 8(1), 122-126.
  9. Godinjak, Z., & Idrizbegović, E. (2008). Should diagnostic hysteroscopy be a routine procedure during diagnostic laparoscopy in infertile women?. *Bosnian Journal of Basic Medical Sciences*, 8(1), 44.
  10. Ghi, T., Casadio, P., Kuleva, M., Perrone, A. M., Savelli, L., Giunchi, S., ... & Pelusi, G. (2009). Accuracy of three-dimensional ultrasound in diagnosis and classification of congenital uterine anomalies. *Fertility and Sterility*, 92(2), 808-813.
  11. Troiano, R. N., & McCarthy, S. M. (2004). Mullerian duct anomalies: imaging and clinical issues. *Radiology*, 233(1), 19-34.
  12. Hua, M., Odibo, A. O., Longman, R. E., Macones, G. A., Roehl, K. A., & Cahill, A. G. (2011). Congenital uterine anomalies and adverse pregnancy outcomes. *American journal of obstetrics and gynecology*, 205(6), 558-e1.
  13. Temime, R. B., Najar, I., Chachia, A., Attia, L., Makhlouf, T., & Koubaa, A. (2010). Hymenal imperforation: About 13 cases. *Med Tunisia*, 88(3), 168-71.
  14. Bermejo, C., Martínez Ten, P., Cantarero, R., Diaz, D., Pérez Pedregosa, J., Barrón, E., ... & Ruiz López, L. (2010). Three-dimensional ultrasound in the diagnosis of Müllerian duct anomalies and concordance with magnetic resonance imaging. *Ultrasound in Obstetrics and Gynecology*, 35(5), 593-601.
  15. Vyas, R. C., Moghariya, A. M., Shah, S. R., Parikh, P. M., & Shelat, P. M. (2019). Mullerian ductal anomalies and its outcome. *International Journal of Reproduction, Contraception, Obstetrics and Gynecology*, 8(2), 440-445.
  16. Zhang, Y., Zhao, Y. Y., & Qiao, J. (2010). Obstetric outcome of women with uterine anomalies in China. *Chinese Medical Journal*, 123(04), 418-422.
  17. Grimbizis, G. F., Gordts, S., Di Spiezio Sardo, A., Brucker, S., De Angelis, C., Gergolet, M., ... & Campo, R. (2013). The ESHRE/ESGE consensus on the classification of female genital tract congenital anomalies. *Human reproduction*, 28(8), 2032-2044.