

## Thoraco-Abdominal Split by a Metallic Rod: A Case Report

Souleymane Sidibé<sup>1\*</sup>, Issa B Maiga<sup>2</sup>, Lassina Woni<sup>2</sup>, Soungalo Diop<sup>2</sup>, Aboul Azziz Maiga<sup>2</sup>, Allaye Ombotimbé<sup>2</sup>, Fatoumata Konate F<sup>2</sup>, Moussa Wogbo<sup>2</sup>, Djoré D. Gapily<sup>2</sup>, Ahmadou Drame<sup>3</sup>, Kassim Diarra<sup>3</sup>, Seydou Mariko<sup>4</sup>, Seydou Togo<sup>2</sup>, Moussa A Ouattara<sup>2</sup>, Sadio Yena<sup>2</sup>

<sup>1</sup>Department of Pediatric Surgery, Mali Hospital, Bamako, Mali

<sup>2</sup>Thoracic Surgery Department, Mali Hospital, Bamako, Mali

<sup>3</sup>Department of Resuscitation-Anesthesia and Operating Room, Mali Hospital, Bamako, Mali

<sup>4</sup>Department of Gynecology, Mali Hospital, Bamako, Mali

DOI: [10.36347/sasjs.2023.v09i02.004](https://doi.org/10.36347/sasjs.2023.v09i02.004)

| Received: 29.12.2022 | Accepted: 03.02.2023 | Published: 10.02.2023

\*Corresponding author: Souleymane Sidibé

Department of Pediatric Surgery, Mali Hospital, Bamako, Mali

### Abstract

### Case Report

**Introduction:** Impalement wounds are defined by foreign objects usually steel bars or a wooden object, piercing a body cavity in part or from one end to another and always remaining in place. Thoraco-abdominal impalements are cases of rare trauma in our exercise context. We report a case of thoraco-abdominal impalement in an 11-year-old patient as well as our therapeutic attitude in our exercise context. **Observation:** this is an 11-year-old student, with no medical and surgical history, received in emergency for thoraco-abdominal trauma following a play activity in the family home. **Discussion:** Penetrating thoraco-abdominal wounds are most often caused by gunshot wounds. Impalement is a potentially serious lesion that can be immediately life-threatening and depends on the organs affected. Our case study concerns a patient victim of a domestic accident following a playful activity within the family home. The injuring agent was a concrete rod positioned within the home without any security measures and which was used to tie up sheep intended for domestic breeding. Management of impalements must comply with rules so as not to aggravate the lesions. **Conclusion:** Thoracoabdominal impalement injuries are potentially serious and can be life-threatening. Its management is a challenge in countries with limited resources like ours. Good coordination of medico-surgical care allowed optimal management of the patient.

**Keywords:** Thoracoabdominal trauma, impalement, surgery.

Copyright © 2023 The Author(s): This is an open-access article distributed under the terms of the Creative Commons Attribution 4.0 International License (CC BY-NC 4.0) which permits unrestricted use, distribution, and reproduction in any medium for non-commercial use provided the original author and source are credited.

## INTRODUCTION

Impalement wounds are defined by foreign objects usually steel bars or a wooden object, piercing a body cavity in part or from one end to another and always remaining in place. These are serious lesions and are most often fatal due to the location of the large vessels and the heart [5]. They pose specific management problems and surgical exploration is systematic for all patients [4]. Thoraco-abdominal impalements are cases of rare trauma in our exercise context. We report a case of thoraco-abdominal impalement in an 11-year-old patient as well as our therapeutic attitude in our exercise context.

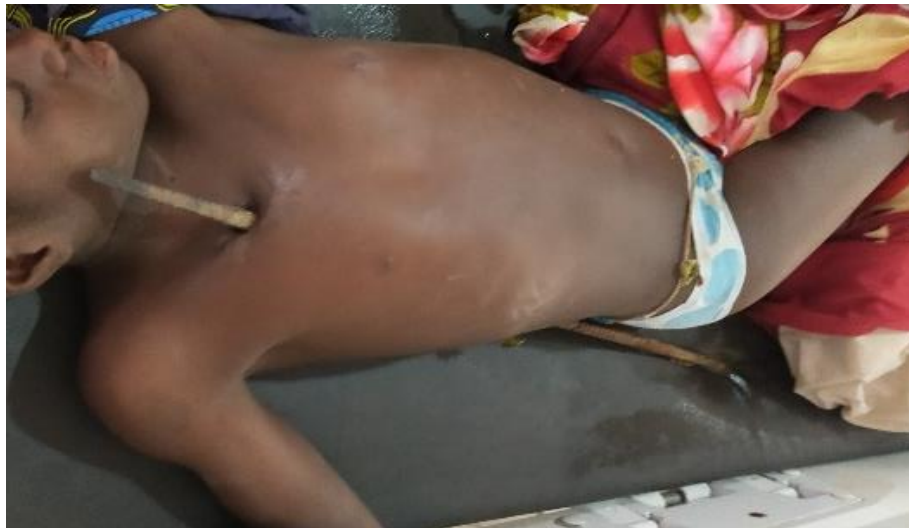## OBSERVATION

This is an 11-year-old student, with no medical and surgical history, received in emergency for thoraco-abdominal trauma following a play activity in the family home. The clinical examination on admission

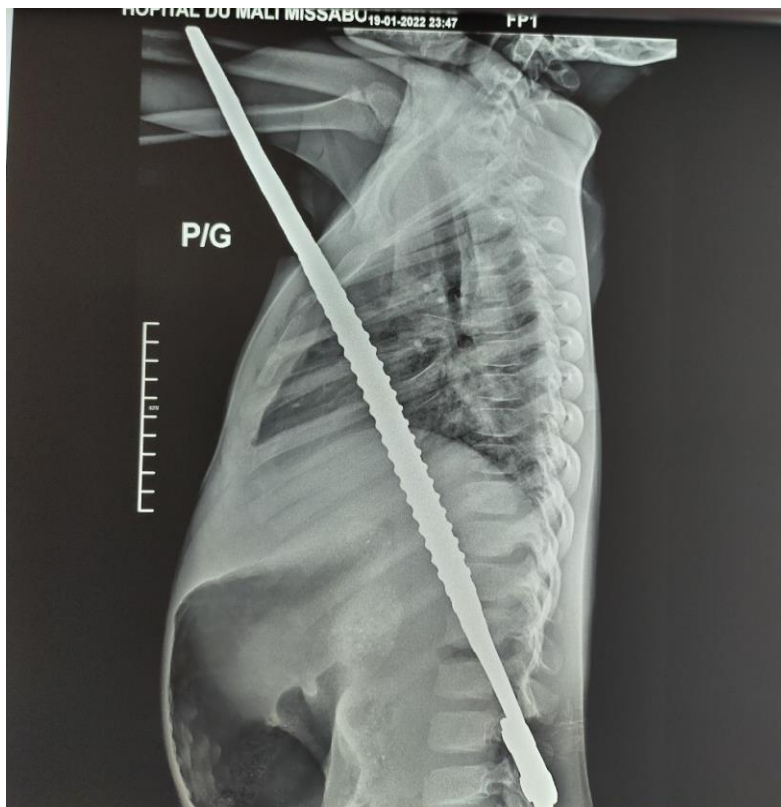
showed an impalement with a full-thickness metal rod extending from the right lumbar fossa to the right subclavicular hollow on inspection (Figure 1). Examination of the rib cage showed neither dullness nor eardrums with good perception of breath sounds. Cardiovascular and abdominal examination was also unremarkable. As an emergency assessment, a chest X-ray (Figure 2) and a PSA were performed, which did not show the presence of pleural and peritoneal effusions. The biological assessment, namely the count, the blood crasis were normal. Faced with this picture, a double surgical team was urgently formed made up of a thoracic and cardiovascular surgeon on the one hand and a pediatric surgeon on the other. The use of a grinding wheel was necessary to cut the distal end of the metal rod. Under general anesthesia with orotracheal intubation, the first operation was abdominal. Patient installed in dorsal decubitus (Figure 3), first by midline laparotomy above and below the umbilical. Exploration found an impalement of the

upper pole of the right kidney, liver, and diaphragm without hemoperitoneum. The gesture consisted in mobilizing the metal rod and a suture of the hepatic and renal lesions with absorbable thread 3/0 and the diaphragmatic spade with absorbable thread 1, followed by abdominal cleansing with isotonic saline solution with placement of a drain sub-hepato diaphragmatic. The second stage was the thoracic approach. The patient is installed in the left lateral decubitus position with a block under the armpit. A posterolateral thoracotomy passing through the 5th intercostal space

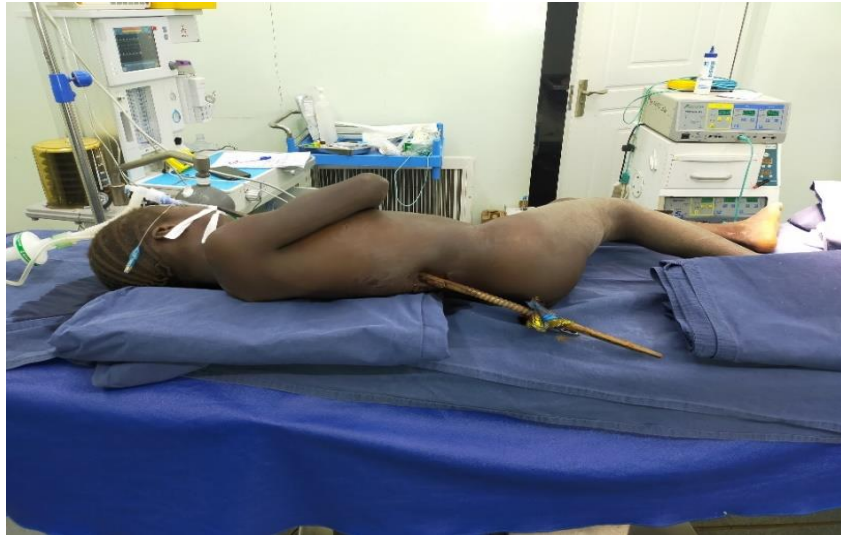was the approach. On exploration, no intrathoracic organ lesion was observed. The gesture consisted in the extraction of the metal rod with grooming of the pleural cavity with isotonic saline, the establishment of a CH24 pleural drain, closure then dressing. As postoperative care it was injectable paracetamol 500mg/6h, ceftriaxone 500mg/12h, serum and anti-tetanus vaccine and respiratory physiotherapy. The postoperative course was simple. The patient's examination was done on D6 with unremarkable outpatient follow-up. At D15 post-operative, the wounds were well healed (Figure 4).



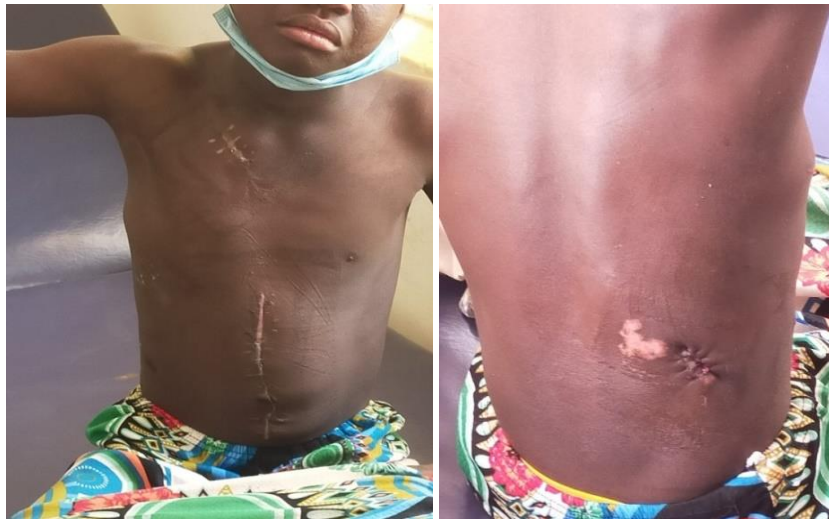**Figure 1: Thoracoabdominal impalement by iron bar**



**Figure 2: Profile chest X- ray**



**Figure 3: Installation of the patient on the operating table**



**Figure 4: Post-operative scars**

## DISCUSSION

Penetrating thoraco-abdominal wounds are most often caused by gunshot wounds. Impalement is a potentially serious lesion that can be immediately life-threatening and depends on the organs affected. Lesions with damage to the heart or large vessels are potentially fatal and very few cases of survivors have been reported [2, 3, 5]. They require specific care that may involve several specialties. They are most often accidental and can be professional, with the main victims most often construction site workers or domestic workers [1, 4]. Our case study concerns a patient victim of a domestic accident following a playful activity within the family home. The injuring agent was a concrete rod positioned within the home without any security measures and which was used to tie up sheep intended for domestic breeding. Management of impalements must comply with rules so as not to aggravate the lesions [4]. The injuring object must under no circumstances be removed from the accident site but may be cut on either side to facilitate transport of the injured person [4, 5]. The patient was received with the metal rod bar performing

a thoraco-abdominal impalement. A medical ambulance facilitated his evacuation to our hospital, after receiving first aid in his basic health training. An exhaustive clinical examination is necessary for optimal management and would also allow, depending on the orientation of the impalement, to have an idea of the organs probably affected. Impalement injuries are classified into three types based on the mechanism. Type I: when there is an impact of a moving body against a fixed object (this is the case in our observation), type II: when there is an impact between a moving object and the body stationary and type III: when there is an impact between an object and a moving body [4]. Patients with hemodynamic instability are immediately admitted to the operating room [4]. In other cases, paraclinical exploration is necessary. 3D CT scan with reconstruction slice acquisition and angiography, FAST abdominal ultrasound, thoracoscopy or laparoscopy can be of major benefit. These examinations make it possible to assess the lesion beforehand and also to guide treatment [2, 4, 8, 10]. These exams are still not available urgently



in our usual working conditions. Only the clinical examination and a thoracoabdominal X-ray as well as a blood count with rhesus groups were carried out. Antibiotic prophylaxis is necessary in patients [3, 4]. Surgical exploration must be systematic in any case of impalement. The surgical approach can vary from one operator to another [4]. But the direct visualization of the entry and exit orifice of the foreign body makes it possible to analyze the trajectory and extract it under visual control in order to allow optimal vascular control. In our case study, a double team made up of a thoracic and cardiovascular surgeon and a pediatric surgeon was urgently formed for a double thoraco-abdominal approach. Under general anesthesia with orotracheal intubation, the initial installation was decubitus for the abdominal approach then lateral decubitus for the thoracic approach. Diaphragmatic lesions are almost present due to its anatomical position [3, 8]. Intraoperative exploration did not reveal any major vascular lesion. Under visual control the metal rod was removed without incident. Surgical repair of the injured organs and abundant washing of the path of the foreign body and placement of chest and abdominal drains must be performed for postoperative monitoring [4]. This gesture was performed in our case and the postoperative course was simple.

## CONCLUSION

Thoracoabdominal impalement injuries are potentially serious and can be life-threatening. Its management is a challenge in countries with limited resources like ours. Good coordination of medico-surgical care allowed optimal management of the patient.

## CONFLICT OF INTEREST

The authors declare no conflict of interest in relation to this article.

## Contribution of the Authors

Souleymane Sidibé was the designer of our study and TOGO S2, OUATTARA MA2, YENA S2 supervised the conduct of the clinical case study. Souleymane Sidibé and Seydou Mariko edited the manuscript. All the authors contributed substantially to the manuscript. All authors had read and approved the final manuscript before submission.

## REFERENCES

- Okumori, M. A. S. A. N. A. O., Futamura, A. K. I. R. A., Tsukuura, T. O. S. H. I. O., Konno, S. U. S. U. M. U., Kuramochi, K. A. Z. U. K. O., Kaya, S. E. I. J. I., & Yamada, F. U. M. I. N. O. R. I. (1981). Impalement wounds of the head and chest by reinforced steel bars with recovery: an unusual case report. *The Journal of Trauma*, 21(3), 240-241.
- Shimokawa, S., Shiota, K., Ogata, S., Toyohira, H., Moriyama, Y., & Taira, A. (1994). Impalement injury of the thorax: report of a case. *Surgery today*, 24, 926-928.
- Mandal, A. K., & Sanusi, M. (2001). Penetrating chest wounds: 24 years' experience. *World journal of surgery*, 25, 1145-1149.
- Pirvu, A., Soucemarianadin, M., Reche, F., & Magne, J. L. (2013). Empalement abdomino-pelvien: UN accident rare. In *Annales francaises d'anesthesie et de reanimation* (Vol. 9, No. 32, pp. 629-631).
- Afzal, R. M., Armughan, M., Javed, M. W., Rizvi, U. A., & Naseem, S. (2018). Thoracic impalement injury: a survivor with large metallic object in-situ. *Chinese journal of traumatology*, 21(06), 369-372.
- Onat, S., Ulku, R., Avci, A., Ates, G., & Ozelcik, C. (2011). Urgent thoracotomy for penetrating chest trauma: analysis of 158 patients of a single center. *Injury*, 42(9), 900-904.
- Barbois, S., Abba, J., Guigard, S., Quesada, J. L., Pirvu, A., Waroquet, P. A., ... & Arvieux, C. (2016). Management of penetrating abdominal and thoraco-abdominal wounds: about a retrospective series of 186 cases. *Journal of Visceral Surgery*, 153(4), 73-83.
- Biffl, W. L., & Moore, E. E. (2010). Management guidelines for penetrating abdominal trauma. *Current opinion in critical care*, 16(6), 609-617.
- Doumbia, D., Soumaré, L., Etoughe, M. Y., & Soumaré, S. (2006). Chest trauma at Point "G" Hospital. *Malimedical*, 21(1), 43.
- Amore, D., Muto, E., Casazza, D., Cicalese, M., Rispoli, M., & Curcio, C. (2020). Penetrating pulmonary injury caused by a steel rod. *Respirology Case Reports*, 8(7), e00640.
- Van Waes, O. J. F., Van Riet, P. A., Van Lieshout, E. M. M., & Hartog, D. D. (2012). Immediate thoracotomy for penetrating injuries: ten years' experience at a Dutch level I trauma center. *European Journal of Trauma and Emergency Surgery*, 38, 543-551.
- Asensio, J. A., Arroyo, H., Veloz, W., Forno, W., Gambaro, E., Roldan, G. A., ... & Demetriades, D. (2002). Penetrating thoracoabdominal injuries: ongoing dilemma—which cavity and when?. *World journal of surgery*, 26, 539-543.
- Struck, G. T., Nabhen, J. J., Soek, H. A., Moretti, R., Yamaguto, G. E., Moriya, V. L., ... & Urdiales, A. I. A. (2021). Transfixing heart injury by stab wound: Case report. *Trauma Case Reports*, 35, 100518.
- Berg, R. J., Karamanos, E., Inaba, K., Okoye, O., Teixeira, P. G., & Demetriades, D. (2014). The persistent diagnostic challenge of thoracoabdominal stab wounds. *Journal of Trauma and Acute Care Surgery*, 76(2), 418-423.