

The Prevalence of Ocular Surface Disease in Glaucoma Patients

C. Talbi^{1*}, H. Taouti¹, S. Belghmaidi¹, I. Hajji¹, A. Moutaouakil¹

¹University Hospital Mohammed VI, Marrakech, Morocco

DOI: [10.36347/sasjs.2023.v09i02.008](https://doi.org/10.36347/sasjs.2023.v09i02.008)

| Received: 19.12.2022 | Accepted: 30.01.2023 | Published: 17.02.2023

*Corresponding author: C. Talbi

University Hospital Mohammed VI, Marrakech, Morocco

Abstract

Original Research Article

Introduction: Glaucoma is the third cause of blindness in developed countries after age-related macular degeneration (AMD) and diabetic retinopathy. The aim of this study was to determine the prevalence of ocular surface disease in patients treated for glaucoma or ocular hypertension. **Patients and methods:** We conducted a one-year observational study including glaucoma patients older than 15 years, diagnosed and treated for more than six months. The impact of anti-glaucoma treatment on the ocular surface was assessed by a questionnaire derived from the Ocular Surface Disease Index (OSDI). **Results:** Antiglaucoma treatment caused an alteration of the ocular surface in 59% of patients. 61.7% of patients had a mean epithelial thickness below normal. **Discussion:** Several observational studies have shown a high prevalence of ocular surface disease in glaucoma patients. The prevalence of surface involvement in our study is close to most studies in the literature. The strong correlation between the number of eye drops prescribed and the severity of ocular surface involvement has been proven. This correlation is attributed to the preservative benzalkonium chloride (BAK). Among the cellular alterations, we noted a decrease in mucus cells with a decrease and instability of the thickness of the tear film, which was more important in patients under BAK preserved eye drops than in those without BAK. **Conclusion:** Our study allowed us to determine the frequency of ocular surface damage in patients treated long-term with hypotonizing eye drops. The mechanisms of this damage are multiple. Preservatives seem to play a central role in the genesis of these reactions.

Keywords: Antiglaucoma treatment - ocular surface disease - benzalkonium chloride.

Copyright © 2023 The Author(s): This is an open-access article distributed under the terms of the Creative Commons Attribution 4.0 International License (CC BY-NC 4.0) which permits unrestricted use, distribution, and reproduction in any medium for non-commercial use provided the original author and source are credited.

INTRODUCTION

Glaucoma is a common disease, affecting 0.5-1% of adults over 40 years of age in Europe and North America. It is the third leading cause of blindness in developed countries after age-related macular degeneration (AMD) and diabetic retinopathy [1]. Ocular surface diseases include all tear film alterations and inflammatory phenomena causing ocular surface tissue damage [2]. The aim of this study is to determine the prevalence of ocular surface pathology in patients treated for glaucoma and ocular hypertension.

PATIENTS AND METHODS

This is an observational study, during the specialized consultation of glaucoma patients carried out at the ophthalmology department of CHU Mohamed VI Marrakech, over a period of one year. We included all glaucoma patients aged more than 15 years, diagnosed and put under treatment for more than 6 months, and we excluded patients put under short term hypotonizing treatment for a period less than 6 months.

All patients underwent a complete ophthalmological examination including clinical evaluation of the ocular surface. A questionnaire derived from the Ocular Surface Disease Index (OSDI) was used to assess the impact of this condition on the patients' quality of life. According to the clinical damage to the ocular surface, the patients were classified into three groups (A: no damage; B: moderate damage; C: severe damage), and according to the severity of the symptomatology, in particular the OSDI score, into four groups (no symptoms, mild damage, moderate damage and severe damage). Epithelial pachymetry mapping was performed using OCT-SA in all our patients.

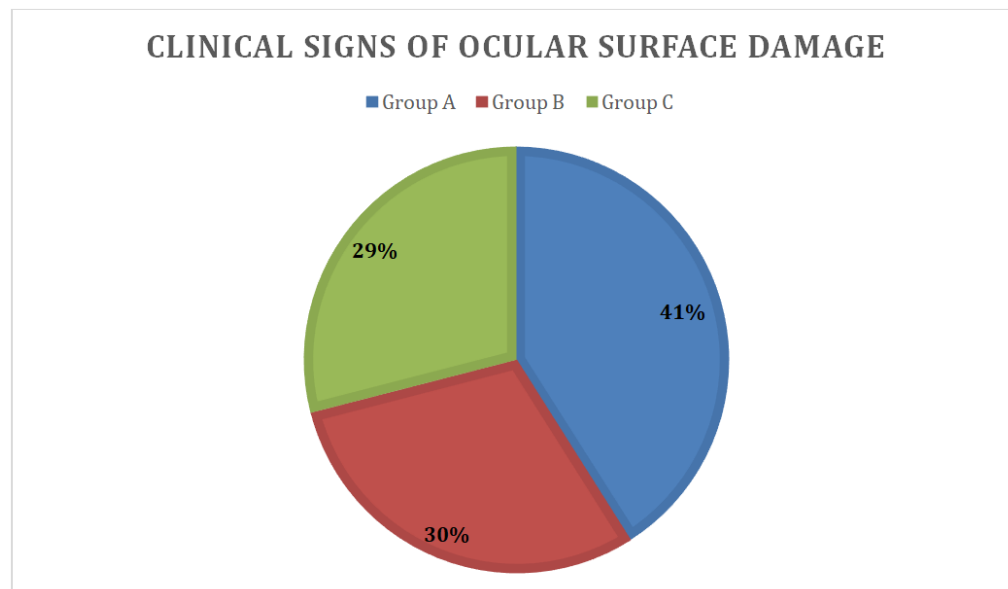
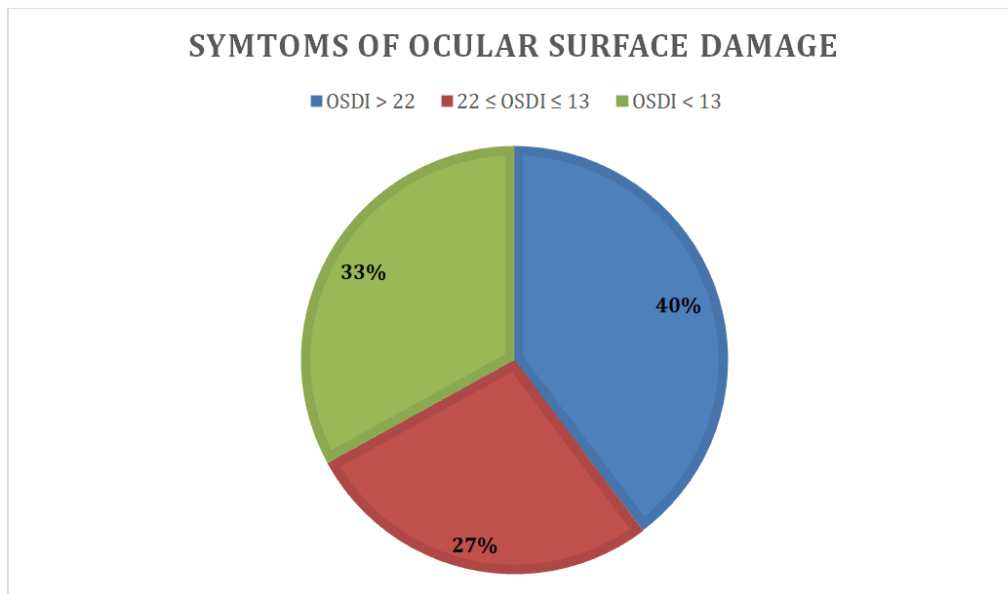
RESULTS

We collected 73 patients over a period of one year, aged between 15 and 79 years with a mean age of 57 years, and a sex ratio of 0.7 (43 women and 30 men). Eight patients were monophthalmic. The mean visual acuity was 4/10th after optical correction. The average age of glaucoma was 5.7 years. In our study, 29 patients (39.7%) had significant symptoms of ocular surface

damage (OSDI score >22). Symptoms of mild ocular surface damage were found in 20 patients (27.3%). Twenty-four patients (33%) had no symptoms of ocular surface damage.

The patients were divided into clinical classifications A, B and C. Group A (no involvement), group B (moderate involvement) and group C (severe involvement) comprised 30 (41%), 22 (30%) and 21 (29%) patients respectively. Moderate to severe clinical involvement (B+C) of the ocular surface was observed in 43 patients (59%).

Almost one third of the patients were on monotherapy (24 patients or 33%), 50% (36 patients) were on dual therapy, the rest of the patients were on triple or quadruple therapy. Epithelial pachymetry mapping was normal in 28 patients (38.3%), with a mean epithelial thickness of $53.2 \pm 0.7\mu\text{m}$, the rest of the patients had a mean epithelial thickness below normal of $46.1 \pm 2.9 \mu\text{m}$. Only 20% of our patients were on anti-glaucoma therapy without preservatives, 60% were on anti-glaucoma therapy with only one preservative, while the remaining patients had more than one preservative in their treatment.



DISCUSSION

The treatment of glaucoma aims to preserve quality of life, and is therefore a compromise between the need to lower IOP as much as possible in order to avoid visual field degradation, and the need to limit the

side effects of treatment which can alter the quality of life of patients, and also reduce compliance with treatment. Long-term administration of antiglaucoma eye drops to reduce IOP induces changes in the tissues that make up the ocular surface [3, 4]. Several

observational studies have shown a high prevalence of ocular surface pathology in glaucoma patients. In a multicentre cross-sectional study in four European countries, which included more than 9,600 patients treated for glaucoma or high IOP level, the prevalence of symptoms and clinical signs of ocular surface damage was 40% and 20% respectively [5]. The prevalence of ocular surface symptoms was also estimated to be close to 50% in a prospective study involving 630 glaucoma patients [6]. In this study, the prevalence of symptoms was also correlated with the number of antiglaucoma eye drops used. Analysis of the German dry eye registry, which includes more than 20,500 patients and 900 centres, showed that the incidence of dry eye increased with the age of the patients, the age of the glaucoma, and when the number of antiglaucoma treatments reached or exceeded three drops per day [7]. Recently, a French multicentre study included 516 patients receiving long-term antiglaucoma treatment [8]. Ocular surface involvement was found in 51% of patients, and 21% had moderate to severe involvement. Although few in number, these observational studies all agree that evidence of ocular surface involvement is present in 15-50% of patients treated for glaucoma or high IOP level, depending on the criteria used, a significantly higher prevalence than in the general population [9]. The prevalence of surface involvement in our study is similar to most studies in the literature. When comparing the severe OSDI found in our series (19.2%) with other studies we find a similar prevalence compared to an international study (20.3%) [10], and more important compared to the American study (13.8%) [11]. The strong correlation between the number of eye drops prescribed and the severity of ocular surface damage has been demonstrated. This correlation is attributed to the preservative benzalkonium chloride (BAK), among the cellular alterations there is a decrease in mucus cells with a decrease and instability of the thickness of the lacrimal film more important in patients under BAK preserved eye drops compared to those without BAK [12]. These BAK-induced effects can be reversed in some patients, especially by adding sodium hyaluronate-based artificial tears, and by changing the hypotonating treatment to other preservative-free drugs, or to a less harmful preservative [13, 14].

CONCLUSION

Our study allowed us to determine the frequency of ocular surface damage in patients treated long-term with hypotonising eye drops. The mechanisms of this damage are multiple. Preservatives seem to play a central role in the genesis of these reactions. These alterations to the ocular surface may be manifested both by symptoms of poor tolerance reported by patients and by clinical and paraclinical signs observed by the ophthalmologist, who should systematically include examination of the ocular surface in the same way as ocular tone is measured in glaucoma patients.

REFERENCES

- Weinreb, R. N., Kitazawa, Y., & Krieglstein, G. K. (2000). *Glaucoma in the 21st century*. Barcelona, Espagne: Mosby international Ltd, *Harcourt Health Communications*.
- Leung, E. W., Medeiros, F. A., & Weinreb, R. N. (2008). Prevalence of ocular surface disease in glaucoma patients. *Journal of glaucoma*, 17(5), 350-355.
- Asbell, P. A., & Potapova, N. (2005). Effects of topical antiglaucoma medications on the ocular surface. *The Ocular Surface*, 3(1), 27-40.
- Baudouin, C. (2008). Detrimental effect of preservatives in eyedrops: implications for the treatment of glaucoma. *Acta ophthalmologica*, 86(7), 716-726.
- Jaenen, N., Baudouin, C., Pouliquen, P., Manni, G., Figueiredo, A., & Zeyen, T. (2007). Ocular symptoms and signs with preserved and preservative-free glaucoma medications. *European journal of ophthalmology*, 17(3), 341-349.
- Fechtner, R. D., Godfrey, D. G., Budenz, D., Stewart, J. A., Stewart, W. C., & Jasek, M. C. (2010). Prevalence of ocular surface complaints in patients with glaucoma using topical intraocular pressure-lowering medications. *Cornea*, 29(6), 618-621.
- Erb, C., Gast, U., & Schremmer, D. (2008). German register for glaucoma patients with dry eye. I. Basic outcome with respect to dry eye. *Graefes archive for clinical and experimental ophthalmology*, 246(11), 1593-1601.
- Baudouin, C., Renard, J. P., Nordmann, J. P., Denis, P., Lachkar, Y., Sellem, E., ... & Bouée, S. (2013). Prevalence and risk factors for ocular surface disease among patients treated over the long term for glaucoma or ocular hypertension. *European journal of ophthalmology*, 23(1), 47-54.
- Dry Eye WorkShop. (2007). The epidemiology of dry eye disease: report of the Epidemiology Subcommittee of the International Dry Eye WorkShop (2007). *Ocul Surf*, 5, 93-107.
- Garcia-Feijoo, J., & Sampaolesi, J. R. (2012). A multicenter evaluation of ocular surface disease prevalence in patients with glaucoma. *Clinical Ophthalmology (Auckland, NZ)*, 6, 441-446.
- Fechtner, R. D., Godfrey, D. G., Budenz, D., Stewart, J. A., Stewart, W. C., & Jasek, M. C. (2010). Prevalence of ocular surface complaints in patients with glaucoma using topical intraocular pressure-lowering medications. *Cornea*, 29(6), 618-621.
- Ciancaglini, M., Carpineto, P., Agnifili, L., Nubile, M., Fasanella, V., Lanzini, M., ... & Mastropasqua, L. (2008). An in vivo confocal microscopy and impression cytology analysis of preserved and unpreserved levobunolol-induced conjunctival

- changes. *European journal of ophthalmology*, 18(3), 400-407.
13. Katz, G., Springs, C. L., Craven, E. R., & Montecchi-Palmer, M. (2010). Ocular surface disease in patients with glaucoma or ocular hypertension treated with either BAK-preserved latanoprost or BAK-free travoprost. *Clinical Ophthalmology (Auckland, NZ)*, 4, 1253-1261.
14. Yee, R. W. (2007). The effect of drop vehicle on the efficacy and side effects of topical glaucoma therapy: a review. *Current Opinion in Ophthalmology*, 18(2), 134-139.