

## Valgus Osteotomy for Non-Union Fracture Neck of Femur in a Child: A Case Report

Aruddha Sarkar<sup>1\*</sup>, Saurabh Sahni<sup>2</sup>, Biswarup Sen<sup>3</sup>

<sup>1</sup>Senior Resident, Department of Orthopaedics, Deep Chand Bandhu Hospital, Ashok Vihar New Delhi, India

<sup>2</sup>Associate Consultant, Department of Orthopaedics, Max Superspeciality Hospital, Shalimar Bagh, New Delhi, India

<sup>3</sup>Consultant, Department of Orthopaedics, Sant Parmanand Hospital, Civil Lines, New Delhi, India

DOI: [10.36347/sasjs.2023.v09i02.013](https://doi.org/10.36347/sasjs.2023.v09i02.013)

Received: 14.01.2023 | Accepted: 21.02.2023 | Published: 22.02.2023

\*Corresponding author: Aruddha Sarkar

Senior Resident, Department of Orthopaedics, Deep Chand Bandhu Hospital, Ashok Vihar New Delhi, India

### Abstract

### Case Report

Paediatric neck of femur fractures is rare and incorporates less than 1% of all the paediatric fractures. Complications of femoral neck fractures in children includes necrosis (AVN) of femoral head, non-union and premature closure of the proximal femoral physis— resulting in decrease of growth, coxa vara and limb-length discrepancies. In past, the incidence of non-union varied from 7% to 10%, depending on the location of the fracture in the neck of femur the incidence of non-union in these fractures have significantly reduced in the recent times due to early anatomical reduction and rigid internal fixation. Due to the small number of cases, the treatment protocols for non-union of the paediatric femoral neck fractures are not well defined. Valgus osteotomy changes the shearing force at the non-union site to compression forces which provides optimal environment for bone union. Here we present a case of 6 years old child who presented with non-united fracture of the neck of femur with coxa vara, 1 year after conservatively treated osteomyelitis of proximal femur with valgus intertrochanteric osteotomy.

**Keywords:** Non-union, Paediatric, Neck of Femur, Valgus Osteotomy.

Copyright © 2023 The Author(s): This is an open-access article distributed under the terms of the Creative Commons Attribution 4.0 International License (CC BY-NC 4.0) which permits unrestricted use, distribution, and reproduction in any medium for non-commercial use provided the original author and source are credited.

## INTRODUCTION

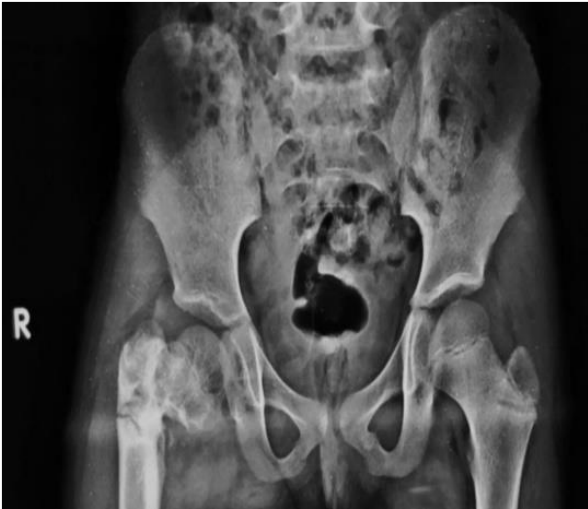
Paediatric neck of femur are rare and incorporates less than 1% of all the paediatric fractures [1, 2]. Femoral neck fractures in children are different from adults because of the presence of epiphyseal plate and the vulnerability of blood vessels in the femoral head. Complications of femoral neck fractures in children includes necrosis (AVN) of femoral head, non-union and premature closure of the proximal femoral physis— resulting in decrease of growth, coxa vara and limb-length discrepancies [2]. Non-union of the femoral neck fractures in children is common after conservative treatment or treatment of fixation with multiple screws or K-wires. In past, the incidence of non-union varied from 7% to 10%, depending on the location of the fracture in the neck of femur the incidence of non-union in these fractures have significantly reduced in the recent times due to early anatomical reduction and rigid internal fixation [1-3]. Still, non-united femoral neck fractures are often reported in developing countries due to lack of medical care, mismanagement by traditional bone-setters and quacks and delayed referrals [1-3]. Due to the small number of cases, the treatment protocols for non-union of the paediatric femoral neck

fractures are not well defined. Valgus intertrochanteric osteotomy has been reported to treat this problem with rather good results in relatively older patients [1-4]. Biomechanically, valgus osteotomy changes the shearing force at the non-union site to compression forces which provides optimal environment for bone union [1, 2]. Here we present a case of 6 years old child who presented with non-united fracture of the neck of femur with coxa vara, 1 year after conservatively treated osteomyelitis of proximal femur with valgus intertrochanteric osteotomy [1-5].

## CASE REPORT

A 6-year-old male child was presented to the OPD of Max Superspeciality Hospital and admitted with complaints of pain in right hip and difficulty in walking for the last 4 months following a trivial fall at home preceded by osteomyelitis of the proximal femur 1 year back which was managed conservatively. Systemic examination was unremarkable. On local examination, the patient had a short limb and Trendelenburg gait with no hip joint tenderness. Apparent and true shortening of 1 cm was present corroborating with supra-trochanteric shortening. On

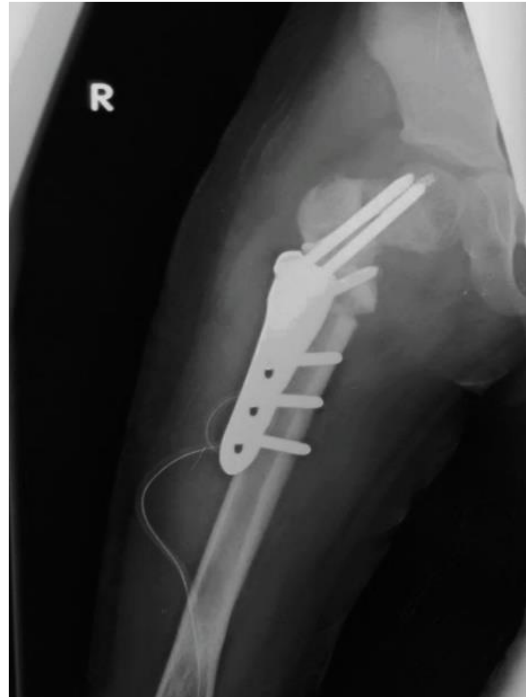radiological examination, there was an evidence of fracture neck of femur with coxa vara (Fig1).



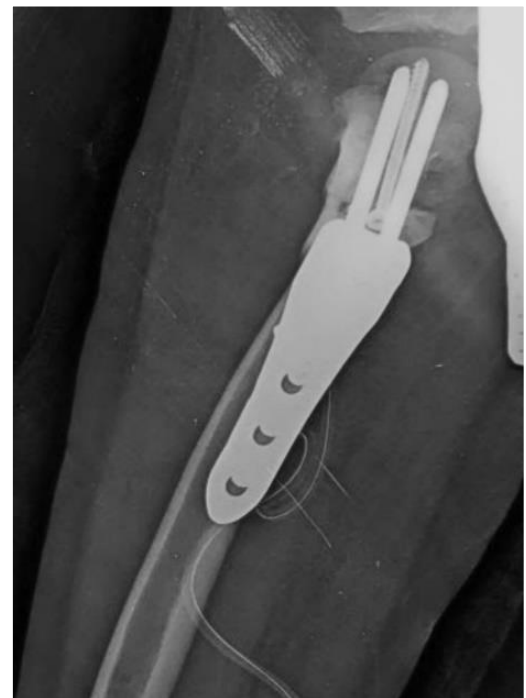
**Fig 1: Pre-operative X-ray**

### Surgical Technique

The angle of correction was determined from pre-operative planning by calculating the angle from contra-lateral normal hip. Routine pre-anaesthetic investigations were done. The operation was performed in supine position on a radiolucent operating table. The proximal femur was exposed sub-periosteally by detaching vastus lateralis muscle through a straight lateral approach and the anterior aspect of the femur was stripped widely till to the base of the neck. A Kirschner wire or K-Wire was inserted on the anterior surface of the femoral neck indicating the femoral anteversion. Then a threaded pin was inserted and drilled along the longitudinal axis of the femoral neck aligning parallel on a lateral view to the pre-positioned K-wire on the anterior aspect of the femoral neck. This angle of insertion of the threaded pin in the neck indicated the correction angle for the altered neck-shaft angle of the affected femur. Next, using the aiming block 2 more cervical pins was placed using the instrument angle guide. After removing the angle guide 2 K-wires are inserted in the lateral aspect of the distal femur and in the greater trochanter to control excessive medial rotation post the osteotomy cut. Osteotomy of the femur was done using oscillating saw 12 mm from the cervical pins after holding the proximal fragment with a special clamp. Then the osteotomy plate was slid over the K-wires. K-wires were removed consecutively and screws placed in position. The femoral shaft was reduced to the osteotomy plate using bone forceps. Definitive fixation of the plate to the femoral shaft cortex done using locking screws. Incision was closed in layers after reattaching vastus lateralis muscle over plate. Drain inserted. Antiseptic dressing of wound done.



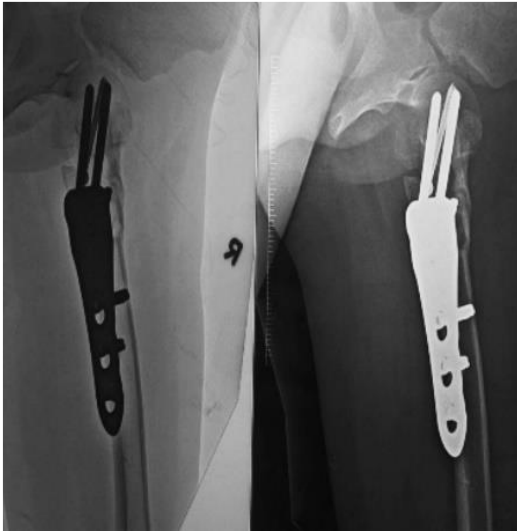**Fig 2: Immediate post-operative X-ray (A.P. view)**



**Fig 3: Immediate post-operative X-ray (Lateral view)**

### Post-operative Care

Stitch removal was done at two weeks post-operative period. Patient was kept non-weight bearing for up to 4 weeks after surgery and then partial weight bearing was allowed from 4<sup>th</sup> week to 6<sup>th</sup> week. Full weight bearing was allowed after 6 weeks from surgery. Patient was advised for subsequent follow-up every two weekly but patient was lost to follow up.



**Fig 4: Post-operative X-ray at 6 weeks**

## DISCUSSIONS

Neglected femoral neck fractures are reported from developing and under-developed countries where the patients are initially seen by bonesetters and inadequately managed [1, 2]. The causes of non-union in femoral neck fractures in children are incomplete reduction, inadequate immobilization, non-operative treatment in undeserving fractures, infection, and implant failure [1, 2]. For operative treatment many different procedures have been described, including close/open reduction and internal fixation using K-wires, cannulated screws, fibula, or nails. Valgus intertrochanteric osteotomy makes the non-union horizontal, thereby allowing the axial compressive forces at hip to assist in bone union. There is no evidence in the literature that one or other implant influences the rate of postoperative complications, such as avascular femoral head necrosis or coxa vara. The fixed angle LCP plate allows precise correction of the

pre-existing deformity because of a guide pin which prepares the penetration angle for the cervical screws in the next step. Preoperative planning is easily achieved [5].

## CONCLUSION

Valgus osteotomy is an effective surgical option for neglected non-united fractures of proximal femur particularly in the paediatric age group and is a bio-mechanically viable option in these cases.

## REFERENCES

1. Sharma, A., Tiwari, A., Verma, T., & Maini, L. (2016). Non-union fracture neck femur in a toddler: Reconstructed by valgus osteotomy—A minimally invasive approach. *Journal of Clinical Orthopaedics and Trauma*, 7, 8-11.
2. Magu, N. K., Singh, R., Sharma, A. K., & Ummat, V. (2007). Modified Pauwels' intertrochanteric osteotomy in neglected femoral neck fractures in children: a report of 10 cases followed for a minimum of 5 years. *Journal of orthopaedic trauma*, 21(4), 237-243.
3. Neto, P. F. T., Dos Reis, F. B., Filho, J. L., Fernandes, H. J., Fujiki, E. N., Bensahel, H., & Milani, C. (2008). Nonunion of fractures of the femoral neck in children. *Journal of children's orthopaedics*, 2(2), 97-103.
4. Eamsobhana, P., & Keawpornawan, K. (2016). Nonunion paediatric femoral neck fracture treatment without open reduction. *Hip International*, 26(6), 608-611.
5. Khouri, N., Khalife, R., Desailly, E., Thevenin-Lemoine, C., & Damsin, J. P. (2010). Proximal femoral osteotomy in neurologic pediatric hips using the locking compression plate. *Journal of Pediatric Orthopaedics*, 30(8), 825-831.