

Consequences of Non-Adherence to Treatment for Advanced Oral Epidermoid Carcinoma

Martiniano SG¹, Henriques DAS¹, Silva JM¹, Martins KEL¹, Agripino GG², Marinho SA^{2*}

¹Student of dentistry, ² Doctor, Professor, Dentistry Course, Center for Sciences, Technology and Health, State University of Paraíba, Campus VIII, Araruna, PB, Brazil

*Corresponding Author:

Name: Sandra Marinho

Email: san_mar2000@yahoo.com.br

Abstract: The objective of this work is to report a case of a female patient with advanced oral epidermoid carcinoma. An 89-year-old female patient resident of the municipality of Araruna, Brazil, who had been a smoker since the age of five years, was sent to the diagnostic team at the State University of Paraíba, Campus VIII. The clinical exam revealed a large ulcerous, crusted tumor on the entire upper lip and ulcerous, erythematous, leukoplakic lesions in the oropharynx. The diagnosis was well-differentiated epidermoid carcinoma T4N0M0. The patient was sent for cancer treatment, which involved excision of the labial tumor and radiotherapy for the intraoral lesions. However, the patient refused to undergo radiotherapy. After nine months, the tumor had metastasized to the submandibular lymph node. The patient's continued refusal to undergo treatment resulted in the growth of the tumor, ulceration of the submental lymph node and death 14 months after the initial diagnosis. Adherence to treatment is an important factor to the prognosis of cancer. Non-compliance on the part of the patient reported herein had a negative effect on her survival.

Keywords: Carcinoma, Neoplasm metastasis, Mouth.

INTRODUCTION

The prevalence of cancer has increased in recent decades and this disease is a major public health problem throughout the world. The World Health Organization estimates an annual incidence of 27 million cases of cancer, 17 million deaths due to cancer and 75 million cancer survivors by the year 2030. The largest effect of this increase in cases of cancer will be on countries with a low to medium income, such as Brazil. Disregarding non-melanoma skin tumors, cancer of the oral cavity is the fourth most frequent type of cancer in men and the ninth most frequent type in women in northeastern Brazil. Moreover, tobacco smoking accounts for approximately 42% of deaths due to mouth cancer [1].

Other etiological factors include excessive exposure to ultraviolet (UV) rays and alcohol abuse. Approximately 15% of tumors that affect the mouth are located in the lower lip due to exposure to UV radiation. Malignant lip tumors affect men more, with a male to female proportion of 5:1 [2]). As such cases are easily visible, early diagnosis and treatment are common [3]. In contrast, intraoral tumors are generally diagnosed in a more advanced stage, often due to a lack of preparedness on the part of dentists for early diagnosis in such cases, resulting in a diminished chance of effective treatment and cure and a high mortality rate [4].

Psychological factors can exert an influence on treatment, as a patient's emotional state is essential to a satisfactory outcome [5]. Since individuals with cancer are in a clinically and psychologically frail state, support from family members is fundamental to compliance with treatment.

This paper describes an uncommon case of well-differentiated epidermoid carcinoma on the upper lip of an elderly patient and inoperable oropharyngeal carcinoma with regional metastasis and progress of the disease due to the patient's refusal to undergo treatment.

CASE REPORT

An 89-year-old female, resident of the municipality of Bananeiras (state of Paraíba, northeastern Brazil) with uncontrolled hypertension and who had been a smoker since the age of five years, presented to the diagnostic team of the State University of Paraíba (Campus VIII) in November 2011 after a neighbor had intervened on her behalf by contacting a community health agent in the municipality of Araruna. The clinical exam revealed a large ulcerous, crusted tumor on the upper lip measuring 5 cm at its largest diameter (Figure 1) and multiple painless, ulcerated, erythematous, leukoplakic lesions involving the soft palate and oropharynx, with each lesion measuring approximately 1 cm (Figure 2). The patient also

exhibited poor oral health, with gingival calculus, worn dental crowns and root remnants. The extraoral exam revealed no evidence of metastasis in the regional ganglia.

An incisional biopsy was performed on the labial tumor but the patient refused to allow biopsies of the oropharyngeal lesions. The biological material was sent for anatomopatological analysis, which confirmed the clinical diagnosis of well-differentiated squamous cell carcinoma (Figure 3). The patient was sent to the Napoleão Laureano Hospital, which is a reference center for cancer treatment in the state of Paraíba. The cancer was staged as T4N0M0 and the treatment plan proposed by the surgical team was excision of the labial tumor, followed by radiotherapy to reduce the oropharyngeal lesions, which were considered to be inoperable.

Considering the patient's advanced age, the well-differentiated tumor and absence of metastasis, the proposed treatment was expected to increase the life expectancy of the patient significantly with relatively satisfactory quality of life, despite the evident negligence of the patient regarding the initial tumor, which had led to the development of extensive lesions. Surgery was scheduled for the following month and the patient was sent for pre-oral cancer treatment as well as the necessary complementary exams and nutritional

accompaniment. In this period, the patient's husband died. The considerable emotional impact of this event led to the non-appearance of the patient on the day scheduled for surgery.

In May 2012, the patient returned to the hospital for surgical excision of the labial tumor, which exhibited excellent healing (Figure 4), and was immediately sent for radiotherapy. However, the patient once again refused to undergo treatment despite the advice of the medical and dental teams and members of the Social Assistance Reference Center of the municipality, who offer to transport her to the hospital if she changed her mind. The patient agreed to home follow-up by the dental team and maintained palliative care of the symptoms with the aid of the medical team. Despite constant orientation regarding the need for radiotherapy, the patient continued to refuse treatment.

In August 2012, an infarcted left submandibular lymph node was discovered, measuring approximately 3 cm in diameter (Figure 5), with a hard consistency and painless upon palpation. In the absence of treatment, the disease progressed rapidly, with the growth of the metastasized lymph node tumor and the involvement of the submental lymph node, with ulceration and suppuration of this lymph node in November of the same year (Figure 6). The patient died in January 2013, 14 months after the initial diagnosis.

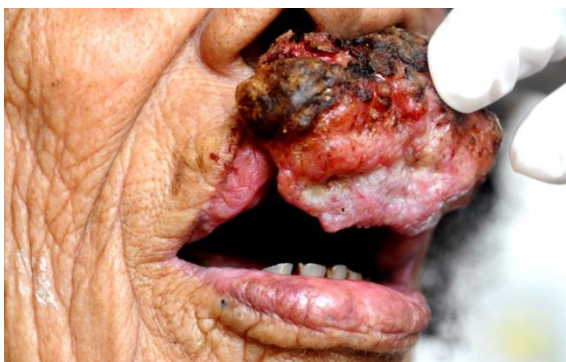

Fig-1: Initial clinical aspect of labial tumor: vegetative mucosa.

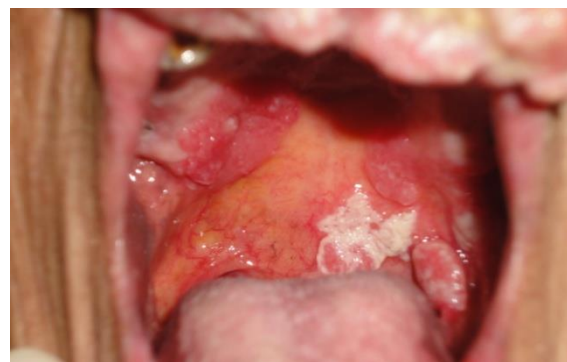

Fig-2: Initial clinical aspect of lesions on soft palate and in oropharyngeal region.

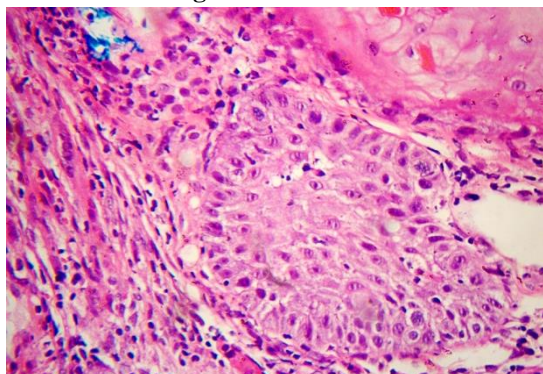


Fig-3: Tumor invasion front in form of solid islands of neoplastic cells (HE staining; magnification: 400x).

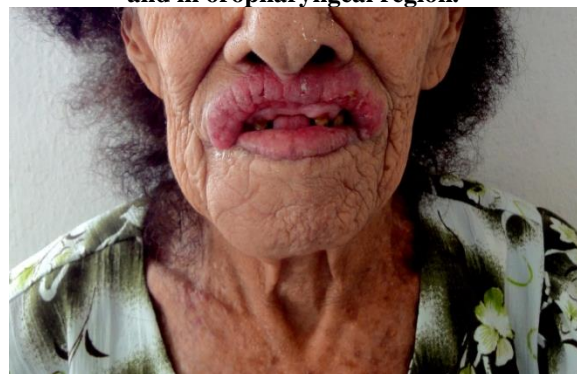

Fig-4: Clinical aspect two weeks postoperatively.

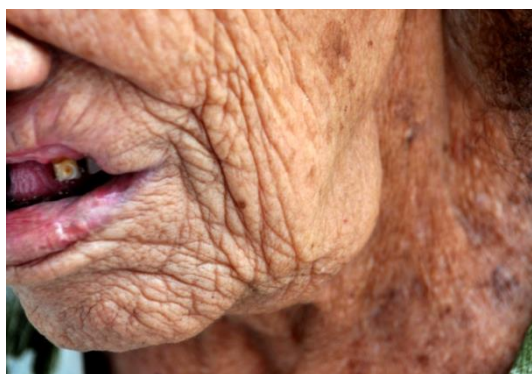


Fig-5: Infarcted left submandibular lymph node 9 months after initial diagnosis.

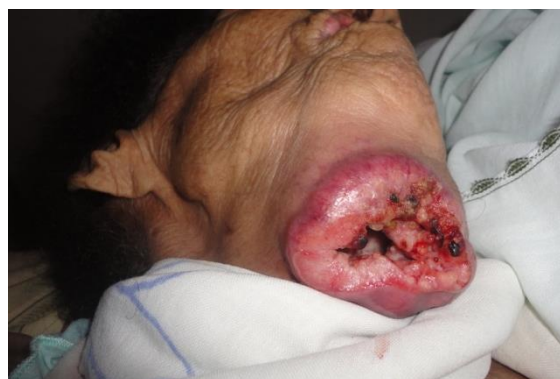

Fig-6: Ulceration and suppuration of submental lymph nodes 14 months after initial diagnosis.

DISCUSSION

Mouth cancer is a public health problem that mainly affects white male smokers [1,2]. In the case reported herein, synchronous tumors were found in an 89-year-old female patient with an 84-year-old smoking habit, which is a relatively uncommon event. Moreover, the upper lip was affected, which is considered rare. The lips of women seem to be more protected due to the use of cosmetics as well as the lesser exposure to aggressive factors, such as solar radiation [2]. As the patient had begun smoking at the age of five years, tobacco was likely the etiological factor for the intraoral lesions. Mortality rates due to oral cancer have declined in the male population in most countries. However, the same has not been found regarding the female gender [1].

The treatment for oral carcinoma should be carefully planned and relies heavily on patient adherence. Although the patient in the present case originally agreed to treatment, she refused to undergo radiotherapy. Such treatment would involve a number of sessions and the need to relocate to the city of João Pessoa (state of Paraíba, Brazil), which is 165 Km from the patient's hometown of Araruna. This fact contributed greatly to the negative outcome of the case.

The labial tumor was completely excised and the surgical wound demonstrated excellent healing. Nonetheless, the patient felt displeased with the esthetic outcome. According to Teixeira [6], despite advances in biomedical practices, the treatment of cancer requires new life strategies in one's relationship with oneself and others, which have consequences with regard to different aspects of life. Due to its anatomic location, mouth cancer poses particular challenges, as surgical intervention in severe cases can leave the face disfigured [7]. In the case reported here, the disfigurement of the patient, with the loss of a large portion of her upper lip, may have contributed to her refusal to undergo further treatment.

It is possible that the death of her husband plunged the patient into a state of mourning and made

her reluctant to leave her home, where she had accumulated countless memories with her long-time companion, and may have also contributed to her giving up on life itself, as she had no other close relatives. According to Del Porto [8], mourning due to the loss of a loved one is characterized by a feeling of deep sadness, the exacerbation of sympathetic activity and restlessness. Normal mourning can last for a year or two and should be differentiated from depression. In normal mourning, an individual generally preserves certain interests and reacts positively to the environment when duly stimulated. In the case reported herein, the mourning of her lost husband may have evolved into actual depression. However, no psychological evaluation was performed to confirm this suspicion. It is possible that this situation contributed to the patient's resistance to moving, even temporarily, to another city for treatment. Women with breast cancer who are also at psychosocial risk are reported to have a poorer prognosis [9]. The present case suggests that the same is true for oral tumors, as emotional stress was an important factor in the patient's decision to cease the treatment procedure [10].

The progression of the oropharyngeal lesions culminated in regional metastasis to the left submandibular lymph node as well as the involvement and suppuration of the submental lymph node. The occurrence of dysphagia due to the lesions led to the hospitalization of the patient in the final stage of her life, when she was quite debilitated. However, she still refused to relocate to the city of João Pessoa to initiate radiotherapy and died 14 months after the initial diagnosis.

CONCLUSION

Despite the timely diagnosis in the present case, the patient's life expectancy was severely compromised by her refusal to undergo treatment, which allowed the progression of the disease, with tumor growth, lymph node involvement, considerable worsening of her condition and eventual death.

REFERENCES

1. Brasil, National Institute of Cancer (INCA). Cancer incidence in Brazil. Estimative 2014. Available from: <http://www.inca.gov.br/estimativa/2014/>
2. Antunes AA, Antunes AP; Lips' tumors retrospective study and literature review: a twenty-eight-year experience. [In Portuguese] *Rev Bras de Cancerologia*, 2004; 50(4): 295-300.
3. Sassi LM, Giustina JCD, Cesa TS, Stramandinoli RT, Schussel J; Rare case of squamous cell carcinoma of superior lip in brown-skinned patient. [In Portuguese] *Rev Cir Traumatol Buco-Maxilo-Fac.*, 2011; 11(1): 27-30.
4. Pedron I, Santos ES, Aburad A, Tortamano IP, Adde CA; Squamous cell carcinoma: Diagnosis and first behavior. [In Portuguese] *Rev Inst Ciência e Saúde*, 2006; 24(3): 237-41.
5. Angerami-Camon VA, Nicoletti EA, Chiattoni HBC; The patient, the Psychology and the hospital. [In Portuguese] 3rd edition, Pioneira, São Paulo, 1996.
6. Teixeira LC; A body that hurts: considerations on the psychoanalytic clinic of psychosomatic phenomena. [In Portuguese] *Latin Am J Fundam Psychopathol*, 2006; 6(1): 21-42.
7. Teixeira LC; Subjective and social implications of oral cancer: psychoanalytic considerations. . [In Portuguese] *Arq Br Psicol.*, 2001; 61(2): 1-12.
8. Del Porto JA; Depression: Concept and diagnosis. [In Portuguese] *Rev Bras Psiquiatr.*, 1999; 1: 6-11.
9. Taylor SE, Lichman RR, Wood JV, Bluming AZ, Dosik GM, Leibowitz RL; Illness-related and treatment-related factors in psychological adjustment to breast cancer. *Cancer*, 1985; 55(10): 2506-2513.
10. Nerenz DR, Leventhal H, Love RR; Factors contributing to emotional distress during cancer chemotherapy. *Cancer*, 1982; 50: 1020-1027.