

Delayed Diagnosis of a Foreign Body Bronchus: An Unusual Case**¹Dr. Mohit Srivastava, ²Dr. Sushant Tyagi, ³Dr. Abhinav Srivastava, ⁴Dr. Aman Agarwal**¹Assistant Professor, Department of ENT, SIMS, Hapur²Senior Resident, Department of ENT, SIMS, Hapur^{3,4}Junior Resident, Department of ENT, SIMS, Hapur

Saraswathi Institute of Medical Sciences, NH-24, Anwarpur, Hapur- 245304, UP, India.

***Corresponding author**

Dr. Mohit Srivastava

Email: dr.mohit141180@gmail.com

Abstract: Tracheo bronchial foreign body is a rare but serious presentation in ENT practice. Late-diagnosed bronchial foreign bodies can cause irreversible changes in the bronchi and the lungs and create life endangering situations. We present a case report of a 6-year-old girl who presented with a history of recurrent cough and fever for 3 months duration. There was no history of weight loss or night sweats. The child was diagnosed as suffering from pneumonia and was given multiple courses of antibiotic therapy on OPD basis. Chest radiograph (PA view) showed collapse of the right lung field. On virtual bronchoscopy a foreign body was visualized in the right main bronchus with compensatory hyperinflation of the left lung field. The patient was taken for rigid bronchoscopy under GA and the foreign body was removed in multiple pieces. Foreign body aspiration is a serious ENT emergency and needs early diagnosis and prompt action to save the life of the patient. Virtual bronchoscopy gives the exact location of the foreign body and helps in surgical planning. Rigid bronchoscopic removal is the mainstay of treatment in such cases.**Keywords:** Foreign body aspiration, virtual bronchoscopy

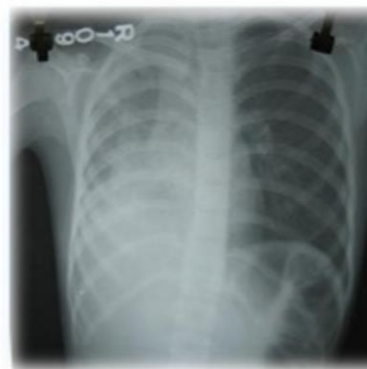INTRODUCTION

Tracheo bronchial foreign body is a rare but serious presentation in ENT practice. Late-diagnosed bronchial foreign bodies can lead to irreversible changes in the bronchi and the lungs. We present a case report summarizing clinico pathological features and surgical treatment options for late-diagnosed bronchial foreign body aspiration.

CASE REPORT

A 6-year-old girl presented with a history of recurrent cough and fever for 3 months duration. There was no history of weight loss or night sweats. The child was diagnosed as suffering from pneumonia and was given multiple courses of antibiotic therapy on OPD basis. There used to be symptomatic improvements on treatment followed by sudden worsening of symptoms intermittently. On general physical examination the child was found to be dyspnic with a respiratory rate of 38/min, chest movements were found to be reduced on right side and on auscultation breath sounds were decreased on right side with coarse crepts. Chest radiograph (PA view) showed collapse of the right lung field. The child was started on broad spectrum I.V antibiotics and was taken up for virtual bronchoscopy. On virtual bronchoscopy a foreign body was visualized in the right main bronchus with compensatory hyperinflation of the left lung field. The patient was taken for rigid bronchoscopy under GA and the foreign

body of groundnut seed was removed. The patient stood procedure well and showed significant improvement in post operative period.

**Fig-1: Showing pre operative right lung collapse on chest Xray**

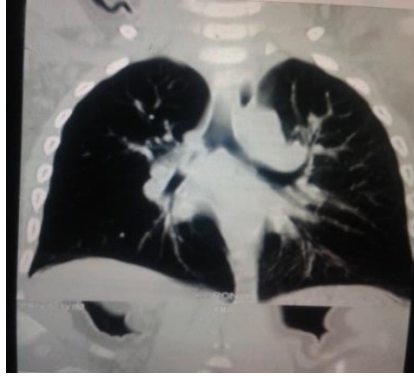

Fig-2: CT Scan showing Foreign Body in right main bronchus

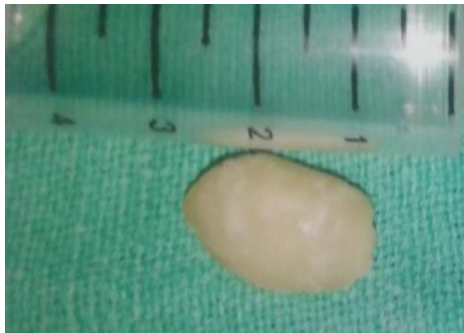


Fig-3: Post op photograph of ground nut piece removed from right main bronchus

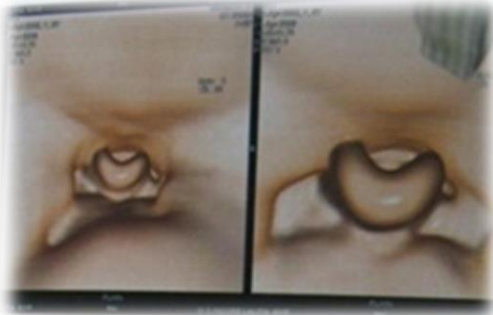


Fig-4: Virtual Bronchoscopy showing foreign body in right main bronchus.

DISCUSSION

Late-diagnosed bronchial foreign bodies can lead to irreversible changes in the bronchi and the lungs [1]. A variety of organic and non organic foreign body has been aspirated into the tracheo bronchial tree. A few cases of accidental tracheostomy tube aspiration have been reported in literature. The cause includes tracheostomy tube breakage and aspiration of various components into tracheo bronchial tree [2]. Chest radiographs are commonly performed in children with suspected FBA. Chest radiographs may show unilateral lobar hyperlucency, localized atelectasis, and localized pulmonary infiltrate. However a normal chest

radiograph cannot exclude a foreign body aspiration and so in suspected cases and in undetected cases, computed tomography (CT) scanning should be done [3]. Visualization of the tracheo bronchial tree with flexible/rigid bronchoscopy is the preferred procedure in the diagnosis of FBA. With the use of a flexible bronchoscope under local anaesthesia for the visualization of airways, removal of the foreign body can be attempted to avoid the added cost, risk, and morbidity of a second procedure: rigid bronchoscopy under general anaesthesia. Furthermore, fiberoptic bronchoscopy is superior to rigid bronchoscopy in cases of distally wedged foreign bodies, in mechanically ventilated patients or in cases of spine, jaw, or skull fractures preventing rigid bronchoscope manipulation. Unresolving pneumonia, lung abscess, recurrent haemoptysis, lung fibrosis, obstructive emphysema, middle lobe syndrome, and bronchiectasis are the reported late complications of a retained tracheo bronchial foreign body [4]. It is commonly believed that inhaled foreign bodies are lodged preferentially in the right bronchial tree due to its more direct route. But Rageb *et.al*; reported that inhaled metallic pins were more often lodged in left bronchial tree than the right side with statistical significance. They attributed this finding to the Bernoulli phenomenon. Coughing, laughing or speaking creates negative pressure in the left bronchial tree [5].

CONCLUSION

A thorough and meticulous history taking, great deal of clinical suspicion, physician awareness of potential foreign body aspiration and expertise in bronchoscopic examination are helpful in treating life threatening cases of foreign body aspiration in tracheo bronchial tree. Foreign body aspiration is a serious medical emergency and needs timely diagnosis and prompt action. The rigid bronchoscopic removal is still the mainstay of treatment and gives miraculous results in the hands of experienced surgeons.

REFERENCES

1. Duan L, Chen X, Wang H, Hu X, Jiang, G; Surgical treatment of late-diagnosed bronchial foreign body aspiration: a report of 23 cases. *The Clinical Respiratory Journal*, 2014; 8: 269–273.
2. Solanki B, Solanki Y; Broken non–fenestrated synthetic tracheostomy tube as a foreign body in tracheo bronchial tree – A unique case. *Trans world Medical Journal*, 2014; 2(1):61–63.
3. Singh R, Gangopadhyay A, Gupta D, Pandey V; Migrating Foreign Body Bronchus: An Unusual Case of Foreign Body Aspiration. *Case Reports in Clinical Medicine*, 2014; 3: 407-409.

-
4. Dikensoy O, Usalan C, Filiz A; Foreign body aspiration: clinical utility of flexible bronchoscopy. *Postgraduate medical journal*, 2002; 78(921): 399-403.
 5. Rizk N, Gwely NE, Biron VL, Hamza U; Metallic hairpin inhalation: a healthcare problem facing young Muslim females. *Journal of Otolaryngology–Head and Neck Surgery*, 2014; 43(1): 21.