

**A Rare Case of Primary Isolated Extrahepatic Intra-Abdominal Hydatid Cyst****Dr. Souvik Basak<sup>1\*</sup>, Dr. Abhishek Sharma<sup>2</sup>, Dr. Dhritiman Maitra<sup>3</sup>, Prof. (Dr.) Kashi Nath Das<sup>4</sup>**<sup>1</sup>Senior Resident, <sup>2</sup>Post Graduate Trainee, <sup>3</sup>Assistant Professor, <sup>4</sup>Professor and Head, Department of Surgery, Medical College, Kolkata.**\*Corresponding author**

Dr. Souvik Basak

Email: [sb009cmc@gmail.com](mailto:sb009cmc@gmail.com)

---

**Abstract:** We report a case of a fifty-year-old lady presenting with abdominal distension for 2 months associated with dull aching pain and intermittent fever. Contrast enhanced CT scan showed loculated fluid filled cystic swelling occupying whole abdomen up to pelvis in addition to another loculated cyst with intra-cystic debris in left hypochondrium (15 cm x 18 cm). Liver and lungs were found normal and small intestine found pushed to right. The enzyme-linked immune-absorbent assay (ELISA) for echinococcal antibodies came out positive. Exploratory laparotomy, evacuation of pus with membranes followed by peri cystectomy was done and adjuvant Albendazole therapy was added. Histopathology examination confirming it to be a hydatid cyst. The rarity of the diagnosis along with its mode and nature of presentation and absence of several characteristic features make this case an interesting one.**Keywords:** Extrahepatic hydatid cyst, Intestinal Hydatid Cyst, Intra-abdominal hydatid cyst, Primary and Isolated Extrahepatic hydatid cysts.

---

**INTRODUCTION:**

Primary and isolated extrahepatic intra-abdominal hydatid cysts (PIEHC) are rare and only a few sporadic series have been reported. The rarity of the diagnosis, mode of presentation and apparent lack of distinctive symptoms has prompted us to report this case.

Hydatid cyst or Echinococcosis is a zoonotic parasitic disease caused by tapeworm (*Echinococcus granulosus*) that occurs primarily in sheep grazing areas, but it is common worldwide because dog is a definitive host [1]. The disease is endemic in many Mediterranean countries, the Middle East and Far East, South America, South and East Africa. Liver (45-75%) and lungs (10-50%) are most commonly involved organs [5-7]; liver being involved in two third of the patients. The involvement of all the other organs including brain, heart, kidney, bone, skeletal muscle, breast, thyroid gland comprises only about 10 % and is listed under unusual localization classification [2-4].

Extrahepatic hydatid cyst is usually secondary to rupture of hepatic hydatid cyst. It is difficult to diagnose extra hepatic echinococcosis as it usually is not suspected. It should be strongly suspected in differential diagnosis of all abdominal cysts especially in an unusual region and non-endemic areas.

**CASE REPORT:**

A fifty-year-old lady presented with a history of abdominal distension associated with dull aching

pain for the last 2 months. There were intermittent episodes of fever associated with fatigue but no history of jaundice, vomiting, bowel habit abnormalities, melena, and cough, hemoptysis or weight loss. He had no past history of any abdominal surgeries. She was having a pet dog for the last one year.

General survey was within normal limits. Abdomen was found to be hugely distended. Local temperature was not raised, so is there an absence of local tenderness. Fluid thrill was found present without shifting dullness. Routine blood parameters (e.g. complete hemogram, electrolytes, and Liver function tests) were found unremarkable. The enzyme-linked immune-absorbent assay (ELISA) for echinococcal antibodies in blood came out positive.

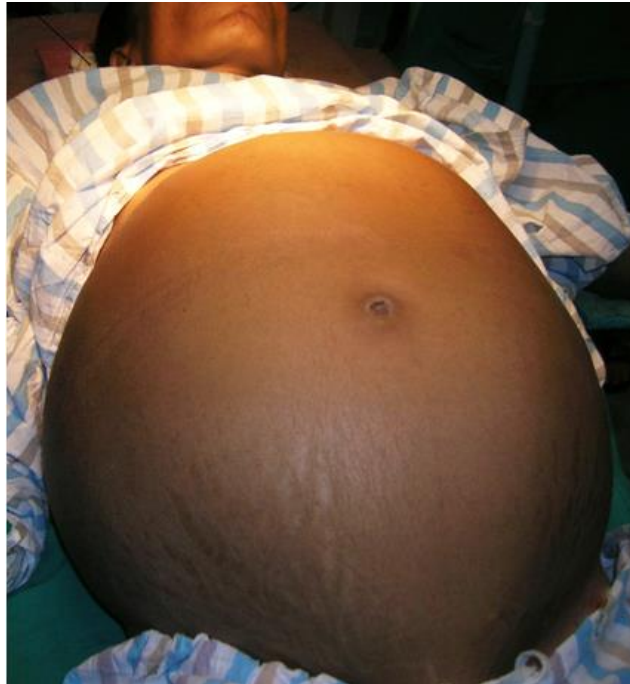Ultrasonography demonstrated an intra-abdominal loculated fluid filled cavity. Contrast enhanced CT scan showed loculated fluid filled cystic swelling occupying whole abdomen up to pelvis. Lungs and liver found normal. In addition, another loculated cyst with intra-cystic debris in left hypochondrium measuring 15 cm x 18 cm was found. Small intestine was found pushed to right.

Patient was adequately prepared. Exploratory laparotomy performed via a midline incision and was immediately followed by pus coming out with membrane. No intestine loops found on evacuation of pus but cavity found communicating posteriorly with other cyst. The cyst was evacuated and membrane with

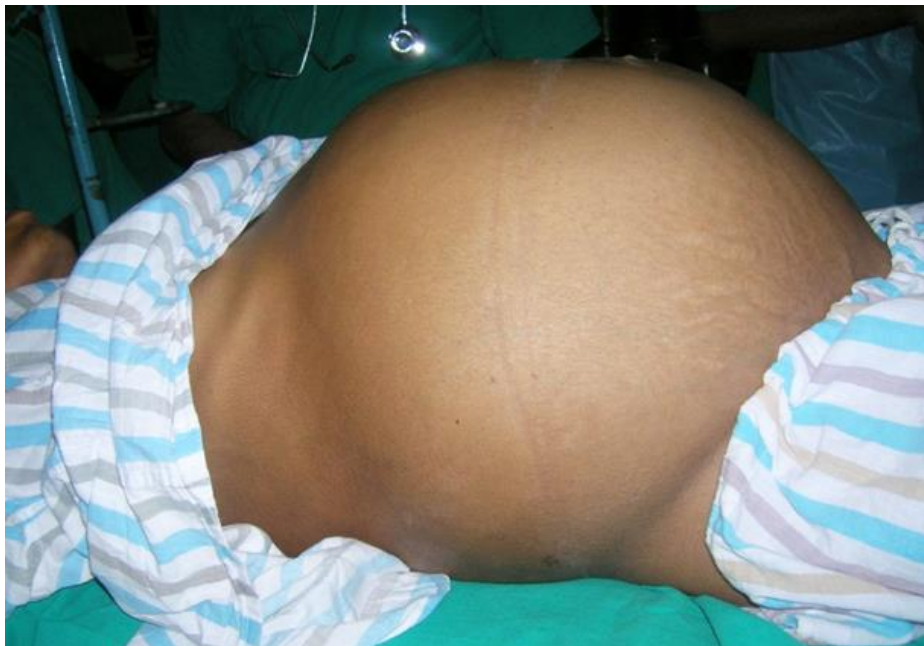fluid found. The cyst was removed surgically by pericystectomy. There was no spillage of cyst fluid into the surrounding areas. The cyst was not found to be arising from any particular organ or anatomical structure. Thorough lavage given by 0.9% saline, hemostasis secured and abdomen closed in layers after placement of an intra-abdominal drain. Her post-operative course was uneventful. Patient was

discharged with 1 month course of Albendazole 400 mg twice daily.

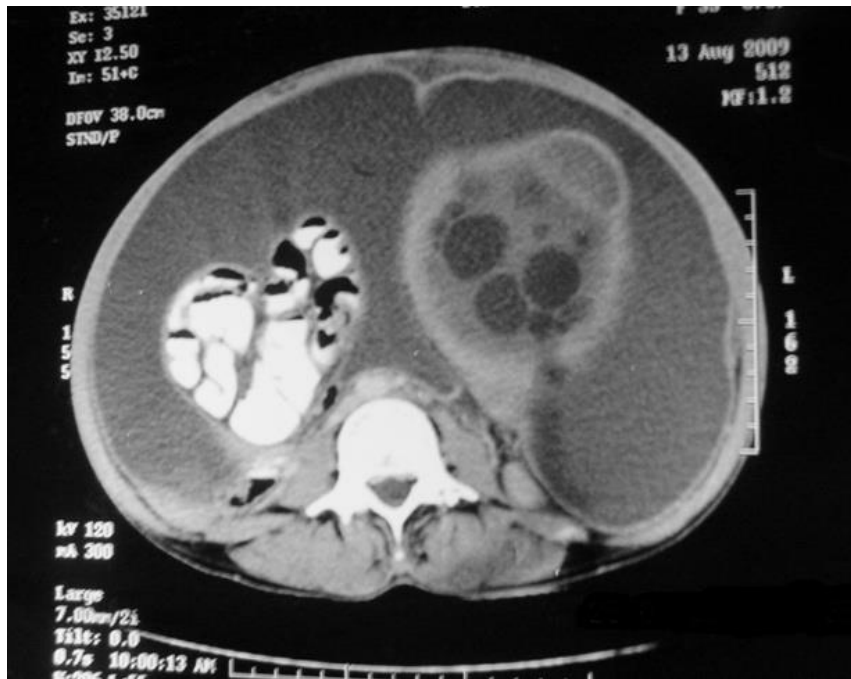Histopathology examination of the membrane and cytology of the aspirated fluid was done and it demonstrated a germinal layer, lamellated ectocyst with fibrous outer layer. Marked foreign body type giant cell reaction was also seen confirming hydatid cyst. No evidence of malignancy was found.



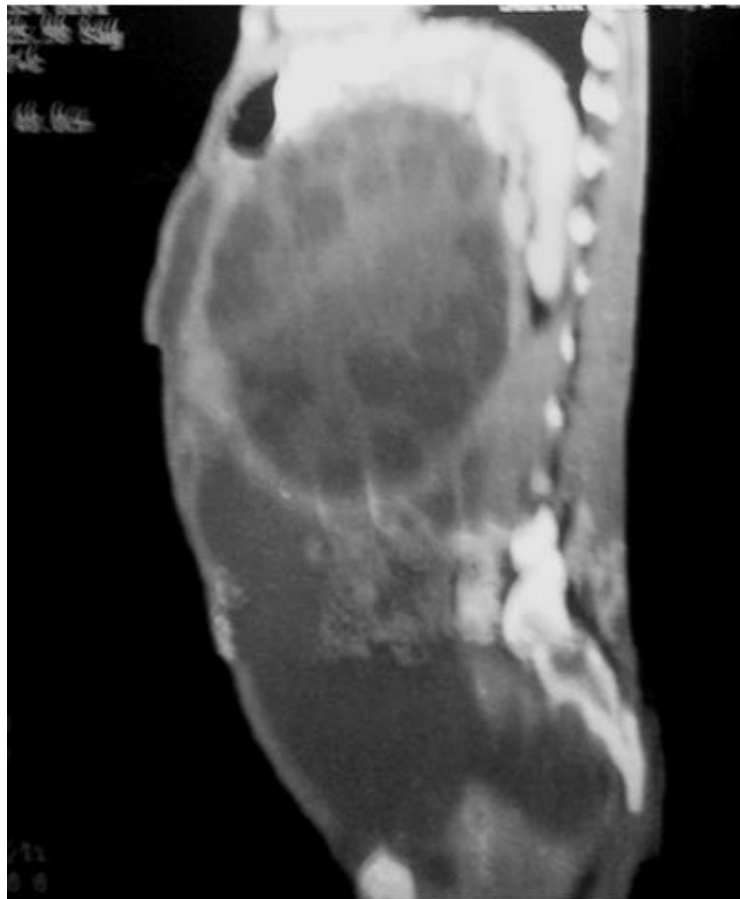
**Fig-1: Supine profile of the patient showing huge abdominal distension.**



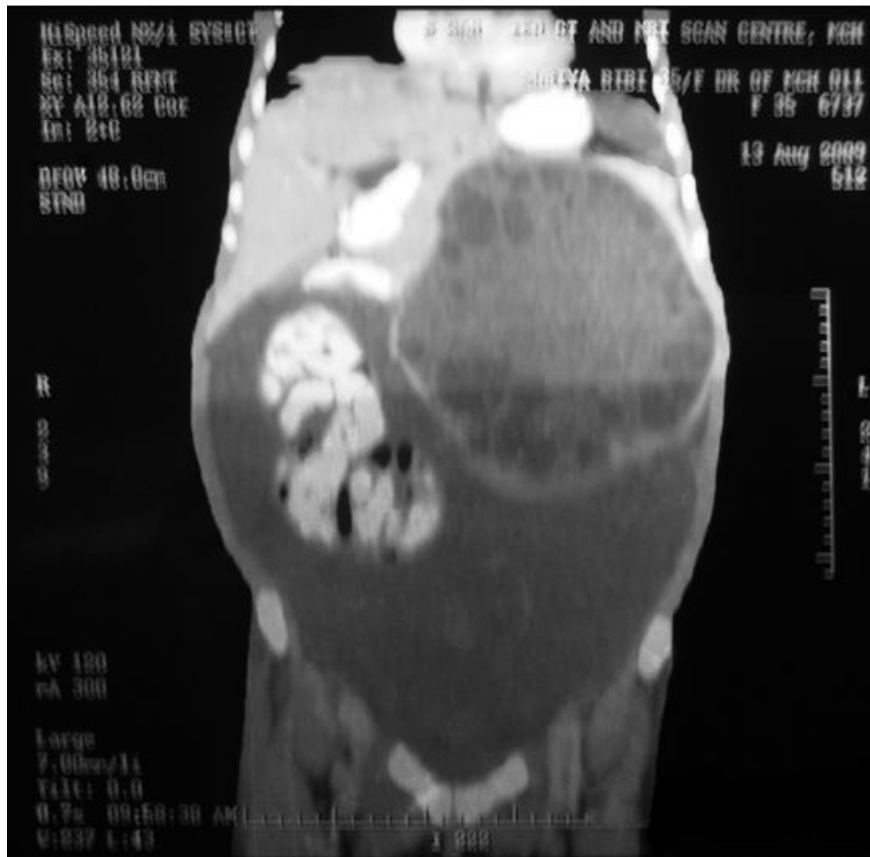**Fig-2: Side profile of the patient showing huge abdominal distension.**



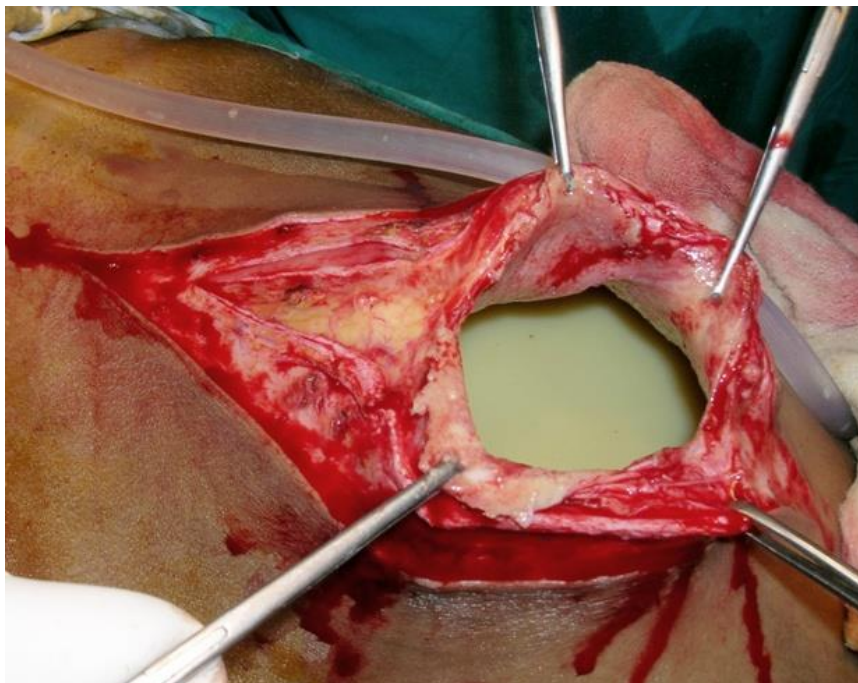
**Fig-3: CECT scan showing fluid filled cystic swelling occupying whole abdomen up to pelvis with another loculated cyst with intra-cystic debris in left hypochondrium. Small intestine found pushed to right.**



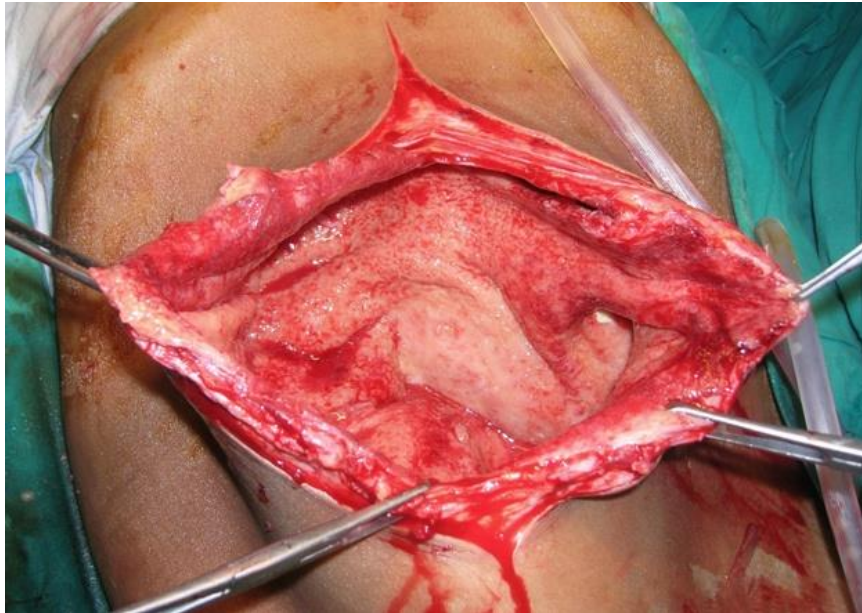
**Fig-4: CECT reconstructed image (Coronal profile) showing loculated cyst with intra-cystic debris in left hypochondrium along with fluid filled cystic swelling occupying whole abdomen up to pelvis.**



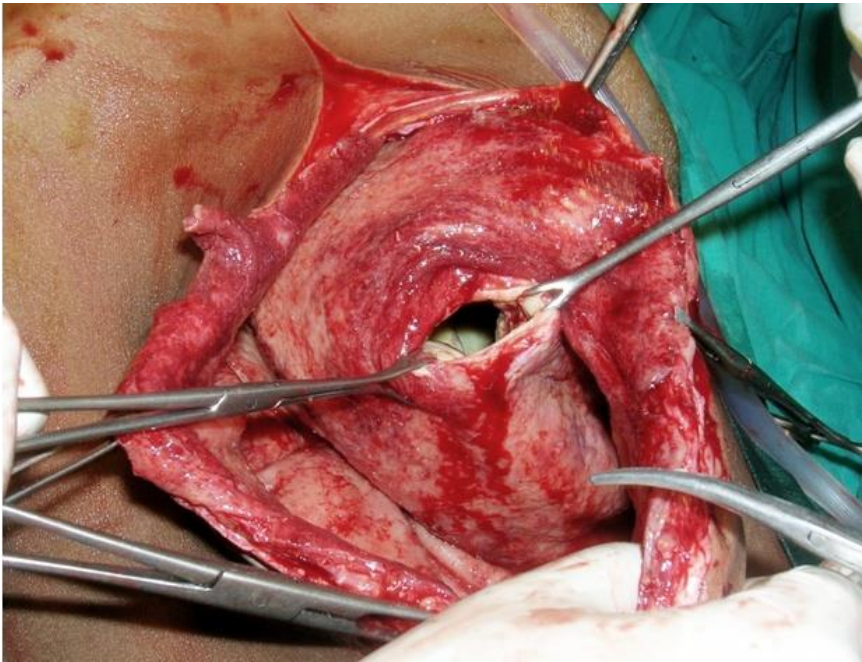
**Fig-5: CECT reconstructed image (Sagittal profile) showing loculated cyst with intra-cystic debris in left hypochondrium along with fluid filled cystic swelling occupying whole abdomen up to pelvis. Small intestine found pushed to right.**



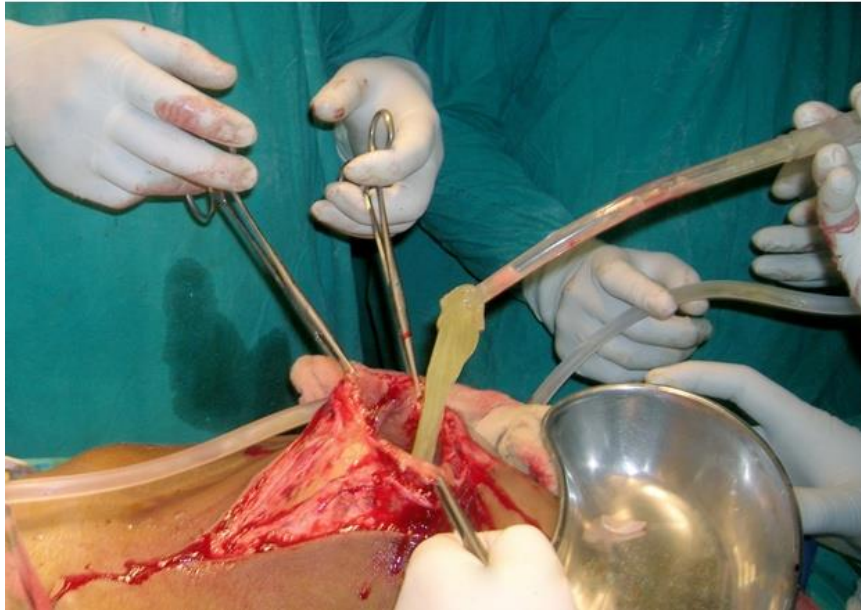
**Fig- 6: Pus seen inside abdomen on exploration.**



**Fig-7: Intra-abdominal cystic swelling seen after aspiration of pus.**



**Fig-8: Intra-abdominal cyst being opened showing pus inside.**



**Fig-9: Membrane being removed from intra-abdominal cyst.**

#### **DISCUSSION:**

Hydatid cyst is caused by the parasite *Echinococcus granulosus* commonly seen in temperate regions. The adult worm resides in Dog or Wolf's intestine (definitive host). Definitive host shed eggs in their stool which contaminate vegetables and fruits. These eggs are then ingested by the cattle or sheep during grazing in the fields. Humans are intermediate and accidental host getting infected by eating contaminated vegetables or fruits. The parasite oncospheres enter the stomach or intestine and start penetrating their wall and reach liver parenchyma through portal circulation. After reaching the liver which acts as a filter for the parasite, larval stage development begins (cyst formation). Some of the oncospheres may bypass liver and reach lungs through systemic circulation and form larval stage there. Hydatid cyst commonly affects liver and lungs [5-7].

The chief objective of outlining this case report was not only to highlight the rarity of a cause one can encounter while dealing with abdominal distension but also to emphasize certain peculiarities in this case which attracts attention. Primary and isolated extra hepatic intra-abdominal hydatid cysts (PIEHC) are rare and only a few sporadic series have been reported [8]. Up to 1.6% cases in various studies have been reported to have peritoneal and pelvic hydatid disease. Peritoneal echinococcosis (13%) is usually secondary (spontaneous or iatrogenic rupture of hepatic, splenic, or mesenteric cysts) [9]. Primary peritoneal echinococcosis is rare. The liver and lungs were found normal in this patient.

Primary peritoneal hydatid cyst masquerading as ovarian, mesenteric, duplication and other intra-

abdominal cysts have been reported. All these patients had evidence of hydatosis in other peritoneal organs [9-12]. A single primary peritoneal hydatid cyst without any hepatic or extra hepatic organ is also a rarity.

Parasitic infestation may also present with asymptomatic rise in the eosinophil counts but it was not seen in our patient. It was apparent from perioperative findings that it was a case of PIEHC which was communicating with another cyst filling entire peritoneal cavity and also has been infected but, surprisingly the patient did not present with characteristic symptoms of complicated hydatid cyst like high fever, features of sepsis etc. This was indeed baffling.

Differential diagnosis of the intra-abdominal cystic lesions includes mesenteric cyst, gastrointestinal duplication cyst, ovarian cysts, cyst adenoma, and lymphangioma. If the cyst is complicated, then the differential diagnosis should also include intra-abdominal abscess, hematoma, and loculated ascites [13]. It is wise to rule out abdominal tuberculosis as it may change the plan.

Ultrasonography of the abdomen is the initial imaging to identify the organ of origin and to characterise the cyst. However, a contrast enhanced computed tomography is always required to confirm the diagnosis as well as to plan the therapy [14]. ELISA can be a good serological test for the confirmation of hydatid cyst with a sensitivity of 95-97%. Prompt treatment of these cysts is recommended as they are prone to complications like rupture, haemorrhage, infection, or torsion [15]. The treatment of choice is principally a careful and complete surgical excision; the

---

partial or subtotal cystectomy can be performed to avoid to adjacent organs injury [15]. In our case, complete cyst removal was possible. Adjuvant therapy with Albendazole is also essential which was used here.

#### CONCLUSION:

This case illustrates that one should not disregard isolated hydatid cyst as a cause of abdominal distension with minimal or uncharacteristic symptoms and any associated history and features suggesting liver or lung involvement. Complete and meticulous surgical removal of the cyst along with adjuvant Albendazole therapy is the mainstay of the treatment. Our case presented with extra hepatic intra-abdominal intercommunicating hydatid cysts filling almost whole of peritoneal cavity and underwent complete pericystectomy with adjuvant Albendazole therapy.

#### REFERENCES:

1. Kern P, Bardonnnet K, Renner E, Auer H, Pawlowski Z, Ammann RW, *et al.*; European echinococcosis registry: human alveolar echinococcosis, Europe, 1982–2000. *Emerg Infect Dis* 2003, 9(3):343–349.
2. Dagtekin A, Koseoglu A, Kara E, Kara bag H, Avci E, *et al.*; Unusual location of hydatid cysts in pediatric patients. *Pediatr Neurosurg* 2009; 45(5): 379-83.
3. Engin G, Acunaş B, Rozanes I, Acunaş G; Hydatid disease with unusual localization. *Eur Radiology* 2000; 10: 1904-1912.
4. Kolligs FT, Gerbes AL, Durr EM, Schauer R, Kessler M, Jelinek T, *et al.*; 52-year-old patient with subcutaneous space-occupying lesion in brain. *Internist (Berl)* 2003, 44–6:740–745.
5. Fazili A, Wani NA, Khan TS, Mir AR; Hydatosis: rare presentations. *JK Practitioner*. 2002; 9:252–253.
6. Khare DK, Bansal R, Chaturvedi J, Dhasmana JP, Guta S; Primary peritoneal echinococcosis masquerading as an ovarian cyst. *Indian J Surg*. 2006; 68:173.
7. Ghafouri A, Nasiri S, Shojaeifar AF, Mobayen MR, Tahamtan M, Nazari M, *et al.*; Isolated primary hydatid disease of omentum; Report of a case and review of the literature. *Iran J Med Sci*. 2010; 35(3):259–261.
8. Makni A, Jouini M, Kacem M, Safta ZB; Extra-hepatic intra-abdominal hydatid cyst: which characteristic, compared to the hepatic location? *Updates in Surgery*, 2013; 65(1): 25-33.
9. Singh RK; A case of disseminated abdominal hydatidosis. *J Assoc Physicians India* 2008, 56:55.
10. Babu KS, Goel D, Prayaga A, Rao IS, Kumar A; Intra abdominally datid cyst: a case report. *Acta Cytol* 2008; 52:464-6.
11. Astarcioglu H, Kocdor MA, Topalak O, Terzi C, Sokmen S, Ozer E; Isolated mesosigmoidal hydatid cyst as an unusual cause of colonic obstruction: Report of a case. *Surg Today* 2001; 31: 920-2.
12. Lim JH; Parasitic diseases in the abdomen: imaging findings. *Abdom Imaging* 2008; 33:130-2.
13. Sekmenli T, Koplay M, Sezgin A; “Isolated omental hydatid cyst: clinical, radiologic, and pathologic findings,” *Journal of Pediatric Surgery*, 2009; 44(5): 1041–1043.
14. Ilica AT, Kocaoglu M, Zeybek N, Guven, S, Adaletli I, Basgul A., *et al.*; “Extrahepatic abdominal hydatid disease caused by *Echinococcus granulosus*: imaging findings,” *American Journal of Roentgenology*, 2007; 189(2): 337–343.
15. Uramatsu M, Saida Y, Nagao J; “Omental cyst: report of a case,” *Surgery Today*, 2001; 31(12): 1104–1106.