

Unusual foreign body in urinary bladder: Report of a case with review of literature

Dipak Kumar Bera¹, Dilip Kumar Pal², Manju Banerjee³

¹Post Doctoral trainee, Department of Urology, Institute of Post Graduate Medical Education & Research, Kolkata-700020

²Professor & Head, Department of Urology, Institute of Post Graduate Medical Education & Research, Kolkata-700020

³Professor, Department of General Surgery, Institute of Post Graduate Medical Education & Research, Kolkata-700020

*Corresponding author

Prof. Dilip Kumar Pal

Email: drdkpal@yahoo.co.in

Abstract: Different types of foreign body have been found in the urinary bladder. Most of these are self-inserted via urethra. The motives for such insertions are difficult to understand. Usually these foreign bodies were inserted as a result of exotic impulses, psychiatric problems, sexual curiosity or sexual perversion. The treatment of foreign bodies is determined by their size, location and shape. In most cases endoscopic removal is ideal, but in some cases where endoscopy is not successful surgical treatment may be necessary. Herein we present one case of self-inserted urinary bladder foreign body.

Keywords: urinary bladder, psychiatric problems, sexual curiosity.

INTRODUCTION:

Foreign bodies in the urinary bladder are not uncommon. Most foreign bodies are inserted out of curiosity, autoerotic stimulation, or medical procedures [1]. A host of foreign bodies have been reported ranging from wire, screw, or ball point pen to animals such as a leech or snake [2,3]. The foreign body can remain asymptomatic for long time. But in most cases the patient presents with pain in the lower abdomen, hematuria, urinary tract infection or obstructive voiding symptoms [4]. The procedure for complete removal of such foreign bodies should be as simple as possible and at the same time should be less traumatic to the urinary tract. In this case report, we present a 22-year-old male patient who inserted a rolled bamboo leaf in an attempt to dilate his urethra because of poor urinary stream.

CASE REPORT:

A 22-year-old male patient presented to the Emergency Department with complaints of pain lower abdomen, burning micturation and terminal hematuria. Previously he had gradually progressive poor flow of urine for the last 3 months. There was no history of psychiatric disorder. According to the patient, he was trying to dilate his urethra with a rolled bamboo leaf in order to improve his poor urinary flow. And while taking the leaf out, a part of it got detached and remained within the urinary bladder.

On clinical examination, external urethral meatus was hyperaemic and the penis as a whole was

slightly tender to deep palpation. Laboratory findings revealed microscopic hematuria and pyuria in routine urine analysis, but the results of the complete blood count and electrolyte profile were normal. Plain X ray KUB was normal. Abdominal Ultrasonogram showed normal kidneys with a long echogenic object found inside the bladder without any acoustic shadow. With the probable diagnosis of foreign body in urinary bladder, we planned for cystoscopic removal.

On cystoscopy urethra was normal. There was a long green leafy structure inside the bladder (Fig.1). With the help of stent removal forceps we removed it which was a 17 cm long rolled out bamboo leaf (Fig.2). The patient was discharged on next day. He was asymptomatic at follow-up and subsequently he was sent for psychiatric counseling.

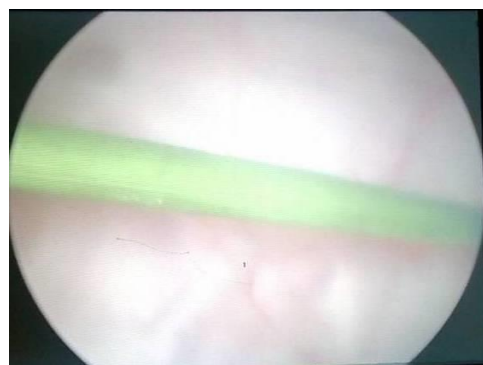

Fig.-1: Cystoscopic view of the intravesical foreign body

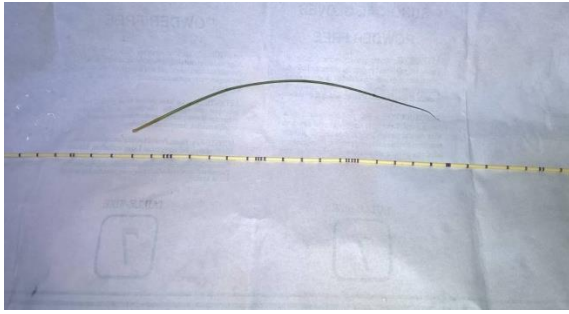


Fig.-2: The 17 inch long bamboo leaf after extraction

DISCUSSION:

Foreign bodies in the genito-urinary tract, though rare but every urologist and practitioner may encounter it in his practise. Causes of foreign bodies in lower urinary tract include psychological, iatrogenic during urological procedure, traumatic aspect and migration from other organs. In psychological aspect, various circumstances including exotic impulse, mental illness, sexual curiosity, and sexual practice while intoxicated and so on make self-insertion of foreign bodies in lower urinary tract. Various materials such as paraffin, a urethral device, metallic cables, plastic tubes, fish, and snake have been reported as foreign bodies in the lower urinary tract [4]. There is a marked male preponderance which may be due to their use of foreign bodies as a masturbatory aid. The clinical presentation is varied-ranging from asymptomatic to lower abdominal pain, swelling of glans or body of penis, dysurea, dyspareunia, hematuria, pyuria, urinary frequency, strangury, urinary retention and fever [5, 6, and 7]. Difficulty in the diagnosis occurs in patients who present late due to embarrassment and invariably follows multiple removal attempts. A plain x-ray or ultrasonography followed by cystoscopy usually sufficient for the diagnosis. Most foreign bodies can be removed transurethrally with cystoscopy. Open removal via suprapubic cystostomy is sometimes needed. After removal, psychiatric referral should be done to prevent repeat presentation with its complication like bladder perforation, abscess and fistula formation.

CONCLUSION

Urinary bladder seems to be an accessible site for the introduction a foreign body. Extraction should be tailored according to the nature of the foreign body and should minimize bladder and urethral trauma. The possibility of an intravesical foreign body should be considered in any patient with chronic unexplained lower urinary tract symptoms.

REFERENCES:

1. Johnin K, Kushima M, Koizumi S, Okada Y; Percutaneous transvesical retrieval of foreign bodies penetrating the urethra. *J Urol* 1999;161:915-6

2. Cho DS, Kim SJ, Choi JB. Foreign bodies in urethra and bladder by implements used during sex behavior. *Korean J Urol* 2003;44:1131-4
3. Van Ophoven A, deKernion JB; Clinical management of foreign bodies of the genitourinary tract. *J Urol* 2000;164:274-87.
4. Ku JH, Lee CS, Jeon YS, Kim ME, Lee NK; A Foreign body in the urethra: a case report. *Korean J Urol* 1997; 38:219-21.
5. Deka PM, Rajeev TP; Unusual cause of hematuria. *Urol Int* 2001; 66:412.
6. Mustafa M; Erosion of intra uterine contraceptive device through the bladder wall causing calculus. *Urol Int* 2009;82: 3701.
7. Singh I; Intravesical CuT emigration: an atypical and infrequent cause of vesical calculi. *Int Urol Nephrol* 2007;39: 4579.