

Recurrent hypoglycaemic coma attack in patient with advanced gastric cancer: a rare occurrence

Adeoti Moses Layi,¹ Akanbi Olusola Olateju,¹ Oguntola Adetunji Saliu,¹ Habeeb Olufemi Gbenga,² Olamoyegun Michael Adeyemi,³ and Kareem Lukuman O.³

¹Surgery Department, Ladoke Akintola University of Technology Teaching Hospital, Ogbomoso, Nigeria

²Surgery Department, University of Ilorin Teaching Hospital Ilorin, Nigeria

³Medicine Department, Ladoke Akintola University of Technology Teaching Hospital, Ogbomoso, Nigeria

*Corresponding author

Akanbi Olusola Olateju

Email: drsolaakanbi@yahoo.com

Abstract: We report a case of 63 year old man, known hypertensive and diabetic patient with advanced gastric cancer, with previous history of stroke. Patient was admitted to our emergency department following hypoglycaemic coma attack, resulting from non islet cell tumour (NICT) recalcitrant hypoglycaemia. At admission the plasma glucose level was 1.1mmol/l. Patient hypoglycaemia failed to respond to intravenous bolus of 1 in 1 dilution of 50% dextrose water and had to be maintained on continuous infusion of 10% dextrose. The patient hypoglycaemia progressively resolved over two weeks following subtotal gastrectomy. This case suggests that hypoglycaemia could be a form of paraneoplastic syndrome associated with gastric cancer.

Keywords: gastric cancer; hypoglycaemia; paraneoplastic, non islet cell tumour.

INTRODUCTION

Hypoglycaemia a low blood sugar is a common acute emergency and complication in a diabetic patient and mostly results from diabetic treatment [1]. Though hypoglycaemia is a well known paraneoplastic syndrome associated with insulinoma, however, occurrence in a non islet cell tumour is a rare occurrence and when it occurs is commonly seen in large slow growing mesenchymal soft tissue sarcoma of the abdomen [2]. Association of hypoglycaemia with gastric cancer is even rarer [3].

CASE REPORT

Our patient was a 63 year old man who routinely attends medical outpatients' clinic of our hospital, as a known hypertensive and diabetic patient with previous history of cerebrovascular accident he suffered three years earlier and recent onset of dyspeptic like symptoms. Further evaluation of the patient was in keeping with clinical diagnosis of acid peptic disease to rule out gastric cancer. Based on the clinical diagnosis, an upper gastrointestinal endoscopy was ordered for, the result of which was in keeping with antropyloric mass with mucosa effacement over the mass (figure 1)

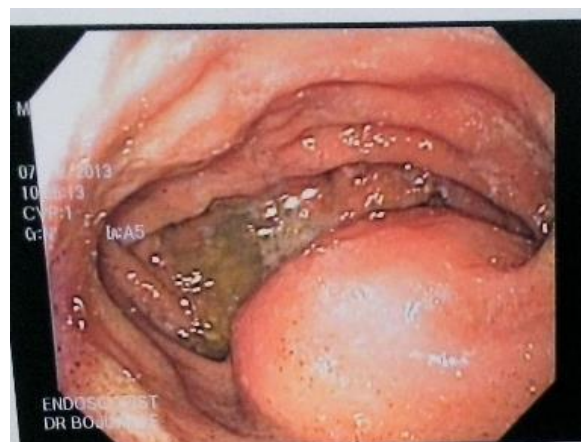

Fig- 1: Showing the endoscopic findings

Other investigations ordered for were Electrocardiographic study which was in keeping with hypertensive heart disease with occasional ectopic beats, Chest X- Ray was in keeping within enlarge cardiac shadow with normal lungs field and bony thorax, a computed axial tomographic scan of the abdomen was in keeping with gastric tumour with neither evidence of intraperitoneal spread nor hepatic metastasis, histology of the multiple gastric antral mucosa biopsy was in keeping with mucinous adenocarcinoma of the stomach and further complete laboratory studies were in keeping with moderate anaemia (haemoglobin of 6g/dl with hypochromic, microcytic red cell), hypoproteinaemia (serum albumin of 2.4 g/dl), while electrolyte pattern

was in keeping with hypokalaemic, hypochloreaemic, metabolic alkalosis with no derangement in liver function test. While patient was being investigated, he was empirically placed on anti h pylori regimen and his routine oral hypoglycaemic agents and anti hypertensive agents for management of his type II Diabetes mellitus and hypertension respectively. He was then referred to surgical outpatients department (SOPD) with results of the investigations. He was admitted via SOPD into our surgical ward based on low packed cell volume and symptomatic anaemia and he was transfused over two days with four unit of partially packed red blood cell and was discharged home seventh day post admission, with packed cell volume of 28% and on routine haematinics excluding folate. All efforts at assessing the insulin level proved abortive.

Four days following discharged from hospital he lost consciousness at home and was re-admitted by medical unit on account of hypoglycaemic coma. At admission he was unconscious and sweating profusely with capillary blood glucose of 1.1mmol/l(one touch ultra test strip) and only regained consciousness after intravenous bolus infusion of 50% dextrose water in double dilution following which the blood sugar rose up to 10 mmol/l and maintained on intra venous fluid with 5% dextrose water 1L to alternate with 0.5l of normal saline, to have a total of 3l of above regimen in 24 hours with oral feed as tolerated. However within ten minutes of commencement of above regimen, patient had another episode of hypoglycaemic coma with sweating and had repeated intravenous infusion of 50 ml of 50% dextrose water. Further systematic enquiry excluded missed meal, recent step up in neither dosage of his oral hypoglycaemic agents nor any known precipitants of hypoglycaemia. Patient had seven episodes of hypoglycaemic attack while on above fluid regimen with high carbohydrate diet and each episode was aborted with intravenous infusion of 50% dextrose water in conjunction with endocrinology unit. In other to avoid these repeated episode of hypoglycaemic attack patient was placed on continuous infusion of 10% dextrose water and complete exclusion of both oral hypoglycaemic agent and insulin while being scheduled for surgery. Figure 2 showing the resected gastric specimen while figure 3 is showing the histology of the tumour.



Fig-2: Showing the gross specimen of the tumour

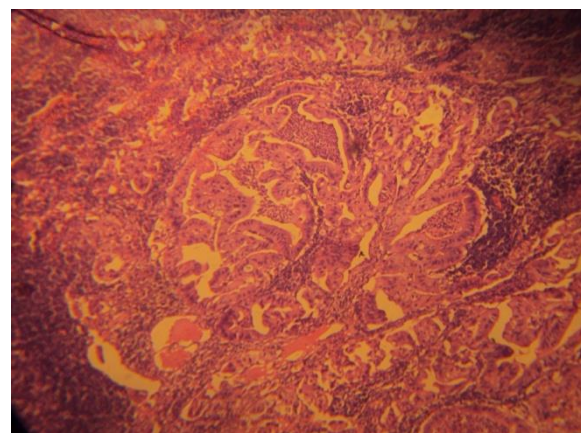


Fig-3: Showing histology of the tumour specimen

Five days following admission to emergency unit, patient had subtotal gastrectomy with billroth II reconstruction, intraoperatively patient was placed on glucose potassium insulin (GKI) regimen and in postoperative period for 72 hours however, postoperative period was uneventful and patient blood sugar became stabilized on subcutaneous insulin. Patient was eventually discharged home on fifteen post operative day to follow up clinic with fasting blood sugar of 5.6mmol/l and on subcutaneous insulin. Patient died one year three months post surgery from progression of the metastatic gastric cancer, without any episode of hypoglycaemic attack.

DISCUSSION

Hypoglycaemia is a well known paraneoplastic syndrome of insulinoma, an islet cell tumour of the pancreas. However, non islet cell tumour hypoglycaemia (NICTH) is a rare occurrence seen commonly in large pleura or abdominal mesenchymal tumour especially with retroperitoneal fibrosarcomas [4]. The exact mechanism of NICTH induced hypoglycaemia is often uncertain. Kahn (1980) has suggested three possible mechanism (1) secretion of insulin or insulin like substance (2) glucose

consumption by tumour cells (3) failure of compensatory mechanism to stimulate glycogenolysis or gluconeogenesis either via destruction of the liver by the tumour or by suppression of the counter regulatory hormonal secretion [5]. In previously 10 published articles reviewed by MacDougall *et al.*; [6]. Hepatic metastasis was uniformly noted in all the cases and often associated with poor prognosis; this is in contrary in our case where no neither radiological nor intraoperative evidence of hepatic metastasis was noted.

He later succumbed to progression of gastric cancer with wide spread hepatic and bone marrow metastasis and died one year three months post operation without episode of hypoglycaemic attack with well controlled blood sugar and blood pressure on oral drugs.

The exact mechanism could not be clearly justified in other previously reported cases; however, secretion of insulin or insulin like substance as suggested by Kahn seems to be the most likely probable mechanism [7]. This may also explain the mechanism in our patient as no evidence of hepatic involvement or the tumour larger than other previously excised tumour without similar symptom.

Management of tumour induced hypoglycaemia can be challenging and rarely effective [6]. Though some success has been met with use of diazoxide a potent inhibitor of insulin secretion [8]. Others have tried use of steroid with minimal success and most often than not patients will still require a continuous intravenous infusion of glucose containing solution as seen in our case presentation. Resectional surgery may be of benefit in those groups of patients who can withstand surgery thus preventing continuous intravenous administration of glucose and hospitalisation with attendant risk of nosocomial infection in patients who are probably immunocompromised.

CONCLUSION

Hypoglycaemia as a paraneoplastic syndrome is uncommon in gastric adenocarcinoma; hence intractable hypoglycaemia in patients with recent onset of dyspepsia should raise some suspicion of malignancy as surgery may just be the only cure.

REFERENCES

1. Guvan M, Bayram F, Guven K, Kelestimur F; Evaluation of patient admitted with hypoglycaemia to a teaching hospital in central Anatolia. *Postgrad Med J*, 2000; 76:150-152.
2. Hizuka N, Fukuda I, Takano K, Okubo Y, Asakawa-Yasumoto K, Demura H; Serum insulin like growth factor II in 44 patients

- with non islet cell tumour hypoglycaemia. *Endocr J*, 1998; 45 (supp): S61-S65.
3. Horiuchi T, Shinohara Y, Sakamoto Y, Watabe T, Mokuda O, Tanaka K *et al.*; Expression of insulin like growth factor II by a gastric carcinoma associated hypoglycaemia. *Virchows Archiv*, 1994; 424(4): 449-452.
4. Daughaday WH; Hypoglycaemia in patient with non islet cell tumour. *Endocrinol Metab Clin North Am*, 1989; 18: 91-101.
5. Kahn CR; The riddle of tumour hypoglycaemia revisited. *Clinics in Endocrinology and Metabolism*, 1980; 9:335.
6. Macdougall IC, Flemming S, Frier BM; Hypoglycaemic coma associated with gastric carcinoma. *Postgrad M J*, 1986; 62: 761-764.
7. Kato A, Bando E, Shinozaki S, Yonemura Y, Aiba M, Fukuda I *et al.*; Severe hypoglycaemia and hypokalaemia in association with liver metastases of gastric cancer. *Intern Med*, 2004; 43(9): 824-828.
8. Le roith D; Tumour induced hypoglycaemia. *N Eng J Med*, 1999; 341: 757-758.