

Multiple foreign bodies in GI Tract: A Case Report and Review of Literature

Dr Sumit Shukla¹, Dr Ankur Maheshwari², Dr Siddharth Dubey³

Dept. of Surgery, MGM Medical College & MY Hospital, Indore (M.P.) 452001.

*Corresponding author

Dr. Siddharth Dubey

Email: siddharthdube0905@gmail.com

Abstract: Deliberate ingestion of single foreign body is a common scenario seen by gastroenterologists in psychiatric units and prisons. However, multiple foreign body ingestions, especially located in the stomach, provide the surgeon with challenges for management and treatment. Although most foreign objects pass spontaneously, one should have a low threshold of intervention for multiple objects, especially those that are wide, sharp and at risk of perforation. Diagnosis is typically made when there is a history of ingestion along with corresponding radiographic verification. We present a case of a 40 year-old man with c/o pain in abdomen and ingestion of multiple foreign bodies. Radiological findings (X-Ray and CT scan) showed multiple foreign bodies in stomach. Exploratory laparotomy with gastrotomy with removal of foreign bodies was done.

Keywords: Foreign body; Ingestion; Gastrointestinal tract; Emergency.

INTRODUCTION

Cases related to gastrointestinal foreign bodies are relatively common causes of admission to emergency departments. The ingestion of a foreign body into the gastrointestinal (GI) tract can be a clinically serious condition. Although this problem can be countered in every age group, almost 80% of cases comprise patients in early childhood (18-48 mo), with a majority of cases resulting from swallowing coins, toys, crayons, or pen caps [1,2]. The ingestion of foreign bodies is rarely seen in adults, is generally accidental and is commonly seen in the form of food (meat and bones) ingestion. Other risk groups for this type of injury include patients with psychiatric disorders, adults without teeth, prisoners and patients under the influence of substances that obscure judgment. The clinical presentation, symptoms and management of foreign bodies depend on their location within the GI tract. Depending on the size and shape, almost 80%-90% of such foreign bodies pass freely from the GI tract without any complication [3-5].

CASE HISTORY

A 40 year old male presented in our emergency department with a pain in abdomen and fever since 7 days. The patient was prisoner and referred from Central Jail. The patient gave the history of ingestion of multiple foreign bodies. There was no history of trauma, vomiting, alteration of bowel habits. There was no history of any psychiatric illness. On clinical examination revealed diffuse tenderness over abdomen with no guarding or rigidity. Patient was passing flatus. On ultrasonography it was found to be

multiple foreign bodies in stomach with rest of the bowel loops normal in caliber with normal peristalsis. Plain abdominal radiograph was obtained which showed multiple radio-opaque shadows. The patient was put to Computed Tomography of abdomen resulting in multiple foreign bodies in stomach and first part of duodenum.

Exploratory laparotomy with gastrotomy and extraction of foreign body was done. The decision of open surgical intervention was based on the fact that there were multiple foreign bodies with size more than 6 cm, some of them were with sharp edges on radiograph. In all total of 16 foreign bodies were extracted which included nails, blades, spanner, pins, wood pieces, pen and polythene bag. The gastrotomy was repaired in double layer with bilateral drain placement. The patient was kept nil per oral for 72 hours and then gradually started on oral intake. Ryle's tube was kept in situ for initial 48 hrs. The drains were removed on 5 and 7 post-operative days. The suture removal was done on 9 day. Patient is doing well at follow up of six weeks with psychiatric evaluation.

DISCUSSION

In the cases of foreign body ingestion the history given by the patient is the mainstay of diagnosis. Further evaluation may include sonography, radiographic findings that include X-ray or CT scan. Therefore, the planning of the diagnostic work-up and the extent and urgency of a possible intervention are decided according to the information provided by the patient regarding the type of foreign body ingested,

together with the clinical complaints and physical examination. Mostly the foreign body ingestions in paediatric population are conservatively managed. They pass the GI Tract without any harm. The incidence of foreign body ingestion is more in paediatric patients aged between 6 mo and 6 years. GI foreign body exposure tends to be accidental in adults, with food particles and bones constituting the majority of the foreign bodies. The rest of the cases occur in the setting of facilitating factors, such as adults without teeth or with dental plates, prisoners and psychiatric patients. Patients who suffer foreign body ingestion can present with a wide range of symptoms, which can vary based on the physical characteristics and the content that is absorbed in the GI tract [1,4,5].

In the emergency or accidental cases the diagnosis is based on the patient's history and complaints, which typically include the sudden onset of difficulty of swallowing during eating, chest pain, odynophagia or insufficiency in tolerating secretions. However, symptoms range from mild to life threatening, including shortness of breath, abdominal pain, vomiting, hematemesis, foreign body sensation, coughing and chest pain depending on the site of obstruction and type of foreign body. In various studies the different types of foreign bodies are observed in the GI tract based on the age group. During childhood, swallowed coins, small toys, crayons or batteries are

observed, whereas during adulthood, food, bones and dental-related foreign bodies are more common. The types of foreign bodies may also differ by country. The high number of pin ingestions is thought to be related to the regional dress code, which results in women holding pins between their lips before attaching their headscarves. While certain conditions, such as parental attitudes and dietary habits, can provide clues for the types of foreign bodies that are ingested, prevention strategies are also dependent on various cultural, social religious and economic factors

The management also varies, depending on the anatomical region where the foreign body is located. Determining the type and location of the foreign body changes the treatment approach

The majority of the radiopaque foreign bodies in the GI tract can be detected using radiography [6-8]. This simple modality provides crucial information, such as the number, size, location and direction of the foreign body, as well as the presence of sharp edges. However, the presence of fish bones, chicken bones, glass, wood and thin metals cannot be ruled out by plain radiographies. Neck, chest and abdominal radiographies are able to show perforations as well as metal objects and bones [9-10]. In our case also abdominal radiograph was done.

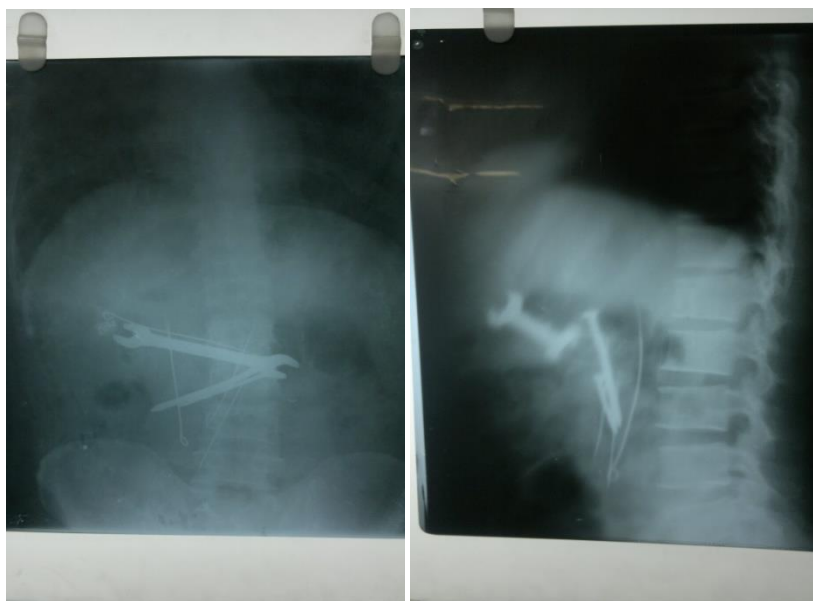


Fig-1 & 2: Plain abdominal radiograph with radio-opaque shadows.

Computed tomography (CT) is especially useful when radiolucent materials cannot be detected with plain X-rays. Also a contrast enhanced CT with 3D reconstruction not only provides information regarding

foreign body but can be useful in determining, treatment options and complications [11]. The CT scan of our patient showed multiple foreign bodies in the stomach and duodenum.

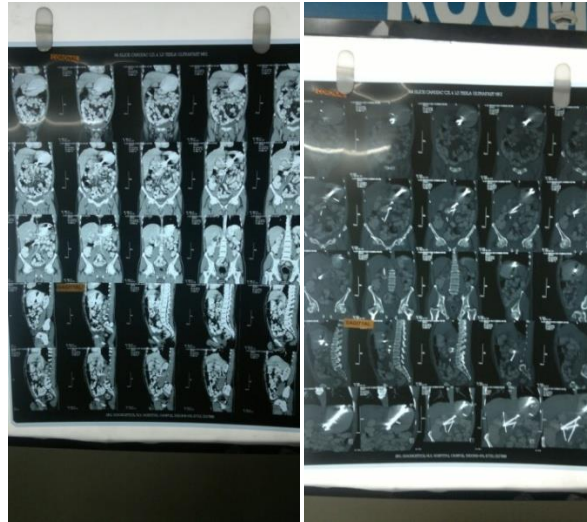

Fig-3 & 4: CT scan of the patients showing multiple foreign bodies.

However mostly foreign bodies in the GI tract are typically treated conservatively, based on the type of foreign body and the patient's clinical condition. Between 80% and 90% of foreign bodies pass through the GI tract freely, while 10% to 20% require an endoscopic intervention, and 1% require surgery. Single foreign body are mostly passed without any complications [12].

Surgeon should determine if and when an intervention is needed. The patient management strategies depend on a patient's age and clinical condition, the type and size of the foreign body, the presence of sharp edges, the anatomical location and the endoscopic capability of the treating unit. In general, foreign bodies larger than 2.5 cm in diameter cannot pass the pylorus, while objects longer than 6 cm cannot pass the duodenal curve [6,7]. Therefore, these objects require endoscopic removal. Endoscopic intervention is also indicated if the patient's condition is not stable or if the foreign body is impacted or presents risks of further damage to the patient [8,9]. An emergent endoscopic removal should be performed in patients with oesophageal obstruction (*e.g.*, cannot swallow

secretions), and those who have swallowed pointed objects. However, endoscopic removal is contraindicated if the foreign body is above the upper oesophageal sphincter or if there is clinical or radiological evidence of perforation (13). Conditions such as acute abdomen due to intestinal perforations are seen in nearly 1% of patients who have ingested foreign bodies [6,9]. This condition can lead to severe complications and even death. The most common complication of foreign body ingestion is perforation of the viscera and more so ever the ingestion of a sharp and pointed object is more likely to cause perforations. Approximately 30%-35% of such objects can penetrate the GI tract, requiring urgent laparotomy. Also in the presence of complications or in the case of unsuccessful endoscopic interventions, emergency surgery is preferred [14]. The majority of foreign bodies pass through the GI tract freely, without any complication, and only a small percentage of these cases require interventions [1, 5, 9, 15]. In our case there were multiple foreign bodies. The decision of open laparotomy was taken as per the size of foreign body also some were pointed and sharp which could damage the viscera.

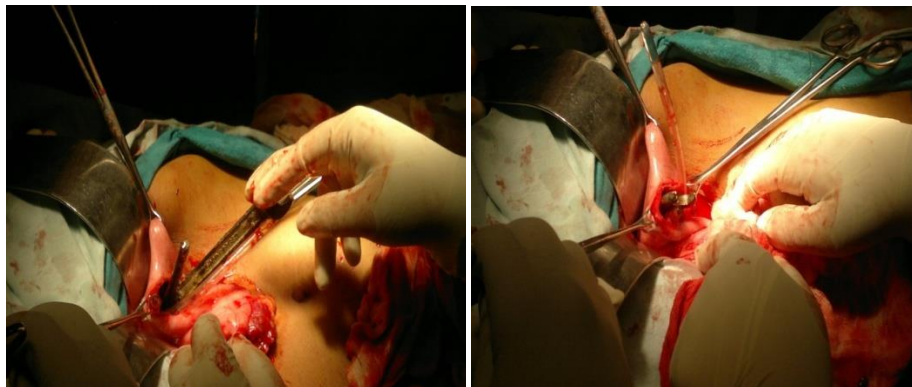


Fig- 5 & 6: Intra-operative images showing extraction of foreign bodies.

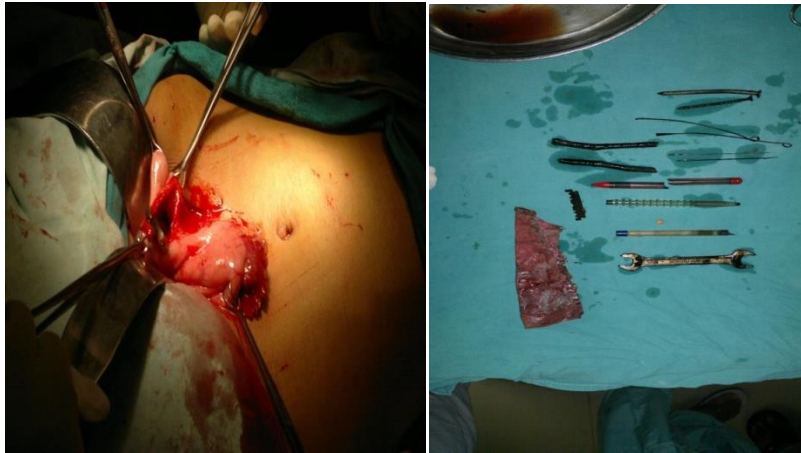

Fig-7 & 8:

Indications for operation:

1. Size of foreign body and failure to show radiographic signs of passage.
2. Acute abdomen with frank peritonitis.
3. Peritonitis.
4. GI bleed.
5. Perforated esophagus (Secondary to intervention).
(Primary to foreign body).

CONCLUSION

Finally in the conclusion majority of the foreign body in the GI tract are managed conservatively, however based on the type of foreign body and the patient’s clinical condition the management may vary. Between 80% and 90% of foreign bodies pass through the GI tract freely, while 10% to 20% require an endoscopic intervention, and 1% require surgery. The patient management strategies depend on a patient’s age and clinical condition, the type and size of the foreign body, the presence of sharp edges, the anatomical location and the capability of the treating unit.

In our case the foreign bodies were multiple, larger (>6cm), penetrating and were lodged in duodenum with no signs of passage, and patient developed signs of peritonitis. So surgical intervention was the modality of choice in such case.

REFERENCES

1. Erbil B, Karaca MA, Aslaner MA, İbrahimov Z, Kunt MM, Akpınar E, Özmen MM; Emergency admissions due to swallowed foreign bodies in adults. *World journal of gastroenterology: WJG*, 2013; 19(38):6447.
2. McCaense DE, Kurchin A, Hinshaw JR; Gastrointestinal foreign bodies. *Am J Surg*, 1981; 142: 335-337.

3. Ashby BS, Hunter-Craig ID; Foreign body perforations of the gut. *Br J Surg*, 1967; 54: 382-384.
4. Carp L. Foreign bodies in the intestines. *Ann Surg*, 1927; 85: 575-591.
5. Schleifer D, Azarbayedjan K, Tabrizi FN; Langenbecks. *Arch Chir*, 1980; 350:165-168.
6. Schwartz JT, Graham DY; Toothpick perforation of the intestines. *Ann Surg*, 1977; 185:64-66
7. Macmanus JE; Perforations of the intestine by ingested foreign bodies. *Am J Surg (new series)*, 1941; 111:393-402.
8. Maglinte DDT, Taylor SD, Ng AC; Gastrointestinal perforation by chicken bones. *Radiology*, 1979; 130:597-599
9. James AH, Allen-Mersh TG; Recognition and management of patients who repeatedly swallow foreign bodies. *J Royal Soc Med*, 1982; 75:107-110.
10. Hashmonai M, Kaufman T, Schramer A; Silent perforations of the stomach and duodenum by needles. *Arch Surg*, 1978; 113:1406-1409.
11. Lee JH, Kim HC, Yang DM, Kim SW, Jin W, Park SJ, Kim HJ; What is the role of plain radiography in patients with foreign bodies in the gastrointestinal tract? *Clin Imaging*, 2012; 36:447-454.
12. Ayantunde AA, Oke T; A review of gastrointestinal foreign bodies. *Int J ClinPract*, 2006; 60:735-739.
13. Ambe P, Weber SA, Schauer M, Knoefel WT; Swallowed foreign bodies in adults. *Dtsch Arztebl Int*, 2012;109: 869-875.
14. Lyons MF, Tsuchida AM; Foreign bodies of the gastrointestinal tract. *Med Clin North Am*, 1993;77:1101-1114
15. Palta R, Sahota A, Bemarki A, Salama P, Simpson N, Laine L; Foreign-body ingestion: characteristics and outcomes in a lower socioeconomic population with predominantly intentional ingestion. *Gastrointest Endosc*, 2009; 69:426-433.