

## **Isolated Adrenal Gland Adenoma Hematoma Associated with Blunt Abdomen Trauma**

**Dr. Mehmet Fatih EKİCİ<sup>1</sup>, Dr. Murat SEYİT<sup>2</sup>, Dr. Fatma CAN<sup>3</sup>, Dr. Sezgin ZEREN<sup>1</sup>, Dr. Zülfü BAYHAN<sup>1</sup>**

<sup>1</sup>Department of General Surgery, Kutahya Evliya Celebi Training and Research Hospital, Dumlupınar University, Kutahya, Turkey

<sup>2</sup>Department of Emergency Medicine, Kutahya Evliya Celebi Training and Research Hospital, Dumlupınar University, Kutahya, Turkey

<sup>3</sup>Department of Radiology, Kutahya Evliya Celebi Training and Research Hospital, Dumlupınar University, Kutahya, Turkey

### **\*Corresponding author**

Dr. Mehmet Fatih EKİCİ

**Email:** [mfatihkici@gmail.com](mailto:mfatihkici@gmail.com)

---

**Abstract:** Isolated adrenal gland adenoma hematomas are rare. We reported a case who was 45 years-old admitted to Emergency Service after a traffic accident and had an adrenal gland adenoma hematomas.

**Keywords:** adrenal gland adenoma, hematoma, trauma, general surgery.

---

### **INTRODUCTION**

Adrenal gland injuries are rarely associated with motorised vehicle accidents, sport injuries and falling [1-2]. Adrenal gland injuries occur at 2% rate among organ injuries associated with trauma. Isolated adrenal gland injuries are more rare [1,3]. Unilateral adrenal gland injuries have good clinical prognosis and medical treatments and follow ups are usually enough [3]. In this paper we want to report a case of isolated adrenal gland adenoma hematoma associated with a traffic accident.

### **CASE REPORT**

45 year-old patient admitted to Emergency Service (E.S.) after a traffic accident. He was generally well and conscious. He had upper right abdomen pain and lumbar pain. He had costovertebral angle tenderness in his right side, pain and voluntary abdominal guarding on his upper right abdomen. His bowel sounds and laboratory findings were normal.

Patient was hospitalised by general surgery. His physical and blood count findings didn't get any worse in his follow up. Intravenous contrast Computed Tomography (CT) scan showed a 33x23 mm solid lesion in right adrenal gland area and linear density increases in fat tissue corresponding with haemorrhage associated with trauma. There were no other traumatic lesions in other organs and bone structures. Lesion density was measured 95 Hounsfield unit (HU) and magnetic resonance imaging (MRI) was performed to eliminate haemorrhage of adrenal gland adenoma. Lesion was isointense on T1 and hyperintense on T2

and showed posterior signal loss in-out of phase MRI images because of fat tissue. There was no signal loss because of haemorrhage on anterior part. Patient was hospitalized for 5 days and his prognosis was fine. 8 weeks after discharge his ultrasound showed a 17x25 mm solid, hypoechoic lesion corresponding with adrenal gland adenoma. Patient had CT scan because of nephrolithiasis 6 months later and decrease in his right adrenal gland size and 25x12 mm adenoma was detected.

### **DISCUSSION**

Adrenal glands have good perfusion. They are located in perirenal space, in gerato fascia surrounded by fat tissue. At 60% rate right adrenal gland is effected during injuries [4]. Adrenal gland injuries are usually with other organ or skeletal system injuries. Isolated adrenal gland injuries are very rare [1,3]. It may not be noticed in first evaluation in E.S. [5]. Injury usually limits itself and patient rarely need intensive care. Non specific symptoms like pain, abdominal guarding and tenderness can be found and there is no specific laboratory finding leading to diagnosis [2].

Non specific adrenal adenomas are the most common adrenal gland tumors. Most of them are not functional [7]. Feocromocitoma, hamartoma, ganglioneuroma, myelolipoma, neurofibroma and metastasis are other common adrenal gland tumors [7].

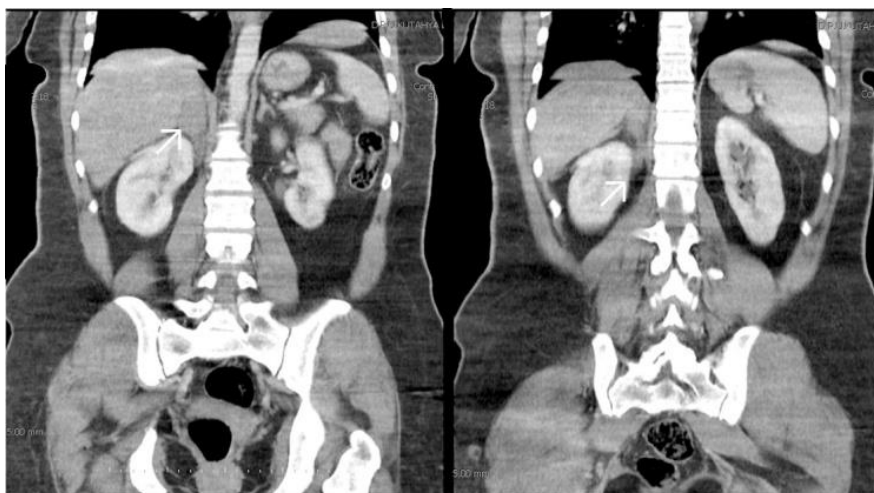
Isolated adrenal gland hematoma is detected at 4% rate in all adrenal gland injuries [3]. Injury in hepatorenal and splenorenal fossa can be diagnosed

with ultrasound performed in E.S. Acute adrenal hemorrhage can be seen mildly hyperechoic and subacute haemorrhage hypo or anechoic in ultrasound[3]. Contrast CT scan is the best radiological method leading to diagnosis. Round shaped sign of hematoma, deleted gland contours because of haemorrhage, increased gland size, adrenal tumor and perirenal bleeding can be detected[5,6]. Ultrasound is reported to be cheapest and easier method on follow ups [2-3]. Its also reported that adrenal hematomas can be confused with haemangiomas [8].

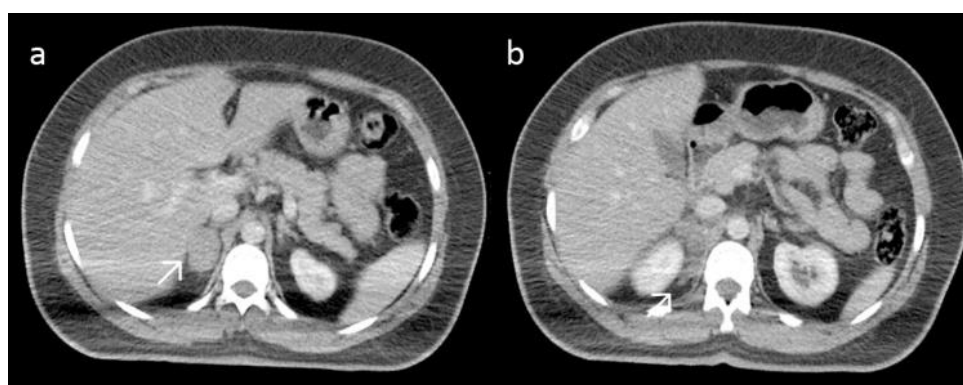
Bleeding, serious adrenal failure, vomiting, mental status changes, hypo or hypertension attacks can be seen in bilateral adrenal injuries [5]. Isolated single sided injuries cause non specific upper abdomen pain. Tenderness on injury side and a mass can be palpated in large hematomas [1-4]. Hyponatremia, hyperpottasemia, acidosis can be detected on bilateral

adrenal gland injuries. All findings are unspecific on unilateral injuries. Anemia is rarely detected on huge haemorrhages[2]. Adrenocorticotrophic hormone (ACTH) stimulation tests, hormone level measurements or cortisone replacement is not recommended [2].

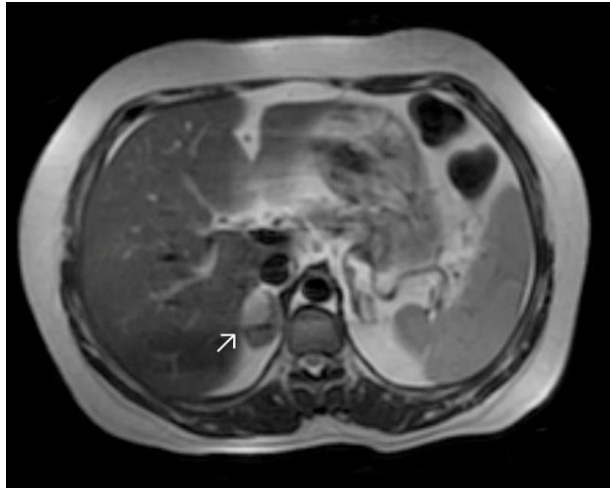
Pain management and restriction of intraabdominal pressure increasing activities is recommended in self limiting injuries[1]. Transarterial embolization can be used in rare occasions to stop bleeding [1]. Blood transfusions are usually not necessary [2]. In our case we diagnosed a hematoma in adrenal adenoma of a patient who had upper right abdomen pain after a car accident using CT scan. His physical examination was normal except upper abdomen tenderness. Self-limiting hematoma was checked by ultrasound periodically. He didn't have any complications and his follow ups were normal after discharge.



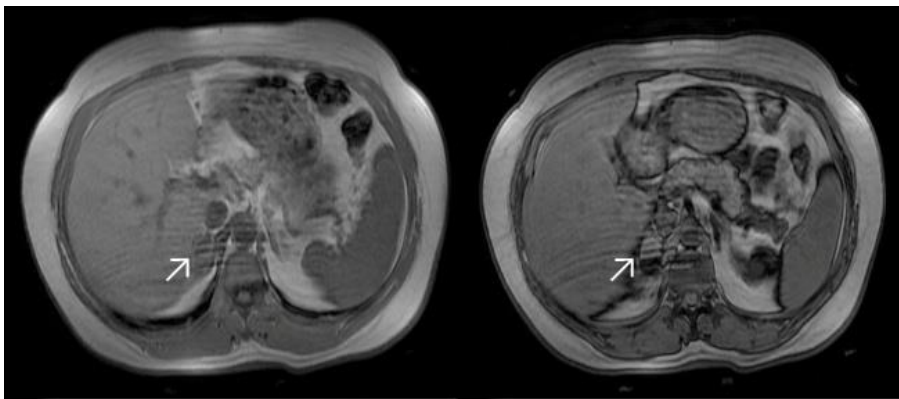
**Fig-1: Increased size of right adrenal gland because of haemorrhage and increase density in adjacent fat tissue on contrast CT images**



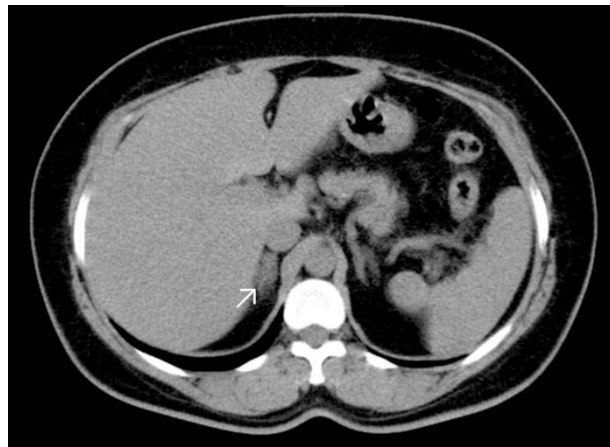
**Fig-2: Axial contrast CT scan images: a)increased size in right adrenal gland because of haemorrhage (b)increased density in adjacent fat tissue**



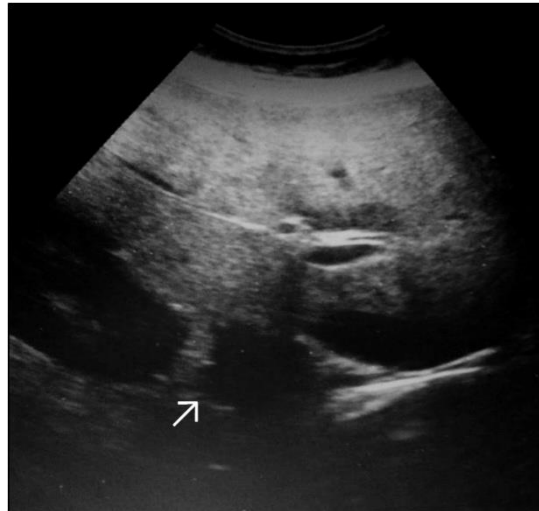**Fig-3: Increased signal on T2 images because of adenoma heamorrhage on the right adrenal gland**



**Fig-4: There is no supression on T1a images in heamorrhage are. Supression of inferior area corresponding with fat tissue of adenoma can be seen on images**



**Fig-5: Decrease in adrenal gland size and adenoma can be seen on axial CT scan of same patient 8 months after injury**



**Fig-6: Acute adrenal hemorrhage can be seen mildly in ultrasound**

### CONCLUSION

Isolated adrenal hematomas are rare and can be detected using emergency ultrasound in trauma patients. CT scan is golden standard in diagnosis. Conservative treatment and follow up is usually enough for management.

### REFERENCES

1. Lin YH, Wu T; Isolated adrenal hemorrhage after blunt trauma. Case report and literature review. *Urological science*, 2013; 24:27-29
2. Roupakias S, Papoutsakis MI, Tsikopoulos G; Adrenal injuries following blunt abdominal trauma in children: report of two cases. *Turkish Journal of trauma and emergency surgery*, 2012; 18(2):171-74
3. Huang YC, Lee WJ, Lin HJ, Yang PJ; Isolated post-traumatic adrenal hematoma: detection by bedside ultrasound in the emergency department. *The journal of emergency medicine*, 2012; 42: 117-18
4. Ushita H, Johnin K, Koizumi S, Kadowaki T, Masada T, Okada Y; Subacute adrenal hemorrhage by blunt abdominal contusion during snow boarding. *Journal of shiga university of medical science*, 2008; 21(1) :1-3
5. Chen K, Lin T, Foo N, Lin HJ, Guo HR; Traumatic adrenal hematoma: A condition rarely recognised in the emergency department. *Injury international journal*, 2007;38:584-87
6. Sinelnikov AO, Abujudeh H, Chan D, Novelline RA; CT manifestations of adrenal trauma: experience with 73 cases. *Emerg Radiol*, 2007;13:313-318
7. Babinska A, Peksa R, Swiatkowska-Rastodulska R, Sworzczak, K; The collection of five interesting cases of adrenal tumors from one medical center. *World J. Surgical Oncology*, 2014;12:377
8. Ishigami K., Stolpen AH., Sato Y, Dahmouh L, Winfield HN, Fajardo LL; Adrenal adenoma with organizing hematoma: diagnostic dilemma at MRI. *Magnetic Resonance Imaging*, 2004;22(8):1157-59