

## Adenosquamous carcinoma of lung: A case of stormy course –A Case Report

V. Sikri<sup>1</sup>, J.S. Sekhon<sup>2</sup>, V. Singhal<sup>3</sup>, A. Gupta<sup>1</sup>

<sup>1</sup>Department of Pulmonary Medicine, <sup>2</sup>Department of Oncology, <sup>3</sup>Department of Critical Care, Fortis Hospital, Ludhiana – 141010, India

### \*Corresponding author

Dr. Vikas Sikri

**Email:** [vikassikri19@yahoo.com](mailto:vikassikri19@yahoo.com)

---

**Abstract:** Adenosquamous carcinoma is a less common subtype of non small cell (NSCLC). It's a relatively rare variety of NSCLC. The clinical presentation is similar to other common variants (Adenocarcinoma and squamous carcinoma). Resection of the primary tumor with curative intent is the mainstay of treatment in early malignancy. However, since most cases of lung cancer present at later stage of disease, medical management, with chemotherapy and/or radiotherapy is the only option available at the time of diagnosis. The overall prognosis is poor in patients with adenosquamous variant vis a vis adenocarcinoma or squamous variety.

**Keywords:** Adenosquamous, Immunohistochemistry, Non Small Cell Lung Cancer.

---

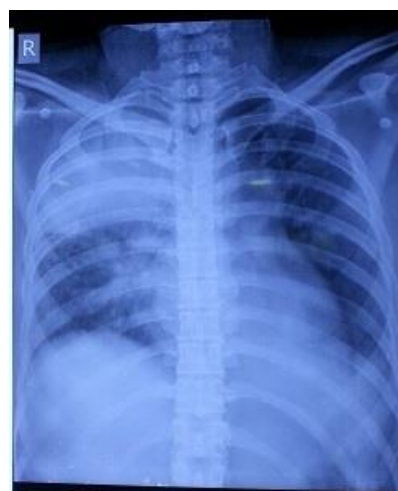### INTRODUCTION

Lung cancer is now being more and more frequently diagnosed with advent of newer diagnostic modalities. Despite recent advances, early detection still remains a challenge. Though the classification of lung cancer into non small cell (NSCLC) and small cell (SCLC) helps in planning initial management, with the availability of targeted therapy sub classification of NSCLC becomes necessary for optimal treatment. In NSCLC group, adenocarcinoma and squamous cell carcinoma forms the bulk of cases and adenosquamous (ASC) variety is rarer and less extensively documented and studied. Here we report a case of young female diagnosed with adenosquamous lung cancer.

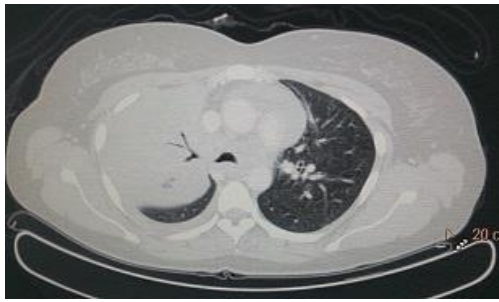
### CASE REPORT

A case of 35 year old female, apparently well 20 days prior to admission when she developed cough and breathing difficulty. There was no fever, chest pain, hemoptysis, decrease in appetite or weight loss. She consulted her doctor and took course of antibiotics but her condition did not improve. Chest X ray was done which showed right upper zone homogeneous opacity. She was referred to tertiary care hospital where BAL and TBNA were done. BAL cultures were negative. TBNA showed suspicion of adenocarcinoma. Patient subsequently came to us for further treatment. She was tachypenic, managed with Non Invasive Ventilation and other supportive care. All routine tests were normal. Chest x- ray showed right upper zone opacity with right basal haziness (Figure 1). Pre chemotherapy work up was done. Computed Tomography (CT) scan (Figure 2 a, b) and PET CT (Figure 2c) showed metastatic disease with mediastinal lymph node uptake, liver lesion and

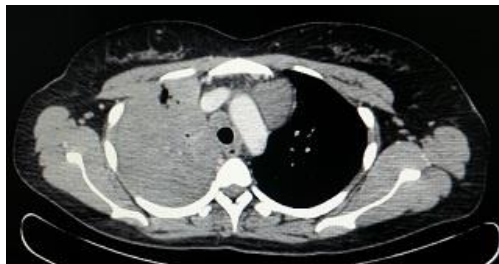abdominal lymph node uptake. Echocardiography showed mild pericardial effusion. However, on review of slides adenosquamous cell carcinoma was reported. Immunohistochemistry showed positivity for TTF-1, p-63, CK-5/6 &7, CEA and CK 20 negative which confirmed diagnosis of adenosquamous carcinoma of lung. However, patient's condition deteriorated rapidly and she had to be intubated. Unfortunately, on the same day she had refractory hypotension and cardiac arrest to which she succumbed.



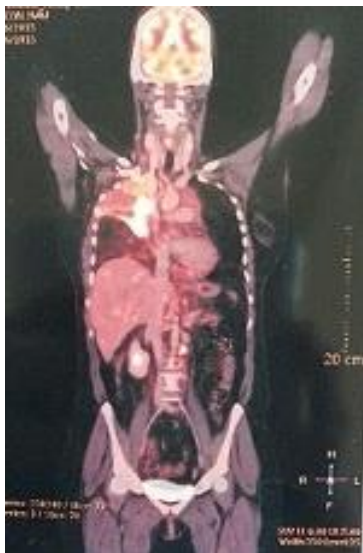**Fig-1**



**Fig-2a**



**Fig-2b**



**Fig-3**

## DISCUSSION

Lung cancer is the most common and leading cause of death, both in men and women. Deaths caused by lung cancer alone is more than those caused by cancer of colon, breast and pancreas (next three most common cancers after lung in USA) added together. Adenosquamous carcinoma (ASC) of lung is a relatively rare subtype of non small cell lung. By W.H.O definition, tumor cells comprises of at least 10% each of adenocarcinoma and squamous cell carcinoma [1]. However, the Japan Lung Cancer Society [2] previously used a more stringent cut off of at least 20% cells of each type, before adopting standard W.H.O classification.

Various studies have reported the incidence between 0.3% to 5%. H. Maeda *et al.* [3] reported incidence of 2.4%. The median age of presentation is 68.7 years with male predominance. The presentation symptoms are usually respiratory as with other type of lung cancers, however in view of highly aggressive nature of ASC duration of history might not be long as most of other indolent malignancies. In fact, acute pneumonias are more up the list of diagnosis if it presents in a relatively young individual, as in our case.

The site of occurrence is usually peripheral. The characteristics and prognosis of ASC remains poorly understood due to the relative rarity of this subtype. Histopathology and Immunohistochemistry thereafter help to diagnose adenosquamous cancer. CK5 is a sensitive marker for squamous cell variant and more specific than p63. TTF-1 is sensitive for adenocarcinoma variant. Brunnstrom *et al.* [3] in their study concluded that CK5 and TTF-1 are very sensitive for squamous cell and adenocarcinoma of lung respectively. H. Maeda *et al.* [4] in their retrospective study of 114 patients identified of having ASC post resection, concluded that ASC was more aggressive than adenocarcinoma and squamous cell carcinoma. Shimizu *et al.* [5] also reported poor survival in patients with ASC. Patients with ASC are more prone to have coexistent double cancer [6].

Our case too had a very rapid course of disease. There was short time between presentation and the fatal outcome, thus reinforcing the aggressive nature of this malignancy.

Treatment includes chemotherapy as for NSCLC. Early stages are amenable to surgery followed by chemotherapy. Prophylactic brain radiotherapy has also been recommended in view of aggressive nature of malignancy. Adjuvant therapy with erlotinib and gefitinib, especially in patients with EGFR mutations has been tried with positive results [7].

In conclusion, adenosquamous carcinoma of lung is less common variant associated with very high virulence. It should be thought of while formulating the differential diagnosis and Immunohistochemistry should be the part of the work up for lung cancer. As the limited available literature suggests virulent nature, high clinical suspicion should be maintained. Surgical intervention should be attempted in early stages of cancer. Adjuvant therapies should be utilized where possible.

## REFERENCES

1. Travis WD, Brambilla E, Muller-Hermelink HK, Harris CC (Eds); WHO Classification of Tumours: Pathology and Genetics of Tumours of the Lung,

- 
- Pleura, Thymus and Heart. Lyon, France:IARC Press, 2004.
  2. The Japan Lung Cancer Society; General rules for clinical and pathological recording of lung cancer, 5<sup>th</sup> ed.,Tokyo: Kanehara, 1999.
  3. Brunnstrom H, Johansson L, Jirstrom K, Jonsson M, Jonsson P, Planck M; Immunohistochemistry in the differential diagnostics of primary lung cancer: an investigation within the Southern Swedish Lung Cancer Study. *Am J Clin Pathol*, 2013; 140: 37-46.
  4. Maeda H, Matsumura A, Kawabata T, Suito T, Kawashima O, Watanabe T, et al.; Adenosquamous carcinoma of the lung:surgical results as compared with squamous cell and adenocarcinoma cases. *European Journal of Cardio-Thoracic Surgery*, 2012; 41: 357-361.
  5. Shimizu J, Oda M, Hayashi Y, Nonomura A, Watanabe Y; A clinicopathologic study of resected cases of adenosquamous carcinoma of lung.*Chest*, 1996;109: 989-94.
  6. Uramoto H, Yamada S, Hanagiri T; Clinicopathological characteristics of resected adenosquamous cell carcinoma of the lung:Risk of coexistent double cancer. *Journal of Cardiothoracic Surgery*, 2010:
  7. Song Z, Lin B, Shao L, Zhang Y; Therapeutic efficacy of gefitinib and erlotinib in patients with advanced lung adenosquamous carcinoma. *Journal of the Chinese Medical Association*, 2013; 76(9): 481-485.