

## **Pregnancy tumor: A case report**

**Dr Jadhav Vaishali, Dr Misri Amrita, Dr Prabhu Santoshi, Dr Mishra Nigamanand, Dr Savani Gayatri**  
Obstetrics & Gynecology Department, BARC Hospital, Anushakti Nagar, Mumbai- 400 094

### **\*Corresponding author**

Dr. Jadhav Vaishali

Email: [vai\\_roh@yahoo.co.in](mailto:vai_roh@yahoo.co.in)

---

**Abstract:** A Pyogenic Granuloma (PG) is a benign growth in the oral cavity that develops from gingiva. Its occurrence during pregnancy is rare. When occurs during pregnancy it is called as granuloma gravidarum or pregnancy tumor. Usually its course during pregnancy is harmless and shows spontaneous regression after delivery. This case reports a vascular pregnancy tumor which had repeated episodes of hemorrhage near term. The case was managed conservatively during pregnancy and surgical excision was performed post-partum.

**Keywords:** Pyogenic Granuloma, Granuloma Gravidarum, Pregnancy Tumor

---

### **INTRODUCTION**

Pyogenic granuloma (PG) is a localized granulation tissue of the oral cavity or skin and is non-neoplastic in nature. In 1844, Hüllihen described it in English literature for the first time. The term 'pyogenic granuloma' or 'granuloma pyogenicum' was introduced by Hartzell in 1904. The word 'pyogenic' refers to pus [1]. It is a subtype of granuloma and contains blood vessels not pus.

The incidence of pregnancy tumor is 1-5% of pregnant women [1]. It appears most often during the second or third trimester. It can show up anywhere in the mouth, but is mostly seen near the gum line. It is usually asymptomatic but can bleed easily. Pregnancy tumors range in size from a few millimeters to an inch or two. They can appear after denture injuries or due to hormonal changes [2, 3].

### **CASE REPORT**

27 years old pregnant woman, primigravida with 19 weeks of pregnancy reported to antenatal clinic on 26/02/14. Patient had off and on tooth ache and swelling of right cheek for last one month. Patient was referred to dental OPD for opinion. She was found to have carried 2<sup>nd</sup> right lower molar tooth. Patient was started on oral antibiotics (Amoxicillin) and analgesic (Paracetamol). As she was symptomatically better, extraction of carried tooth was advised after delivery. Patient had regular antenatal follow up visits later.

On 26/06/14, patient reported as emergency to dental OPD with a huge swelling occupying almost the whole of right lower buccal sulcus with severe bleeding from the tumor. On examination there was a fleshy

mass of around 4x 4 cm detected arising from gums with evidence of carried 2<sup>nd</sup> right lower molar tooth (Figure 1). The lesion was firm, non-tender but was bleeding on touch.

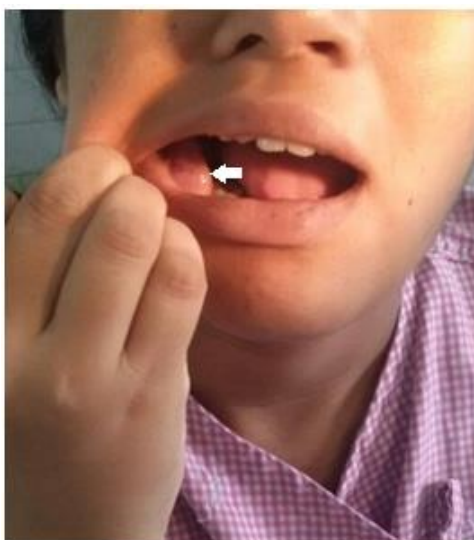Local pressure with ice packs were attempted to control active bleeding. Emergency excision of tumor under local anesthesia was planned in case if bleeding continued. The bleeding stopped completely with local pressure and ice fomentation. Hence, the decision of surgical excision was postponed to post delivery period and conservative medical management was continued with antibiotics, local pressure and ice application.

On 03/07/14, patient was admitted in early labor. Emergency LSCS under spinal anesthesia was performed on 04/07/14 in view of meconium stained amniotic fluid. She delivered a healthy male child 3Kg with 9/10 APGAR.

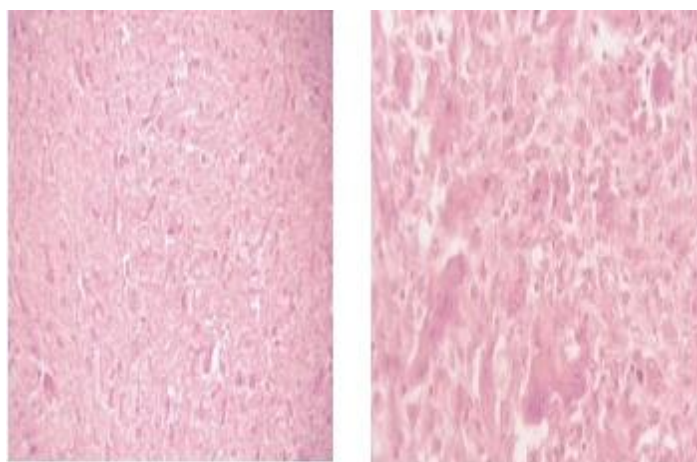
On, 09/07/14 (post-operative day 6) patient was referred to dental OPD for review of lesion. She was asked to follow up after 3 weeks for review, watching for spontaneous regression of tumor.

After three weeks the tumor size had marginally reduced. Although there was no active bleeding from the tumor, the decision of local excision was taken as the tumor interfered with mastication.

The tumor was excised under local anesthesia along with the carried tooth on 28/07/14 (post-delivery day 24) and sent for histopathological examination. Histopathology report showed peripheral giant cell granuloma (Figure 2).



**Fig-1: Pregnancy Tumour (Anterior view)**



**Fig-2: Histopathology: Giant cell granuloma**

#### **DISCUSSION:**

The chance of development of Pyogenic Granuloma (PG) of the gingiva in pregnancy is up to 5%, hence the terms 'Pregnancy tumor' and 'Granuloma gravidarum' are sometimes used. The hormonal imbalance with pregnancy increases the organism's response to irritation, [4]. This is well-defined lesion which appears around the third month of pregnancy. It slowly increases in size and, after delivery, may or may not regress. It has a tendency to bleed. It may interfere with mastication. Estrogen increases vascular endothelial growth factor (VEGF) production in macrophages [5], and in turn decreases androgens and can cause the development of pregnancy tumour. Absence of VEGF causes blood vessels to regress. The amount of VEGF is seen to be high in granulomas in pregnancy and cannot be detected after parturition [6]. Progesterone works as an immunosuppressant in the gingival tissues of pregnant women. It prevents rapid acute inflammatory reaction against plaque, but it causes an increased chronic tissue

reaction, which results in an exaggerated appearance of inflammation [7]. Surgical excision of the pregnancy tumor after delivery is the best treatment option [6]. Although conservative surgical excision and removal of causative irritants are the commonly done treatments [4]. The excision should extend down to the periosteum and the adjacent teeth should be thoroughly scaled to remove the source of continuing irritation [8]. The Nd: YAG laser is used nowadays as there is lower risk of bleeding compared to other surgical techniques [9]. The majority of cases is symptomatic and shows bleeding nodules (71.9%) with soft consistency (62.3%) and a red surface (73.2%) [10]. Simple excision can prevent recurrence but the etiology and pathogenesis should be known to understand its nature [11]. Recently, the flash lamp pulsed dye laser, cryosurgery, sodium tetradecyl sulfate sclerotherapy are being used. For recurrent lesions, intralesional injection of absolute ethanol, corticosteroids were successfully tried. If uncontrolled bleeding occurs, management should be based on the individual condition and should range from supportive

---

therapy like desiccation of bleeders, local, firm compression to blood transfusion, medication to accelerate fetal lung maturity or even termination of pregnancy to save the patient's life. During the excision of a pyogenic granuloma of the gingival, care should be taken to scale the adjacent tooth and should be free of calculus. The calculus may act as a source for recurrence of the lesion [12]. Thus, during pregnancy, careful oral hygiene, removal of dental plaque and use of soft toothbrushes are very important in order to avoid occurrence of this tumor. Pregnancy tumors are not dangerous. Pregnancy tumors may disappear or shrink post delivery. Pregnancy tumors may be visible and embarrassing to the pregnant woman. To prevent getting a pregnancy tumor, regular dental checks in the prenatal period, in early pregnancy for diagnosis and assessment is a must. Routine dental care throughout pregnancy. Presence of tartar can cause a pregnancy tumor to grow. Brushing twice a day and flossing every day, and use of non-alcohol gargles is recommended.

### CONCLUSION

Regular dental checks in the antenatal period, good oral hygiene can avoid this tumor. Post delivery excision of tumor is the treatment of choice. The chance of the tumor recurrence increases due to improper dental hygiene, incomplete removal of tumor and removal of tumor during pregnancy.

### Acknowledgements:

1. Department of Dentistry, BARC Hospital.
2. Department of Pathology, BARC Hospital.

### REFERENCES

1. Gondivkar, Shailesh M, AmolGadbail, RevantChole; "Oral Pregnancy Tumor." Contemporary Clinical Dentistry 1, 2015; 3 (2010): 190–192.
2. Freedberg; Fitzpatrick's Dermatology in General Medicine. (6th ed.). McGraw-Hill, 2003.
3. Jafarzadeh H, Sanatkhani M, Mohtasham N; "Oral pyogenic granuloma: a review" (- Scholar search). J Oral Sci 2006; 48 (4): 167 75.
4. Eversole LR; 3rd ed. Hamilton: BC Decker; Clinical outline of oral pathology: Diagnosis and treatment, 2002; 113–4.
5. Regu P, Aatman Sharma, MuraliGopika Manoharan GV; "Pyogenic granuloma of the tongue- a rare clinical finding".Int J Dent Case Reports 2013; 3(2): 57-61.
6. Lindenmuller IH, Noil P, Mameghani T, Walter C; CO2 laser-assisted treatment of a giant pyogenic granuloma of the gingival. Int J Dent Hyg. 2010; 8(3):249–52.
7. Ojanotko-Harri AO, Harri MP, Hurttia HM, Sewon LA; Altered tissue metabolism of

- progesterone in pregnancy gingivitis and granuloma. J ClinPeriodontol. 1991; 18:262–6.
8. Neville BW, Damm DD, Allen CM, Bouquot JE; 2nd ed. Philadelphia: WB Saunders; 2002. Oral and maxillofacial pathology, 437–95.
9. Powell JL, Bailey CL, Coopland AT, Otis CN, Frank JL, Meyer I. Nd; YAG laser excision of a giant gingival pyogenic granuloma of pregnancy. Lasers Surg Med. 1994; 14:178–83.
10. Gordon-Nunez MA, de vasconcelos M, Benevenuto TG, Lopes MF; Oral pyogenic granuloma: a retrospective analysis of 293 cases in a Brazilian population. J Oral Maxillofac Surg. 2010; 68(9):2185–8.
11. Saravana GH; Oral pyogenic granuloma: a review of 137 cases. Br J Oral Maxillofac Surg.2009; 47(4):318–9.
12. William G.Shafer, Maynard K.Hine, Barnet M.Levy; Bacterial,Viral and Mycotic Infections.A Textbook of Oral Pathology,4th edition 2000;361.