

## **A satisfactory recovery after emergency pericardiocentesis in type an acute aortic dissection with cardiac arrest**

**Hiromichi Ohsaka<sup>1</sup>, Toshihiko Yoshizawa<sup>1</sup>, Kouhei Ishikawa<sup>1</sup>, Kei Jitsuiki<sup>1</sup>, Satoru Suwa<sup>2</sup>, Yosuke Saito<sup>3</sup>, Keiichi Tambara<sup>3</sup>, Youichi Yanagawa<sup>1</sup>**

<sup>1</sup>Department of Acute Critical Care Medicine, Shizuoka Hospital, Juntendo University, Japan

<sup>2</sup>Department of Cardiology, Shizuoka Hospital, Juntendo University, Japan

<sup>3</sup>Department of Cardio surgery, Shizuoka Hospital, Juntendo University, Japan

### **\*Corresponding author**

Youichi Yanagawa

Email: [yyanaga@juntendo.ac.jp](mailto:yyanaga@juntendo.ac.jp)

---

**Abstract:** An 84-year-old female fell unconsciousness after complaining of suffering from pain. She was still unconsciousness on arrival. An urgent cardiac echo suggested dissection of the aorta with cardiac bloody tamponade. We decided to start permissive hypotensive therapy. Enhanced computed tomography confirmed that the patient had type an acute aortic dissection (AD) with cardiac tamponade. After she was returned to the emergency room for preparation for radical operation, her respiration ceased, and she entered cardiac arrest (electrical pulse less activity). Urgent pericardiocentesis was performed under bag mask ventilation with manual chest compression. After the patient had absorbed approximately 50 mL of bloody fluid, spontaneous circulation was restored. She underwent tracheal intubation with sedation and was moved to an operation room for replacement of the ascending aorta. Postoperative course was uneventful. After rehabilitation, she was discharged on Day 14 of hospitalization. We believe the key points contributing to our success were 1) early recognition of type an acute AD with cardiac tamponade by ultrasound, 2) conducting permissive hypotensive therapy under systolic blood pressure of 90 mmHg, 3) simultaneously preparing pericardiocentesis in the emergency room when the patient entered cardiac arrest, in addition to radical operation by a consulting cardiac surgeon.

**Keywords:** pericardiocentesis; aortic dissection; cardiac arrest

---

### **INTRODUCTION**

The outcome of type an acute aortic dissection (AD) is poor when patients enter cardiopulmonary arrest [1-3]. In cases of cardiac arrest due to cardiac tamponade, effective cardiac output cannot be obtained until after decompression of cardiac tamponade, even when patients receive chest compression. Two previous case studies have reported achieving a favorable outcome using open heart massage with pericardiectomy for patients with type an acute AD and cardiac tamponade [4, 5]. We herein report a case of AD with cardiopulmonary arrest that was successfully treated by cardiopulmonary resuscitation with pericardiocentesis.

### **CASE REPORT**

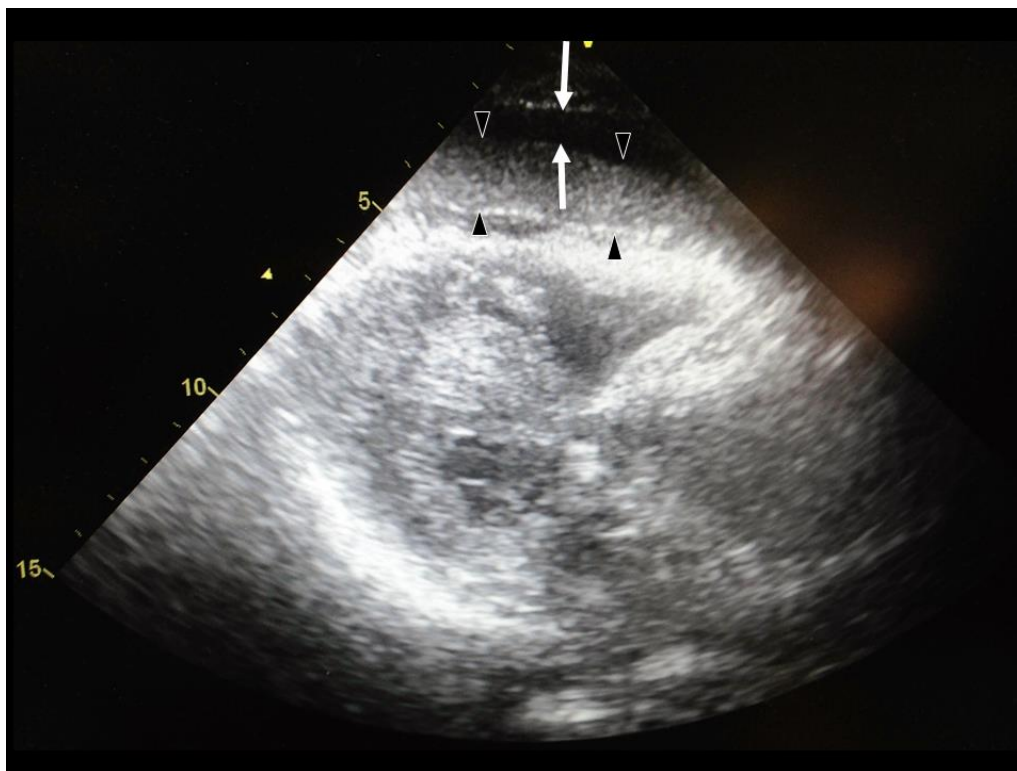
An 84-year-old female fell unconsciousness after complaining of suffering from pain and an ambulance was called. When physicians arrived on the scene, the patient was in a comatose state. Her sum score on the Glasgow Coma Scale was 8 without any obvious paresis, with a systolic blood pressure of 120 mmHg, heart rate of 90 beats per minute, and a SpO<sub>2</sub> of 100% under 15 L/minute of oxygen delivered via a

reservoir mask. During transportation by helicopter, her systolic blood pressure decreased to 70 mmHg, prompting technicians to start infusion of dopamine. She was still unconsciousness on arrival, and her systolic blood pressure had increased to 110 mmHg. An urgent cardiac echo suggested dissection of the aorta with cardiac bloody tamponade (Figure 1).

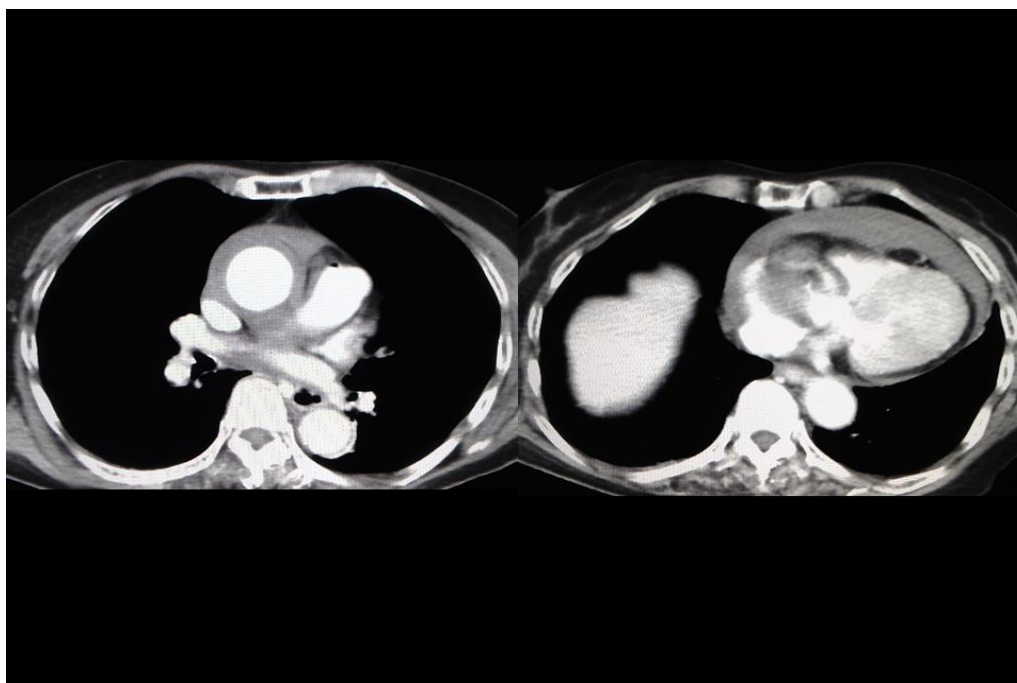
We decided to start permissive hypotensive therapy, discontinuing dopamine. Enhanced computed tomography confirmed that the patient had type an acute AD with cardiac tamponade. After she was returned to the emergency room for preparation for radical operation, her respiration ceased, and she entered cardiac arrest (electrical pulse less activity). Urgent pericardiocentesis was performed under bag mask ventilation with manual chest compression. After the patient had absorbed approximately 50 mL of bloody fluid, spontaneous circulation was restored. She underwent tracheal intubation with sedation and was moved to an operation room for replacement of the ascending aorta. Operation was completed in 3 hours. On Day 3 of hospitalization, her circulation and respiration improved, and extubation

was performed. Postoperative course was uneventful. After rehabilitation, she was discharged on Day 14 of

hospitalization. Her degree of intelligence and cognizance was the same as before admission.



**Fig 1: Echography on arrival. Echography findings showed pericardial low (arrow) and high (triangle) echoic layer (separation of blood plasma and clot), suggesting hemorrhagic pericardial effusion**



**Fig 2: Enhanced chest CT on arrival. Chest CT findings showed type an acute aortic dissection with cardiac tamponade.**

#### DISCUSSION

Cardiac tamponade induced by type an acute AD has a poor prognosis, particularly in cases of

cardiac arrest [1-3]. To our knowledge, this is the first case of satisfactory recovery after emergency pericardiocentesis in type an acute AD with cardiac

---

arrest. We believe the key points contributing to our success were 1) early recognition of type an acute AD with cardiac tamponade by ultrasound, 2) conducting permissive hypotensive therapy under systolic blood pressure of 90 mmHg, 3) simultaneously preparing pericardiocentesis in the emergency room when the patient entered cardiac arrest, in addition to radical operation by a consulting cardiac surgeon. In cases of acute cardiac bloody tamponade, simple pericardiocentesis often is not effective due to the presence of a clot,[6] and cardiac tamponade by type A acute AD will likely complicate cardiac arrest. We were therefore ready to provide immediate open cardiac massage to treat such patients should pericardiocentesis prove to be ineffective.

The Task Force of the European Society of Cardiology on Diagnosis and Management of Patients with Aortic Dissection concluded that pericardiocentesis is contraindicated for AD, due to the risk of an exacerbation of bleeding [7]. Therefore, in patients with type an acute AD (DeBakey type I, II), immediate surgery is indicated in all patients with cardiac tamponade, since mortality increases by up to 10% per hour for every hour of delayed surgical treatment. However, Hayashi *et al.*; reported 18 patients with type A acute AD and cardiac tamponade who did not respond to intravenous volume resuscitation, instead undergoing pericardial drainage by pericardiocentesis in the emergency room [8]. In their report, although 2 patients entered cardiac arrest, the blood pressure increased and aortic repair successfully performed in all 18 patients. Ultimately, 15 patients survived, but the final outcome of the 2 cases of cardiac arrest was not described. Those authors hypothesized that the key point contributing to their success was managing blood pressure by controlling drainage volume to ensure the patient did not become hypertensive.

## CONCLUSION

Emergency physicians should be ready to provide immediate pericardiocentesis to treat such patients, at least when the patient enters cardiac arrest in the emergency room.

## REFERENCES

1. Yanagawa Y, Sakamoto T; Characteristics of patients that experience cardiopulmonary arrest following aortic dissection and aneurysm. *J Emerg Trauma Shock*. 2013; 6(3):159-63.
2. Chavanon O, Costache V, Bach V, Kétata A, Durand M, Hacini R, *et al.*; Preoperative predictive factors for mortality in acute type A aortic dissection: an institutional report on 217 consecutives cases. *Interact Cardiovasc Thorac Surg*. 2007; 6(1):43-6.
3. Bayegan K, Domanovits H, Schillinger M, Ehrlich M, Sodeck G, Laggner AN; Acute type A aortic dissection: the prognostic impact of preoperative cardiac tamponade. *Eur J Cardiothorac Surg*. 2001; 20(6):1194-8.
4. Yanagawa Y, Morita K, Sakamoto T, Okada Y, Isoda S, Maehara T; A satisfactory recovery after emergency direct cardiac massage in type A acute aortic dissection with cardiac arrest. *Am J Emerg Med*. 2006; 24(3):356-7.
5. Terasumi K, Yanagawa Y, Isoda S; A successful treatment of cardiac tamponade due to an aortic dissection using open-chest massage. *Am J Emerg Med*. 2012; 30(4):634.e1-2.
6. Kurimoto Y, Hase M, Nara S, Yama N, Kawaharada N, Morishita K, *et al.*; Blind subxiphoid pericardiotomy for cardiac tamponade because of acute hemopericardium. *J Trauma*. 2006; 61(3):582-5.
7. Erbel R, Alfonso F, Boileau C, Dirsch O, Eber B, Haverich A, *et al.*; Task Force on Aortic Dissection, European Society of Cardiology. Diagnosis and management of aortic dissection. *Eur Heart J*, 2001; 22(18):1642–81.
8. Hayashi T, Tsukube T, Yamashita T, Haraguchi T, Matsukawa R, Kozawa S, *et al.*; Impact of controlled pericardial drainage on critical cardiac tamponade with acute type A aortic dissection. *Circulation*. 2012; 126(11 Suppl 1):S97-S101.