

# Surgical Treatment of Kienböck's Disease by Shortening Osteotomy: Case Series and Review of Literature

Yassine Ben Bouzid<sup>1\*</sup>, Rhita Salah<sup>1</sup>, Mohammed Bencheekroun<sup>1</sup>

<sup>1</sup>Trauma and Orthopedics Department, Mohammed V Military Hospital, Rabat, Morocco

DOI: [10.36347/sajs.2023.v09i03.003](https://doi.org/10.36347/sajs.2023.v09i03.003)

| Received: 05.02.2023 | Accepted: 11.03.2023 | Published: 15.03.2023

\*Corresponding author: Yassine Ben Bouzid

Trauma and Orthopedics Department, Mohammed V Military Hospital, Rabat, Morocco

## Abstract

## Original Research Article

**Introduction:** Kienböck's disease is a rare condition. It most often affects young, manual workers. Imagery is used to diagnose and classify the disease using the Decoulx classification which will guide the therapeutic decision. The aim of the present work is to review the clinical data, the diagnostic methods and our therapeutic results compared with the literature. **Material and Methods:** This is a retrospective study of four cases of Kienböck's disease, collected in the Traumatology-Orthopedics Department of the Mohamed V Military Instruction Hospital in Rabat, over an twenty-year period, from March 2002 to October 2022. **Results:** The series includes eight men and two women, with an average age of 35 and a half years. Pain and decreased mobility were present in all our patients. All of our patients had a radiological workup that allowed the diagnosis six of our patients were in stage II of the disease, three in stage IIIa and one in stage IIIb. All our patients benefited from a shortening of the radius with a good evolution and a return to activities. **Discussion:** By comparing the results of our study with those of the literature, we found a clear concordance concerning the clinical, imaging and therapeutic means. **Conclusion:** Kienböck's disease is a rare disease that should be diagnosed at the early stage to prevent its evolution.

**Keywords:** Lunatum, avascular osteonecrosis, Kienböck disease, shortening osteotomy.

Copyright © 2023 The Author(s): This is an open-access article distributed under the terms of the Creative Commons Attribution 4.0 International License (CC BY-NC 4.0) which permits unrestricted use, distribution, and reproduction in any medium for non-commercial use provided the original author and source are credited.

## INTRODUCTION

In 1910, Kienböck published his popular article on traumatic lunatectomy [1]. Using radiographs, Kienböck described avascular necrosis of the lunate for the first time. It was described as an isolated disease of the lunate associated with some secondary changes in the other carpal bones [2]. The first cases of Kienböck disease were reported in the American literature in 1925 when Goldsmith described the disease in several of his patients. He also stated that the disease was first described by Peste in 1843 but was not widely recognized until Kienböck's publication in 1910 [3].

Kienböck's disease usually affects adults between 20 and 40 years of age, who are mainly manual workers.

The involvement is usually unilateral [4]. A traumatic event is frequently reported months or years before the diagnosis.

Dorsal wrist pain and decreased grip strength usually occur at the time of carpal collapse, probably related to progressive alteration of carpal architecture

and function rather than to bone necrosis [5]. Carpal tunnel syndrome may complicate the course of the disease [6].

The diagnosis is usually made on standard radiographs, which are of additional help for treatment and outcome assessment [7]. MRI is the gold standard for diagnosis [8].

Several classifications have been proposed, but the one described by Lichtman *et al.*, is the most commonly used and the one that has shown good reproducibility and reliability [9].

The treatment of Kienböck's disease is mainly guided by the patients symptomatology and functional deficits, as well as by the stage of the disease. Several surgical procedures have been described for the treatment of lunate osteonecrosis without sufficient information to determine the best treatment options [10]. There are three main categories in the surgical treatment of Kienböck disease: biomechanical lunate offloading, vascularized bone grafting and salvage.

## MATERIALS AND METHODS

### A. Framework and Type of Studies

This is a retrospective study of ten cases of Kienböck's disease collected in the Traumatology-Orthopedics I department of the Mohamed V Military Hospital of Instructions in Rabat, over a period of twenty years, from March 2002 to October 2022.

We excluded incomplete records and patients who were lost to follow-up.

The work has been reported in line with the PROCESS criteria [23].

### B. Method

We studied for our patients (Table 1):

#### 1. Clinical Study

The study of the records in a retrospective way allowed us to look for:

- Age.
- Gender.
- Occupation.
- The notion of trauma.
- The dominant limb and the affected limb.
- The reason for consultation.

- The pain (evaluated according to the visual analog scale).
- Mobility (tested by goniometer).
- Grip strength (evaluated subjectively in the absence of the availability of a dynamometer).

#### 2. Radiological Study

A standard radiograph with two orthogonal views was routinely requested as a first line of study to assess the following parameters:

- The radio-ulnar index.
- Carpal and lunate height.
- Lunar overhang.
- The radiolunate angle.
- The radioscapoid angle.
- The scapholunate angle.

Additional CT or MRI has been requested in some patients to confirm the diagnosis.

The purpose of the radiological workup is to stage the disease using the Lichtman classification.

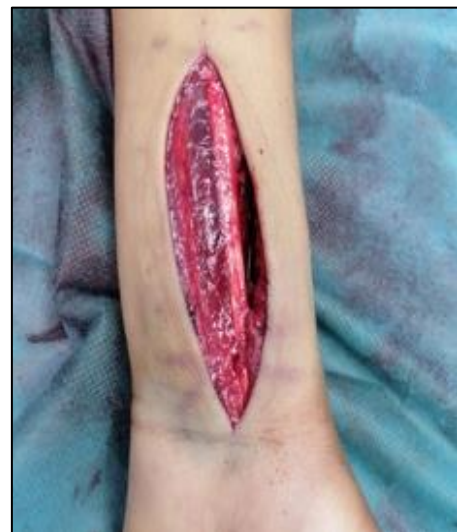Data were analyzed on SPSS.

**Table 1: Summary of clinical and radiological data collected**

Clinical study	Radiological study
Age	Radio-ulnar index.
Sex	Carpal and lunate height.
Occupation	Lunar overhang.
Notion of trauma	Radiolunate angle.
Dominant limb and affected limb	Radioscapoid angle.
Reason of consultation	Scapholunate angle.
Pain	
Mobility	
Grip strenght	

#### Description of the Technique

Patients were operated on under general anesthesia, in the dorsal position and with a pneumatic tourniquet on the upper arm root. After swabbing the surgical site and applying a sterile drape, the distal part of the radius was exposed via an anterior approach, passing between the flexor carpi radialis muscle and the radial artery (figure 5). The diaphysis was then exposed with the help of a rugine over a length of at least 10 cm, followed by a 4-mm osteotomy directed at an angle of 45° to the longitudinal axis of the diaphysis (figure 6), and then a fixation with a T-plate (figure 7 and 8). A posterior splint was applied. Postoperatively, all our patients received antibiotic prophylaxis for 48 hours in addition to analgesic treatment. Immobilization was maintained for two weeks, and then a well-defined rehabilitation program was prescribed.



**Figure 5: Image illustrating Henry anterior approach [13]**

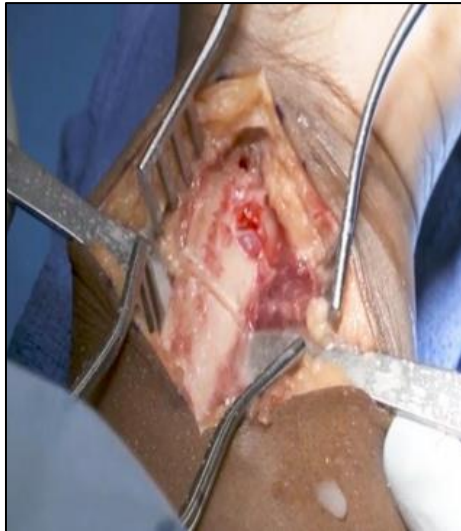

Figure 6: Image illustrating the radius shortening osteotomy [13]

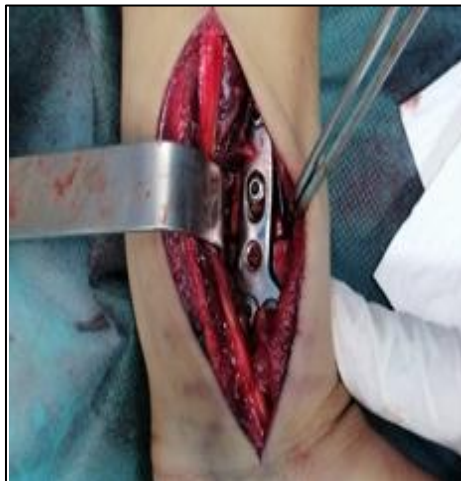

Figure 7: Image showing the placing of a T-plate after a radius shortening osteotomy has been performed [13]

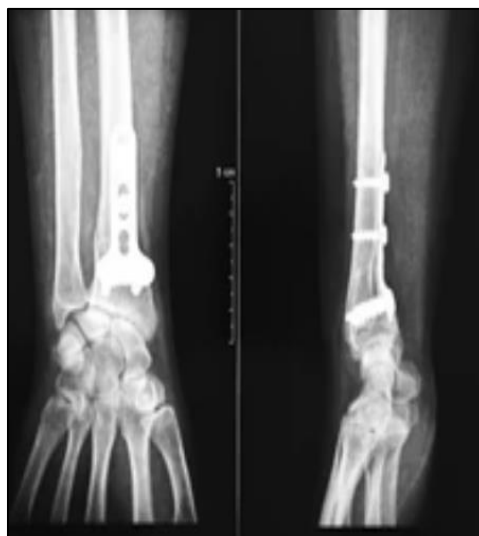

Figure 8: Follow-up radiographs after radius shortening and T-plate fixation [13]

## RESULTS

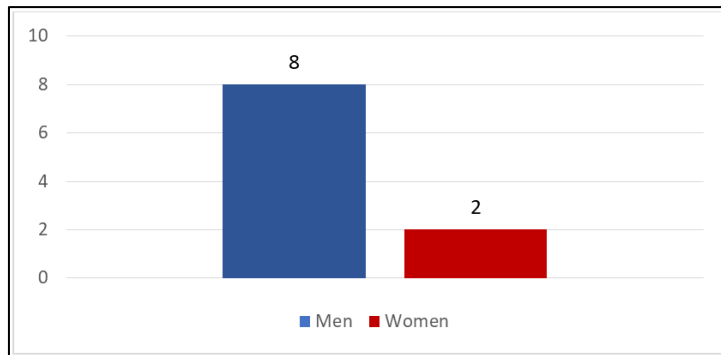
### -Epidemiological data

Our study reported on 10 cases including eight males and two females (4:1 ratio) (Graph 1) with an age

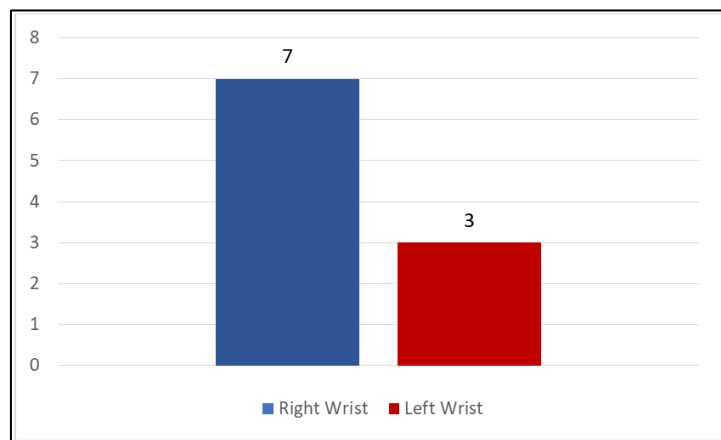
limit between 20 and 47 years and an average age of 34 years. We noted that the condition affected the right wrist in seven cases and three cases of the left wrist (Graph 2). The affection was unilateral and the

dominant side was involved in 7 cases. The notion of trauma was found in half of our cases. Nine patients

were manual workers. Pain, limitation of mobility and decreased grip strength were common in all the cases.



**Graph 1: Distribution diagram of our patients according to gender**



**Graph 2: Diagram of the distribution of cases according to the side affected**

**- Clinical Data**

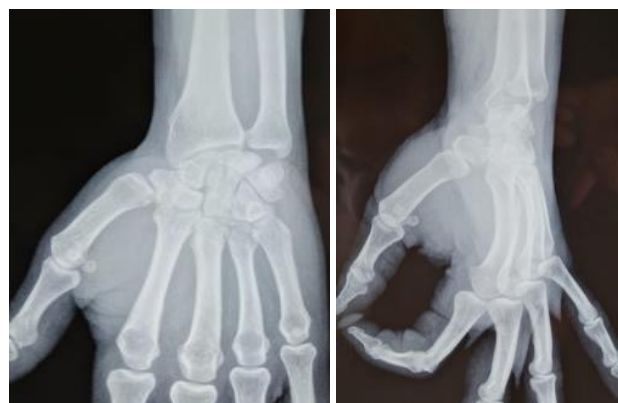Pain was the main reason for consultation. It was associated with a complete or partial functional impairment. Mobility was decreased in all of our patients, particularly flexion-extension movements. The prehension strength was also reduced in all cases.

**- Radiological Data**

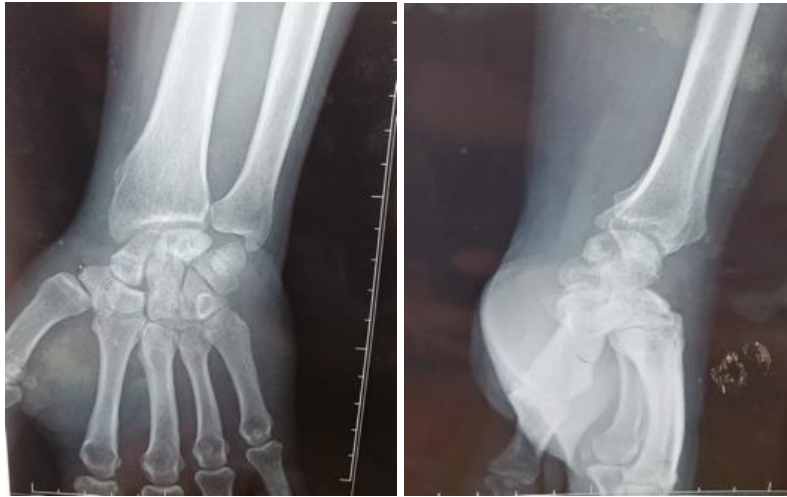Standard radiography with two orthogonal incidences was routinely requested, with additional CT-scan or MRI in some patients. Six patients were diagnosed with stage II disease according to Lichtman

classification (figure 1), with stage IIIa and one with stage IIIb (figure 2, 3 and 4).

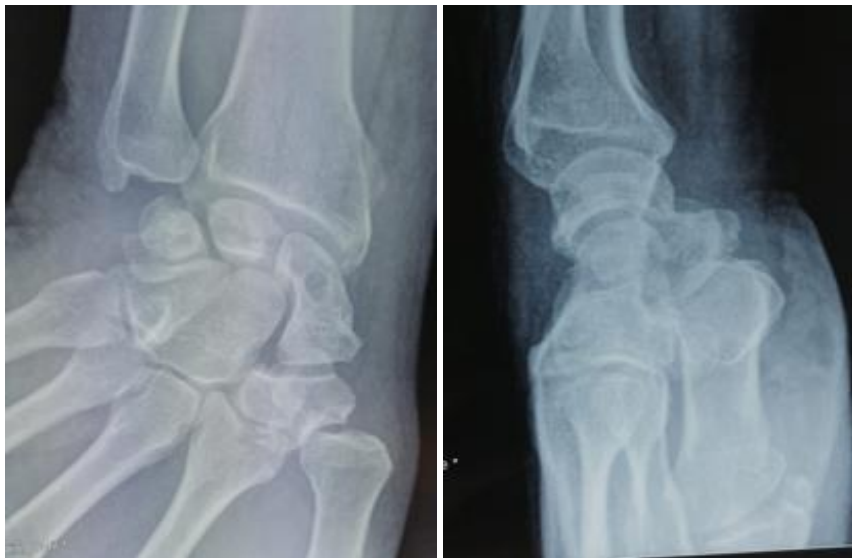Radius shortening osteotomy was performed in all our patients. No postoperative complications were noted. The evolution was successful with regression of pain and restoration of joint amplitudes and grip strength, allowing all our patients to regain their normal activity. As for radiological images, they remained unchanged in 9 of our cases with only one case showing improvement.



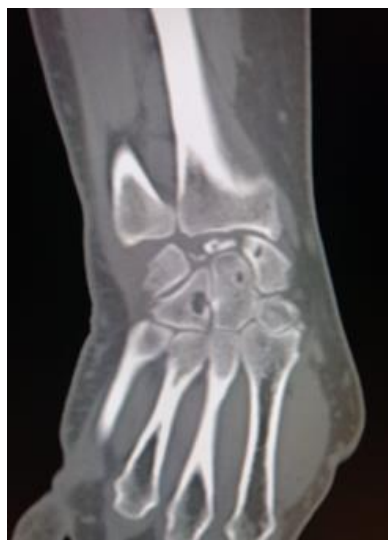**Figure 1: Radiographs showing inhomogeneous condensations of the lunate bone [13]**



**Figure 2: Frontal and lateral radiographs of the right wrist showing inhomogeneous condensation with a few geodes of the lunate bone [13]**



**Figure 3: Frontal and lateral radiographs of the wrist showing a collapse of the lunate bone with some spots of increased density [13]**



**Figure 4: CT-scan of the wrist showing the fragmented and collapsed appearance of the lunate bone with subchondral cysts of the carpal bones [13]**

## DISCUSSION

Kienböck's disease is a rare condition. The prevalence is 0.5% in the general population and 1.1% to 2% in populations exposed to vibration [11].

The incidence is about 1/30000 in France, it is relatively frequent in Swedish people unlike in China and in black Americans. In our study, we collected 10 cases in 20 years treated at the Mohamed V military hospital in Rabat.

It mainly affects young people aged between 20 and 40 years, manual workers [7], with a male predominance [4]. Although this pathology can occur in children, its occurrence is considered impossible before puberty by some authors [12]. In our study, the majority of our patients were male (8 cases) with an age ranging from 20 to 47 years and an average age of 35 years, which is in line with international epidemiology.

The involvement is generally unilateral on the dominant side with a notion of trauma found in the history [13, 14]. Bilateral affection of both wrists can be found. In our study, 7 of our patients were affected on the right wrist, and 3 patients were affected on the left side. The dominant side was involved in 7 cases.

The majority of the affected patients are heavy manual workers (65%) and light manual workers (18%) [4]. Other workers may be exposed to this condition: cutting, ironing, textile, agricultural, machine operators, car mechanics, bricklayers, boilermakers, welders, handlers and machine mechanics [15]. In our study, 9 of our patients were manual workers. Kienböck's disease is now recognized as a compensable occupational disease in France.

The etiology of Kienböck's disease remains unknown. Aseptic necrosis of the lunate leads to its degeneration and fragmentation. Nevertheless, the causes of this necrosis are the subject of several theories.

The search for the context of trauma is the clinician's first concern when faced with a painful wrist [16]. Kienböck's disease is suspected in several situations [14, 17, 18]: a benign wrist trauma with suggestive lesions on X-rays; a notion of wrist torsion; a fall with landing on the palm of the hand, wrist in extension. The pain is often insidious, exacerbated by activities and relieved by rest and immobilization [6, 7]. Wrist range of motion is measured. In this condition, there is a painful limitation of wrist mobility, especially in extension [19]. In Kienböck's disease, there is a clear decrease in the strength of the affected wrist compared to the healthy side, which is a handicap for this population, the majority of whom are heavy workers.

Imaging is necessary [20], and shows partial or total necrosis of the lunate, compression, fragmentation

or collapse of the carpus, which confirms the diagnosis [21].

Several classifications have been proposed, the most commonly used being those of Decoulx and Lichtman. These are radiological classifications that are completely detached from the clinic.

For patients suffering from Kienböck's disease, shortening the radius by 4 to 6 mm compared to the ulna is one of the therapeutic approaches that lead to excellent results. Performed by Iluten [17] in 1928, this technique allowed him to obtain an anatomical correction. Person [15] in 1945, using the same procedure, obtained three satisfactory results but also two cases of secondary radial bowing due to poor bone healing, with a marked angulation that hindered and limited pronation and supination. Moberg and Axellson [17], considered that lengthening the ulna was a difficult procedure which sometimes led to serious complications, published a valuable study on radius shortening, based on 19 operated cases with excellent results. In France, this technique has been used cautiously for some years. Ramadier, Soulier and Decoulx, Jouglaard published: 10 cases with 8 excellent results [14]. Siala [22] reported the results of a series of 31 cases treated by diaphyseal shortening of the radius with an average hindsight of 16 years, and found clinical and radiological improvement. He believed that neither the inferior radioulnar index nor the inclination of the lunate fossa influenced the radiological evolution.

## CONCLUSION

Aseptic osteonecrosis of the lunate bone is a rare condition affecting young adult manual workers. At this point, it is the radius shortening osteotomy that provides the best results. A mechanical theory supports the assumption that osteonecrosis of the lunate bone is due to hyper-pressure in the semilunar compartment caused by a short ulna.

## DECLARATION OF CONFLICTING INTEREST

The authors declare that there is no conflict of interest.

## FUNDING

This research received no specific grant from any funding agency in the public, commercial, or not-for-profit sectors.

**Consent for Publication:** Not applicable to this manuscript.

## Authors Contributions

All authors participated in the data collection. All authors have read and approved the final manuscript

## REFERENCES

1. Kienböck, R. (1910). Über traumatische Malazie des Mondbeins und ihre Folgezustände :

- Entartungsformen und Kompressions- frakturen. *Fortschr Roentgenstr*, 16, 78-103.
2. Jared, P., Wagner, B. S., Kevin, C., Chung, M. D., & Ann Arbor, M. I. Un rapport historique sur Robert Kienböck (1871-1953) et la maladie de Kienböck.
  3. Goldsmith, R. (1925). La maladie de Kienböck de l'os semi-lunaire. *Ann Surg*, 81, 857-862.
  4. Evrard, H., Guillaume, C., Hoet, F., Koenig, H., & Van Innis, F. La maladie du semi-lunaire.
  5. Bochud, R. C., & Büchler, U. (1994). Kienböck's disease, early stage 3 : height reconstruction and core revascularization of the lunate. *J Hand Surg [Br]*, 19, 466-78.
  6. Beckenbaugh, R. D., Shives, T. C., Dobyns, J. H., & Linscheid, R. L. (1980). Kienböck's disease : the natural history of Kienböck's disease and considerations of lunate fractures. *Clin Orthop*, 149, 98-106.
  7. Schuind, F., Eslami, S., & Ledoux, P. La maladie de Kienbock.
  8. Gregory, P., Kolovich, C. M., Kalu, K., & Michael, E. R. Tendances actuelles du traitement de la maladie de Kienböck: A Survey of Hand Surgeons.
  9. Christopher, H., Allan, M. D., Atul Joshi, M. D., David, M., & Lichtman, M. D. La maladie de Kienböck : Diagnosis and Treatment.
  10. Pedro, K., & Beredjikian, M. D. La maladie de Kienböck.
  11. Dubois, J. N. Kienbock's disease in a farm equipment mechanic. *Arch. Mal. Prof. Travail, sécurité sociale*.
  12. Dumontier, P. H., Robin, E., & Dellagouth, J. P. (1982). A propos d'un cas de la maladie de Kienbock chez l'enfant. *Ann. Med. De Nancy et de l'est*, 21, 75-78.
  13. Zaddoug, O., Bah, A., & Jaafar, A. Current management of Kienböck's disease.
  14. Alnot, J., & Katzd, Y. (1987). Wrist and hand arthroplasties (total implant-prosthesis). *Encycl. Med. Chir (Paris-France). Orthopaedics*, 10(44), 372-16.
  15. Razemon, J. P. (1984). Treatment of kienbock's disease, by segmental shortening of the radius. *Ann. Chir. Hand*, 6(1100), 600-607.
  16. Omar, A. (1974). Primary osteonecrosis of the semilunar or Kienbock disease, Conceptions: etiopathogenic and therapeutic. *Thesis Med. Toulouse, France*, 120.
  17. Razemon, J. P. (1982). Round table on Kienbock's disease under the direction of J.P. Razemon. *Ann. Chir. Hand.*, 1(3), 233-86.
  18. Jarde, O., Decooplman, M., & Vives, P. (1986). Treatment of Kienbock's disease. *Larc. Med*, IV(3), 145-150.
  19. Decoulx, P., Duquennoy, A., & Attoustein, J. (1965). The surgical treatment of Kienböck's disease. About 18 operated cases. *Lille chir*.
  20. Mathoulin, C., Galbiatti, A., & Haerle, M. (2006). Revascularization of the semilunar associated with an osteotomy of the radius in the treatment of Kienböck's disease. *e-mémoires de l'Académie Nationale de Chirurgie*, 5(2), 50- 60.
  21. Lichtman, D. M., Mack, G. R., MacDonald, R. I., Gunther, S. F., & Wilson, J. N. (1977). Kienbock's disease: the role of silicone replacement arthroplasty. *J Bone Jt Surg Am*, 59(7), 899-908.
  22. Siala, A., ML, B. A., Frikha, R., Ghannouchi, G., & Moula, T. (2000). Results of diaphyseal shortening of the radius in the treatment of Kienböck's disease: a series of 31 cases. *Revue de Chirurgie Orthopedique et Reparatrice de L'appareil Moteur*, 86(2), 151-157.
  23. Agha, R. A., Sohrabi, C., Mathew, G., Franchi, T., Kerwan, A., O'Neill, N., ... & Mei, Z. (2020). The PROCESS 2020 guideline: updating consensus preferred reporting of CasE series in surgery (PROCESS) guidelines. *International Journal of Surgery*, 84, 231-235.