

Case Reports of Children with Vogt_Koyanagi_Harada Syndrome

Hasna Aamri^{1*}, FZ Azzouzi¹, R. Elqadiry¹, H. Nassih¹, A. Bourrahout¹, I. Ait Sab¹

¹Centre Hospitalier Universitaire Mohammed VI, Marrakesh, Morocco

DOI: [10.36347/sjmc.2023.v11i03.017](https://doi.org/10.36347/sjmc.2023.v11i03.017)

| Received: 03.02.2023 | Accepted: 08.03.2023 | Published: 15.03.2023

*Corresponding author: Hasna Aamri

Centre Hospitalier Universitaire Mohammed VI, Marrakesh, Morocco

Abstract

Case Report

Purpose: To assess the symptoms of Vogt-Koyanagi-Harada (VKH) syndrome in Moroccan children. **Methods:** Clinical data were acquired from the medical records of three children with VKH disease at the Marrakech University Children's Hospital. **Results:** Three cases fulfilled the VKH diagnostic criteria. The patients, ranging in age from 4 to 12 years, all had chronic illness. Uveitis was the most common ocular finding. Glaucoma, cataract, posterior synechiae, and subretinal neovascularization were complications for the patients. **Conclusion:** Depending on the long-term consequences, visual results were positive in all of the patients. VKH is uncommon in children, but it can be sight-threatening and requires close monitoring, making it an essential differential diagnosis.

Keywords: Vogt-Koyanagi-Harada (VKH) syndrome, immunosuppressives, pediatric uveitis, biotherapies.

Copyright © 2023 The Author(s): This is an open-access article distributed under the terms of the Creative Commons Attribution 4.0 International License (CC BY-NC 4.0) which permits unrestricted use, distribution, and reproduction in any medium for non-commercial use provided the original author and source are credited.

INTRODUCTION

VKHS (Vogt-Koyanagi-Harada syndrome) is a rare inflammatory autoimmune disease. It is a form of bilateral granulomatous panuveitis with extraocular symptoms [1]. The etiology is unknown, although autoimmunity mediated by T lymphocytes against self-antigens produced in melanocytes is presently the most widely accepted theory; damaging susceptible individual's melanocyte-rich organs such as the eye, middle ear, meninges, and skin [2]. Although VKHS is uncommon in children and usually develops between the ages of 20 and 50, it can induce uveitis in infants, which can lead to blindness. When other causes of uveitis have been ruled out, a VKHS diagnosis is

primarily based on clinical symptoms that are confirmed by diagnostic tests [3]. VKHS has four stages: prodromal, uveitic, convalescent, and recurring. In 2001, a new set of criteria was proposed for its diagnosis (Table 1), and according to the signs present, VKHS is characterised by complete, incomplete, or probable [4]. Treatment includes a high dosage of systemic glucocorticoid treatment that must be gradually decreased. Immunosuppressive medications are routinely utilized, and the most commonly used include cyclosporine, azathioprine, and mofetil mycophenolate. Biotherapies such as infliximab have shown promising outcomes [5].

Table 1: Revised diagnostic criteria for Vogt-Koyanagi-Harada syndrome, adapted from Read *et al.*, [4]

| | |
|---|--|
| 1. No history of penetrating ocular trauma or eye surgery | |
| 2. No clinical or laboratory evidence of other ocular or systemic disease | |
| 3. Bilateral ocular disease (mandatory presence of a or b criteria, depending on the stage of the disease) | |
| a. Early manifestations (1) Diffuse choroiditis (focal areas of subretinal fluid; bullous serous subretinal detachments) (2) With equivocal fundus findings (fluorescein angiography showing focal delayed choroidal perfusion, pinpoint leakage, large placoid areas of hyperfluorescence, pooling of dye within subretinal fluid and optic nerve staining (3) Ultrasonography showing diffuse | b. Late manifestations (1) History suggestive of findings from IIIA, and either both 2 and 3 below, or multiple signs from 3 (2) Ocular depigmentation (sunset glow fundus; Sugiura sign) (3) Other ocular signs (numular chorioretinal depigmentation scars; RPE clumping and/or migration; recurrent or chronic anterior uveitis |

| | |
|---|--|
| choroidal thickening without evidence of posterior scleritis | |
| 4. Neurological/auditory findings | |
| Meningismus | |
| Tinnitus | |
| Cerebrospinal fluid pleocytosis | |
| 5. Integumentary findings (not preceding central nervous system or ocular disease) | |
| Alopecia | |
| Poliosis | |
| Vitiligo | |

Complete VKHS: 1–5 criteria present

Incomplete VKHS: 1–3 criteria present + 4 or 5 present

Probable VKHS: 1–3 criteria present

CASE REPORT (PATIENT A)

4-year-old Moroccan Sahara child with bilateral ocular redness and periodic headaches who has experienced a loss in visual acuity for 2 months. He has no personal or family background. Visual acuity was difficult to measure bilaterally, with alterations in the anterior region due to anterior bilateral uveitis, according to an ophthalmologic examination. Fundoscopy revealed hyperaemia and oedema of the optic disc. Due to 360° irido-crystalline synechiae, OCT was not conducted. The remaining physical examination revealed hypochromic lesions of the skin in lower members and the back, indicating vitiligo (Figure 1) with 2 years of development and poliosis (Figure 2). A neurological examination and cranial MRI indicated no alterations. A spinal puncture revealed that the output pressure, protein levels, and microbiology were all normal. An audiogram was performed in the quest for an acoustic impairment, which revealed no anomalies. Infectious aetiology (tuberculosis, syphilis, Herpes type 1, Hepatitis B and C, HIV, EBV, and

toxoplasmosis) and autoimmune markers (AAN, rheumatoid factor, anti-ANCA, anti-dsDNA, HLA-B27, and HLA-B51) were all negative. In addition to a standard converting enzyme. The diagnosis of VKHS was hypothesized based on clinical, laboratory, and imaging evidence. This is an incomplete type of VKH syndrome. Methylprednisolone (1g/1.73m²/day) was administered intravenously, Begun on the third day and continued for three days followed by oral prednisolone therapy (2 mg/kg/day) and was associated to methotrexate (15 mg/m² every week). Following 60 days of therapy, further examinations revealed clinical improvement and the disappearance of signs of bilateral uveitis. Methotrexate is administered for two years, and oral corticosteroid medication was continued for 6 months with progressive decrease. Following the withdrawal of steroids, he demonstrated a recidive of his hyalite. We gave him full- dose corticosteroid medication as well as azathioprine (2mg/kg/day). Adalimumab (20mg/kg/day) biotherapy was considered.

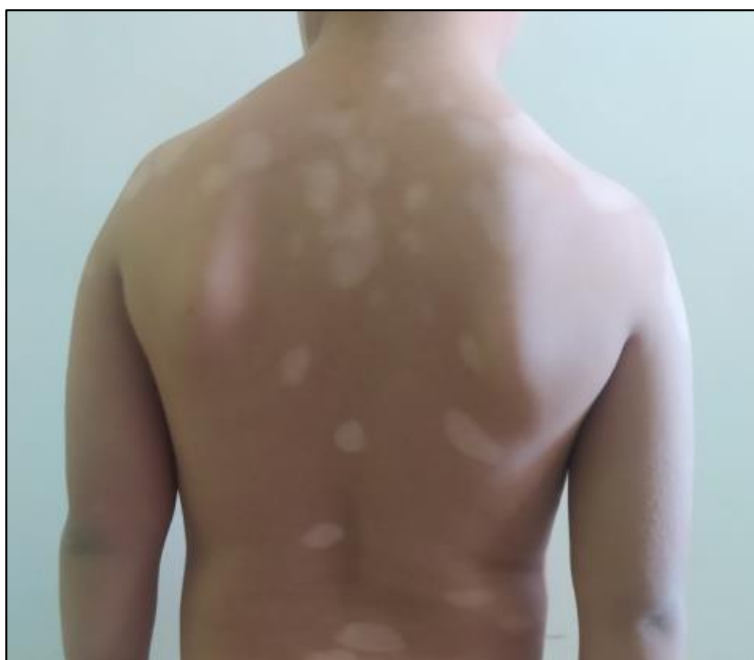

Figure 1: Patient A with vitiligo

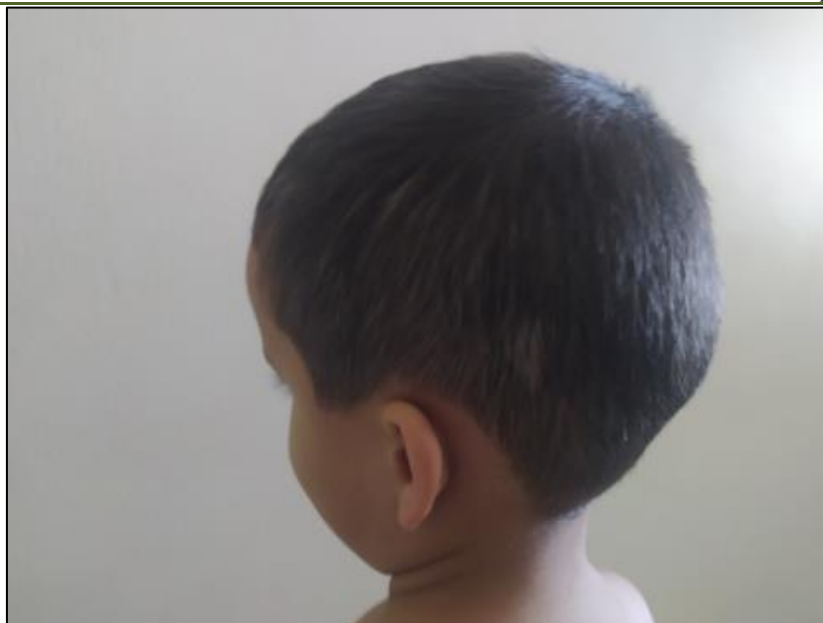

Figure 2: Patient A with poliosis

CASE REPORT (PATIENT B)

A 12-year-old girl was brought to our service for bilateral sight loss, redness, and irritation that had been observed for one month. Her background was ordinary. She had no previous history of eye trauma or illness. She was diagnosed with posterior bilateral uveitis. She had thinning of the internal retinal layers as well as hyperreflectivity of the internal limiting membrane and pre-retinal membrane tugging on the superior vascular arch on the right eye OCT. Retinography revealed pre-papillary and pre-retinal fibrovascular proliferations along with typical vascular abnormalities such as sheathing, occlusion, and unoccupied vessels with diffusion in the pre-retinal neovessels following fluorescein injection (Figure 3, 4).

In the abdomen, she showed achromic macular lesions with polycyclic borders, as well as poliosis lesions. An audiogram and a cerebrospinal fluid testing revealed no abnormalities. The test for infectious aetiology (tuberculosis, syphilis, Hepatitis B and C, HIV, EBV, and toxoplasmosis) and autoimmune markers (AAN, rheumatoid factor, anti-ANCA, anti-dsDNA, ASCA, HLA-B27, and HLA-B51) was negative. It is an incomplete form of VKH syndrome. Intravenous methylprednisolone (30 mg/kg/day) was started and maintained for three days, followed by oral prednisolone (1 mg/kg/day), and following evaluations revealed that the clinical state had improved.

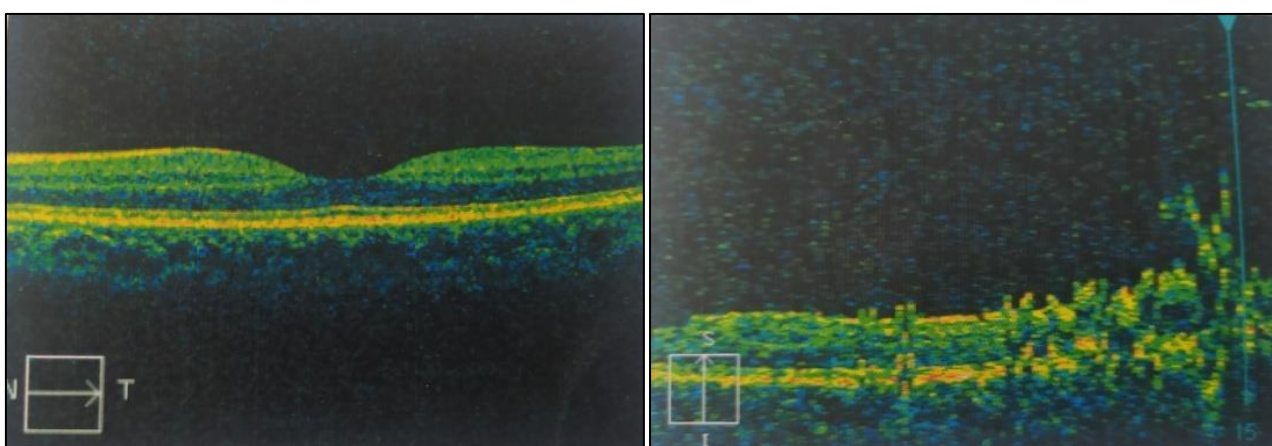


Figure 3 and 4: Macular profile of the right eye abnormal in patient B

CASE REPORT 3 (PATIENT C)

An 8-year-old child with no specific pathological history was hospitalized for recurrent bilateral hyalitis for 3 years, which was exacerbated by glaucoma, which was first indicated by painful and red

eyes. The etiological evaluation was negative. In the face of vitiligo lesions on the posterior face of both hands, as well as on the level of the lower back and both feet, we suspected VKH syndrome. An MRI of the brain and a fluorescein angiography revealed no

abnormalities. The diagnosis of VKH was suggested based on clinical, laboratory, and imaging evidence. He was treated with oral corticosteroid treatment in conjunction with methotrexate, and while he improved ophthalmologically, he still has scar band keratopathy. Following UV treatments, the vitiligo lesions faded.

DISCUSSION

VKH syndrome is an uncommon cause of childhood uveitis that is frequently misdiagnosed. Subretinal fibrosis, posterior synechiae, cataract, and glaucoma are among conditions that can affect the retina. We only had three instances in our department. Among VKH: 1 to 15% begun during childhood [6].

Although VKHS can develop in children, there have been few clinical studies that explain the natural course and prognosis. The authors also discovered few cases in which dermatological indications occurred before to or concurrently with ocular signs, which is not included in the VKHS diagnostic criteria from 2001 (Table 1) [7]. In our investigation, all patients had dermatological signs in addition to ophthalmic manifestations. The presentation of VKH in these children was comparable to that of adults, but more aggressive and susceptible to complications, resulting in a poor visual prognosis [8]. The three cases fulfilled criteria for incomplete VKH. Pediatric patients frequently have more severe ocular consequences from VKH illness than adults. The prognosis of visual function is mostly determined by the time required to diagnose and treat VKHS, hence it is critical to have a clinical suspicion of VKHS [9]. Glaucoma, cataract, synechiae formation, retinal pigment epithelium modifications, retinochoroidal atrophy, or subretinal neovascular membranes are common consequences that can lead to blindness. N. Albaroudi *et al.*, documented complications such as cataract (56.3%), posterior synechiae (87.5%), glaucoma (12.5%), goniosynechiae (12.5%), and bandkeratopathy (12.5%) [10]. In our study, we reported cataract, glaucoma, posterior synechiae and subretinal neovascularization as complications. Inflammation recurrence in children with VKH is unusual and increases the possibility of consequences. They occurred in patients A and B at a rate of 66 %, which is comparable to the results of N. Albaroudi *et al.*, at a rate of 68 % [10]. These results are higher than those published by Martin *et al.*, and Abu El-Asrar *et al.*, who reported 36.4 % and 39.1 %, respectively [11]. The first step in treating VKH syndrome is to administer high-dose systemic corticosteroid therapy, either orally or intravenously, followed by 6 months of oral steroid medication. The method of administration of corticosteroids has little effect on visual prognosis, but the duration of therapy does. To avoid inflammatory relapses, systemic steroids should be administered for at least 6 months and gradually discontinued [12]. In reality, despite its primary role in inflammation management, chronic

corticosteroid medication increases the risk of dependency and induces side effects such as cushing syndrome, hyperglycemia, increased risk of severe infections, and growth retardation, particularly in children. As a result, cortisol sparing and the use of immunosuppressive medications or even biotherapies are required [13]. In our study, The therapy was began in the first 5 days of the symptoms for patients A and B, however it was postponed for patient C due to a delay in consultation. Following the recurrence of the inflammation, patient A was given steroids in addition to methotrexate and azathioprine. Biotherapy is advised, it was delayed because biotherapies are difficult to get, owing to their high cost and poor socioeconomic level. The remaining patients received just steroids. Katsuyama *et al.*, on the other hand, described a 3-year-old kid who had an excellent visual prognosis following intravenous corticosteroid treatment. They did, however, utilize a high dosage of methylprednisolone (30 mg/kg/day) for three consecutive days, followed by oral prednisolone at a daily dose of 0.4 mg/kg, progressively tapered down over a six-month period with an 18-month follow-up period with no recurrence or problems [14]. In refractory instances, Soheilian *et al.*, documented 10 children with VKH syndrome who were effectively treated with oral prednisolone and/or methotrexate, and all improved or kept their visual acuity. As a result, they hypothesized that methotrexate might be beneficial in producing remission in pediatric VKH-associated panuveitis while having few side effects [15]. Martin *et al.*, had satisfactory visual results by using methotrexate in 12 patients (54.6 %), azathioprine in 5 patients (22.7 %), and cyclophosphamide in 2 patients (9.1 %) [16]. Infliximab, a newer therapeutic medication, may be an alternative for treating pediatric VKH. Khalifa *et al.*, observed that infliximab in conjunction with systemic corticosteroids and methotrexate resulted in an outstanding VA outcome with no recurrences [17]. Other biological treatments, such as Rituximab and Adalimumab, have been used successfully to treat VKH illness in children in the literature [18-20].

CONCLUSION

VKH syndrom is uncommon in children and can be difficult to diagnose and possibly blinding, emphasizing the significance of starting high-corticosteroid therapy immediately. These three instances demonstrated that dermatological manifestations can occur before ophthalmological signs, implying that VKH criteria should be updated, and that early treatment can lower the risk of recurrences and consequences. Pediatric patients' life expectancy warrants the early use of immunosuppressive drugs and even biotherapies for greater cortisol sparing and visual function maintenance [20].

CONFLICT OF INTEREST

There is no conflict of interest from any of the authors, and the manuscript has been read and approved by all the authors.

REFERENCES

- Rao, N. A., Gupta, A., Dustin, L., Chee, S. P., Okada, A. A., Khairallah, M., ... & Read, R. W. (2010). Frequency of distinguishing clinical features in Vogt-Koyanagi-Harada disease. *Ophthalmology*, 117(3), 591-599.
- Yıldırım, G., Çavdarlı, C., Özdemir, E. Y., & Alp, M. N. (2021). Vogt Koyanagi Harada syndrome in a 15-year-old girl, steroids side effects and recurrences. *Turkish Journal of Pediatrics*, 63(3), 527-532.
- Nussenblatt, R. B., & Whitcup, S. M. (2010). Uveitis: fundamentals and clinical practice, 4th edn. Mosby Elsevier, Los Angeles.
- Read, R. W., & Rao, N. A. (2000). Utility of existing Vogt-Koyanagi-Harada syndrome diagnostic criteria at initial evaluation of the individual patient: a retrospective analysis. *Ocul Immunol Inflamm*, 8, 227-234.
- Yoshida, A., Tominaga, S., & Kawashima, H. (2016). Juvenile Vogt-Koyanagi-Harada disease in which good visual prognosis was derived from swift and definitive diagnosis. *Case Rep Ophthalmol Med.*, 2016, 7636729.
- Khalifa, Y. M., Bailony, M. R., & Acharya, N. R. (2010). Treatment of pediatricvogt-koyanagi-harada syndrome with infliximab. *Ocul ImmunolInflamm*, 18, 218-22.
- Coutinho, I., Pedrosa, C., Santos, C., Pina, S., Lisboa, M., Bernardo, M., & Prieto, I. (2018). A challenged case of Vogt-Koyanagi-Harada syndrome: when dermatological manifestations came first. *International Ophthalmology*, 38, 793-798.
- Damico, F. M., Kiss, S., & Young, L. H. (2005). Vogt-Koyanagi-Harada disease. *Semin Ophthalmol*, 20, 183-90.
- Soheilian, M., Aletaha, M., Yazdani, S., Dehghan, M. H., & Peyman, G. A. (2006). Management of pediatric Vogt-Koyanagi-Harada (VKH)-associated panuveitis. *Ocular Immunology and Inflammation*, 14(2), 91-98.
- Albaroudi, N., Tijani, M., Boutimzine, N., & Cherkaoui, O. (2020). Clinical and therapeutic features of pediatric Vogt-Koyanagi-Harada disease. *Journal Français d'Ophthalmologie*, 43(5), 427-432.
- Abu El-Asrar, A. M., Al-Kharashi, A. S., Aldibhi, H., Al-Fraykh, H., & Kangave, D. (2008). Vogt-Koyanagi-Harada disease in children. *Eye*, 22(9), 1124-1131.
- Reiff, A. (2020). Clinical Presentation, Management, and Long-Term Outcome of Pars Planitis, Panuveitis, and Vogt-Koyanagi-Harada Disease in Children and Adolescents. *Arthritis Care & Research*, 72(11), 1589-1596. <http://dx.doi.org/10.1002/acr.24056> [In press].
- Khan, F., Zahid, S., Raza, S. S., & Iqbal, M. (2017). A case of Vogt Koyanagi Harada disease in a 16 year old girl. *J Pak Med Assoc*, 67, 1759-1761.
- Katsuyama, A., Kusuhara, S., Awano, H., Nagase, H., Matsumiya, W., & Nakamura, M. (2019). A case of probable Vogt-Koyanagi-Harada disease in a 3-year-old girl. *BMC ophthalmology*, 19, 1-4.
- Soheilian, M., Aletaha, M., Yazdani, S., Dehghan, M. H., & Peyman, G. A. (2006). Management of pediatric Vogt-Koyanagi-Harada (VKH)-associated panuveitis. *Ocular Immunology and Inflammation*, 14(2), 91-98.
- Martin, T. D., Rathinam, S. R., & Cunningham, Jr, E. T. (2010). Prevalence, clinical characteristics, and causes of vision loss in childrenwith Vogt-Koyanagi-Harada disease in South India. *Retina*, 30, 1113-21.
- Khalifa, Y. M., Bailony, M. R., & Acharya, N. R. (2010). Treatment of pediatricvogt-koyanagi-harada syndrome with infliximab. *Ocul ImmunolInflamm*, 18, 218-22.
- Umran, R. M. R., & Shukur, Z. Y. H. (2018). Rituximab for sight-threateningrefractory pediatric Vogt-Koyanagi-Harada disease. *ModRheumatol*, 28, 197-9.
- Jeroudi, A., Angeles-Han, S. T., & Yeh, S. (2014). Efficacy of adalimumabfor pediatric Vogt-Koyanagi-Harada syndrome. *Ophthalmic SurgLasers Imaging Retina*, 45, 332-4.
- Su, E., Oza, V. S., & Latkany, P. (2019). A case of recalcitrant pediatricVogt-Koyanagi-Harada disease successfully controlled withadalimumab. *J Formos Med Assoc*, 118, 945-50.