

Osteosarcoma of mandible with 5 years follows up: Case report and review of literature

Negin Ronasi¹, Mohammad Vahedi², Zahra Abdolkarimpour^{3*}

¹Assistant Professor, Dental Research Center, Department of Oral Medicine, Dental School, Hamadan University of Medical Sciences, Hamadan, Iran.

²Associate Professor, Dental Research Center, Department of Oral & Maxillofacial Medicine, Dental School, Hamadan University of medical sciences, Hamadan, Iran.

³Resident of Oral Medicine, Department of Oral & Maxillofacial Medicine, Dental School, Hamadan University of Medical Sciences, Hamadan, Iran.

***Corresponding author**

Zahra Abdol karimpour

Email: z.abdolkarimpour@gmail.com

Abstract: Osteosarcoma (OS) is a malignant mesenchymal tumor and the most common primary malignant bone tumor. About 6-7% of all OSs occur in the maxillofacial region. OS may arise de novo or subsequent to other conditions. Our report is about a 24-year-old women with the chief complaint of oral mass in the anterior side of the mandible. Histopathological examination showed neoplastic tissue which was suggestive of chondroblastic osteosarcoma. The patient underwent partial mandibulectomy and chemotherapy followed by reconstruction with femoral free flap and prosthodontic rehabilitation. Fortunately after 5 years follow up there is no recurrence. The aim of this report is to show importance of careful diagnosis and treatment planning and to raise awareness of the possibility that Fibro osseous lesions can transform into osteosarcoma.

Keywords: Jaw Osteosarcoma, chondroblastic variant, Fibro osseous lesion.

INTRODUCTION

Osteosarcoma (OS) is a malignant mesenchymal tumor [1] and the most common primary malignancy of bone. It includes approximately 20% of sarcomas but only 5% of the OS occur in jaws [2]. OS of jaws is uncommon and nevertheless its histopathologic similarities with other bones, it has different nature; with lower incidence of metastases and much better prognosis [3]. Cure in osteosarcomas of the jaws has been estimated at 60% to 70% [4]. According to previous studies, while adjuvant chemotherapy may improve early survival, but chemotherapy and radiotherapy appears don't impact long-term survival [5].

CASE REPORT

A 24-year-old female was referred to the oral and maxillofacial Department in December 2010, with the chief complaint of oral mass in the anterior side of the lower jaw which had been slowly increasing in size. She had noticed the nodular expansion two years earlier in the apical region of the right mandibular first and second incisor teeth. A dentist has treated her with recounration when it was 0.5.0.5 cm in diameter, but there was no improvement and there was also increasing in size. The patient didn't have past

hospitalization and systemic problem. The patient's family. History was clear.

The clinical examination showed Asymmetry in face with no history of pain as well as no bleeding, us exudation and paresthesia [Figure 1]. There were no history of fever and weakness. There was no lymphadenopathy in submental, submandibular and cervical lymphnodes. An intraoral examination revealed a sessile nodular lesion with bony hard consistency, extending antero posteriorly from the distal of first incisor to mesial of the first premolar in buccal, and Superior inferiorly, it extended from interdental area to the depth of the buccal vestibular region in diameter of 3*1.5*2 cm [Figure 2]. The expansion of the lingual area was seen in the same region that was covered by intact oral mucosa [Figure 3]. The teeth of area had grade II mobility. Our first clinical diagnosis was central ossifying fibroma. Panoramic view revealed a mixed lesion with ill-defined border with band like PDL widening of adjacent teeth and bodily replacement of canine's root [figure 4]. Periapical radiography showed spike root resorption in central incisor also occlusal view was taken. [figure 5]. Multislice Spiral CT scans with and without contrast revealed an enhancing soft tissue mass about (30.25.30mm) in the right anterior aspect of mandible which was located in both side of

alveolar process. Adjacent bone involvement as permeation appearance and erosion were seen.

Incisional biopsy was taken from these areas. Histopathological examination showed neoplastic tissue consisting of two distinct part include tumor cells arranged in the form of lobules or sheet with numerous surrounding cells with pelomorph and hyper chromatic nuclei and lacunar spaces full of hyaline cartilage and calcification which was suggestive of chondroblastic osteosarcoma and there were undifferentiated tumoral cells in other parts. Whole body bone scan was performed by injection of 20 mci Tc99m_MDP that

revealed a zone of abnormal increased radiotracer activity in the right mandible .There was no clear evidence of skeletal metastasis. Workup for Metastasis such as chest radiograph and abdominopelvic ultrasound was negative and wasn't revealed any metastatic lesions.

The patient underwent partial mandibulectomy under general anesthesia and chemotherapy followed by reconstruction with femoral free flap and prosthodontic rehabilitation. Fortunately after 5 years follow up there is no recurrence [Figure 6].

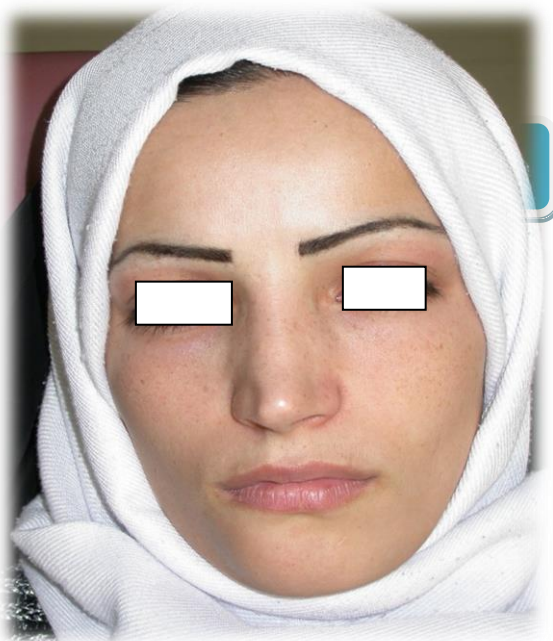

Fig 1: Extra oral examination show Asymmetry in face

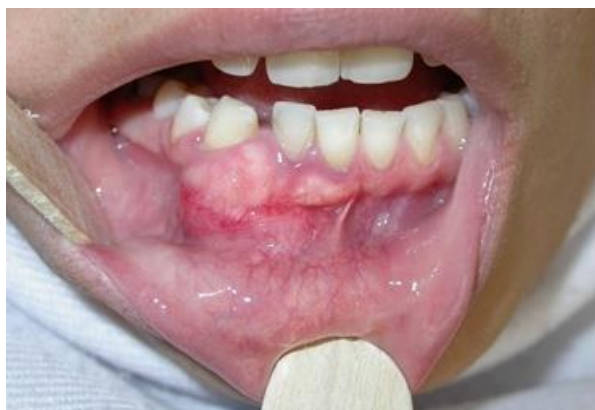

Fig 2: intraoral examination; oral mass in the anterior side of the lower jaw

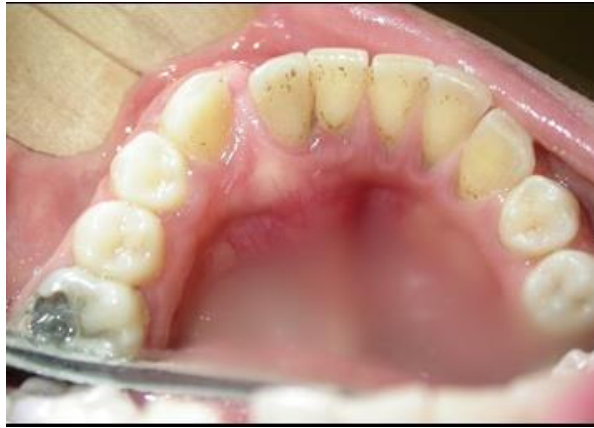

Fig 3: intraoral examination; Lingual aspect

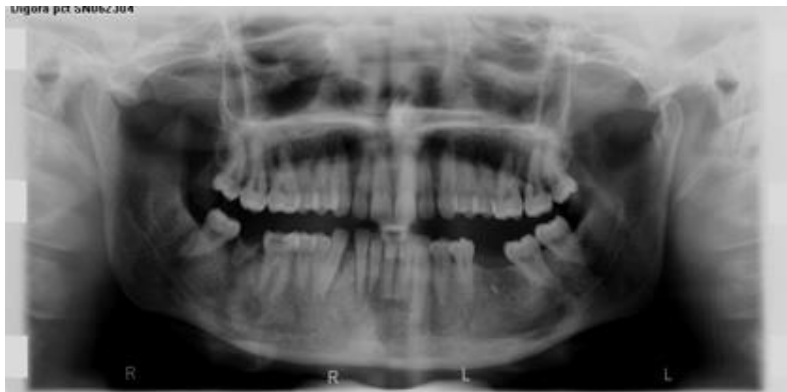

Fig 4: Panoramic view reveals mixed lesion with ill-defined border

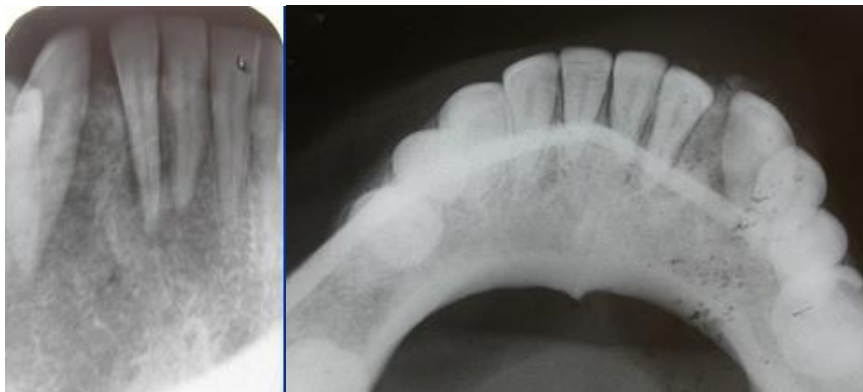


Fig 5: Periapical radiography show spike root resorption in central incisor

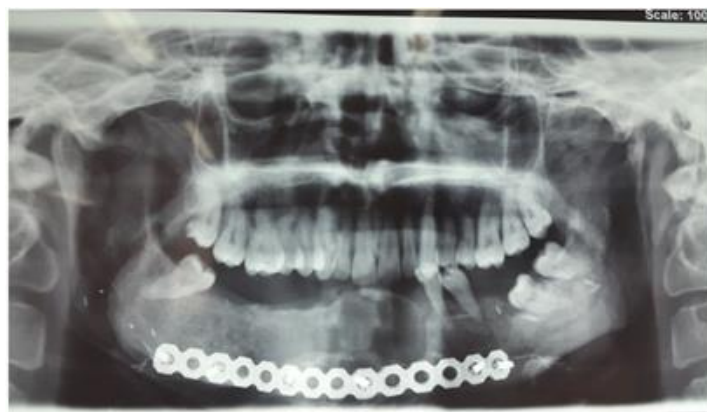

Fig 6: partial mandibulectomy and reconstruction with femoral free flap

DISCUSSION

OS is considered to be a rare lesion occurring in about 1/100,000 persons per year; about 6-7% of all OSs occur in the maxillofacial region[6] Gnathic osteosarcomas should always be considered in the differential diagnosis of expansible jaw lesions that definitive diagnosis of these lesions is considering to clinical, radiographic and pathologic features of each lesion. These lesions may be a reactive or neoplastic lesion, ossifying fibroma, fibrous dysplasia, giant cell granuloma, cysts, benign and malignant neoplasms, and odontogenic tumours[7]. OSs are known according to their areas of origin as conventional type arising within the medullary cavity, intra skeletal osteosarcoma juxta cortical type that arising from the periosteal site [8].

Jaw OSs are usually occur in the third and fourth decades, approximately one decade after their happening in long bones [9]. 60% of JOS occur in males with almost equally rate in the mandible and maxilla [10]. Chindia et al reported 14 cases of jaw osteosarcomas in patients with a mean age of 30 years that The mandible was the most common involved bone and mandibular lesions occurred predominantly in women [11, 12]. Similar to what was observed in our case. Mandibular involvement has a better survival rate than maxillary involvement [13].The tumors of mandible occur more commonly in the posterior site and horizontal ramus, while the tumors of maxilla have been found more frequently in the alveolar ridge, palate and floor sinus of [14].Symphyseal lesion has better prognosis than body, angle or ramus[10].

The most common symptoms that has been observed in the OS of the head and neck region is swelling [14].The occurrence of pain is estimated from 3% to over 80% of patients but generally is less than pain of long bone osteosarcomas. Radiographically, OS usually have poorly defined pattern and irregular destructive bone lesion interspersed with radio opaque material; the radio opaque foci represents the tumor cartilage /or bone producing areas [15].

OS may arise as a de novo lesion or as a subsequent to prior irradiation. It can also arise in pre-existing site of Paget's disease or Fibrous dysplasia. Also trauma is considered as contributing factor [16].There are few and rare reported cases from the concurrent occurrence of fibro osseous lesion and OS and transforming of these lesions without irradiation, like condition that there was in our case that show the importance of careful diagnosis and regular follow-up in patients with these osseous lesions .

Schneider *et al.*; in 1999, reported a case of a 54-year-old black female with mandibular "malignant spindle cell tumor" occurring in florid osseous dysplasia [17]. This report was the first case of

malignancy that arising in a pre-existing cemento-osseous dysplasia (COD).

Cheng *et al.*; in 2002 reported a case of a 72-year-old black female with a OS that had been diagnosed three years earlier with Paget's disease and florid cemento-osseous dysplasia (FCOD) adjacent to pagetoid bone [18].

Melrose and Handlers reported a case of a 36-year-old black female in 2003with a painful swelling in mandible that histopathologic examination revealed it as a high-grade osteosarcoma. This case had been diagnosed three years earlier as FCOD with bignathic presentation [19].

Lopes *et al.*; in 2010, reported a case of 44-year-old black women who presented with chief complaint of a painful swelling of the right mandibular area which was diagnosed as osteosarcoma in a background of FCOD.(20)

These cases have been associated with the florid type of cemento-osseous dysplasia.

Olusanya *et al.*; in 2012 reported two cases of combination of cemento-osseous dysplasia and osteogenic sarcoma in 2012: A 65-year-old Nigerian female with OS on the left side of the jaw and COD on the right side of the jaw and a 45-year-old Nigerian female with the right mandibular progressively increasing swelling and radio opacity within the body of the left mandible [21]. The two last cases associated with the focal subtype of COD.

Lee *et al.*; in 2015 reported a 45-year-old female with initial chief complaint of three-month history of gingival swelling and tooth pain in the left posterior mandible. A histopathological diagnosis of cemento-ossifying fibroma was made. After 3 years fallow up period and treatment of recurrent lesions, there was a transformation into low grade osteosarcoma. This was the first case report of the transformation of these two lesions [22].

Histologically OSs is known according to the cellular pattern as osteoblastic, fibroblastic and chondroblastic. In type of osteoblastic, atypical neoplastic osteoblasts represent considerable variation in size and shape. The chondroblastic type, consists of atypical chondroid regions composed of pleomorphic binucleate cells and fibroblastic type, shows atypical spindle shaped hyper chromatic cells[23].Proportions of osteoblastic and chondroblastic mandibular OS are 46% and 37%, respectively [10].

The present case exhibits features of chondroblastic variant of OS.

According to reports, the prognosis of patients with OS to be better with these factors: Absence of parasthesia, smaller tumor size, adequate surgical removal, a high differential histological grade of the lesion and younger age of the patient. Increase age may be related to recurrence of the treatment [24]. 5 years survival rate for jaw osteosarcomas is 21.5–35% [10]. Prognosis may be dependent on the spread of the tumor at the initial phase of the treatment; lesions less than 5 cm have 25% to 40% survival rate in five-years, while lesions more than 15 cm have approximately zero percent five years survival rate.

The most important intervention in the management of jaws 'osteosarcomas are wide surgical resection with adjuvant chemotherapy and irradiation therapy that these are the primary modes for alleviation of unresectable lesions [25].

CONCLUSION:

The aim of this report is to show importance of careful diagnosis and treatment planning and to raise awareness of the possibility that Fibro osseous lesions can transform into osteosarcoma.

REFERENCES:

1. Baghale K, Motahary P; Osteosarcoma of the jaws: A retrospective study. *ActaMedIran* 2003; 4:113-21.
2. Soares RB, Soares AF, Souza LB, Santos AL, Pinto LP; Osteo sarcoma of mandible initially resembling lesion of dental periapex: A case report. *Braz J Otorhino laryngol* 2005; 71:242-5.
3. Padilla RJ, Murrah VA; The spectrum of gnathic osteosarcoma: caveats for the clinician and the pathologist. *Head Neck Pathol* 2011; 5:92–99.
4. Mendenhall WM, Fernandes R, Werning JW, Vaysberg M, Malyapa RS, Mendenhall NP; Head and neck osteosarcoma. *Am J Otolaryngol* 2011, 32:597–600.
5. Guadagnolo BA, Zagars GK, Raymond AK, Benjamin RS, Sturgis EM; Osteosarcoma of the jaw/craniofacial region: outcomes after multimodality treatment. *Cancer* 2009, 115:3262–3270.
6. Ogunlewe MO, Ajayi OF, Adeyemo WL, Ladeinde AL, James O; Osteogenic sarcoma of the jaw bones: A single institution experience over a 21-year period. *OOOOEndod* 2006; 101:76-81.
7. Sarkar R; Osteoid producing primary lesion at morphologic and biologic interface: Clinical Cases in Mineral and Bone Metabolism 2015; 12(1): 52.
8. Hansen MF; Genetic and molecular aspects of osteosarcoma. *J Musculoskelet Neuronal Interact* 2002; 2:554-60.
9. Chindia ML, Guthua SW, Awange DO, Wakoli KA; Osteosarcoma of the maxillofacial bones in Kenyans. *J Cranio maxillofac Surg* 1998, 26:98–101.
10. Sarkar R; Pathological and clinical features of primary osseous tumours of the jaw. *Journal of Bone Oncology* 2014; 3: 90–95.
11. Nthumba P; Osteosarcoma of the jaws: a review of literature and a case report on synchronous multicentric osteosarcomas. *WJSO* 2012; 10:240-247.
12. Patel SG, Meyers P, Huvos AG, Wolden S, Singh b, Shaha Ar, *et al.*; Improved outcomes in patient with osteogenic sarcoma of the head and neck. *Cancer* 2002; 95:1495-503.
13. Kaur H, Singh A; Osteosarcoma of jaw - Case report and review of literature. *IJMDS*. 2015; 4:653-7.
14. Nirmala SVSG, Sivakumar Nuvvula, Kishore Kumar, Minor Babu, Sandeep Chilamakuri; Osteosarcoma of mandible in a 10-year-old girl. *JISPPd* 2014; 32:74-8.
15. Bianchi SD, boccardi A; radiological aspects of osteosarcoma of the jaws. *Dentomaxillofac radiol* 1999; 28:42-7.
16. Frei C, Bornstein MM, Slauffer E, Fizuka T, Buser D; Osteosarcoma of Maxilla and Maxillary Sinus. A Case Report. *Quintessence Int* 2004; 35:228-233.
17. Schneider LC, Dolinsky HB, Grodjek JE, Mesa ML, Doyle JL; Malignant spindle cell tumor arising in the mandible of a patient with florid osseous dysplasia. *Oral Surg Oral Med Oral Pathol Oral Radiol Endod*. 1999; 88(1):69-73.
18. Cheng YS, Wright JM, Walstad WR, Finn MD; Osteosarcoma arising in Paget's disease of the mandible. *Oral Oncol*. 2002; 38(8):785-92.
19. Melrose R, Handlers J; Osteosarcoma ex florid osseous dysplasia: report of a case. *Oral Surg Oral Med Oral Pathol*. 2003; 96:296.
20. .Lopes M.A, Kim H.s, Mariano F.V, Correa M.B, Rabelo N.T, Vargas P.A; Clinico-Pathologic Conference: Case 1 *Head Neck Pathol*. 2010; 4(4): 329–333.
21. Olusanya AA, Adeyemi BF, Adisa AO; Concurrent cemento-osseous dysplasia and osteogenic sarcoma: report of two cases. *Case Rep Med* 2012: 180561.
22. Lee YB, Kim NK, Kim JY, Kim HJ; Low-grade osteosarcoma arising from cemento-ossifying fibroma: a case report. *J Korean Assoc Oral Maxillofac Surg*. 2015; 41(1):48-51.
23. Nissanka EH, Amaratunge EA, tilakaratne WM; Clinico pathological analysis of osteosarcoma of jaw bones. *Oral Dis* 2007; 13:82-87.
24. Daw Nc, Mahmoud HH, Meyer WH, Jenkins JJ, Kaste Sc, Poquette cA, *et al.*; bone sarcomas of the head and neck in children: the StJude children's research Hospital experience. *cancer* 2000; 88:2172-80.
25. Amaral MB, Buchholz I, Freire-Maia B, Reher P, de Souza PE, Marigo Hde A, *et al.*; Advanced osteosarcoma of the maxilla: a casereport. *Med Oral Patol Oral Cir Bucal* 2008; 13:E492–E495.