

## **Adenosquamous Carcinoma Colon – An Aggressive and Rare Neoplasm**

**Dr. Indrani K<sup>1</sup>, Dr. Kalyani R<sup>2</sup>, Dr. Vidya Bhat<sup>3</sup>**

<sup>1</sup>Assistant professor, <sup>2</sup>Professor, <sup>3</sup>Associate professor, Department of Pathology, MVJMC & RH, Hoskote, Bangalore, Karnataka, India

### **\*Corresponding author**

Dr. Indrani K

Email: [indranipramodh@gmail.com](mailto:indranipramodh@gmail.com)

---

**Abstract:** Adenosquamous carcinoma colon is a rare neoplasm of colon and is said to have an aggressive course and thus poorer prognosis. Here we have described a case of adenosquamous carcinoma colon in an elderly female patient, presenting with typical features of a colonic malignancy, but with a rapidly deteriorating clinical course and liver metastasis.

**Keywords:** adenosquamous carcinoma, colonic malignancy.

---

### **INTRODUCTION**

Adenosquamous carcinoma, described as neoplasm comprising of adenocarcinoma and squamous cell carcinoma, is an extremely rare entity. The various organs in which it has been reported include lung, esophagus, stomach, duodenum, gallbladder, pancreas and colorectum [1]. Incidence of adenosquamous carcinoma of the colon and rectum is as low as 0.06% to 0.18% [2]. Herxheimer reported the first case of adenosquamous carcinoma cecum in 1907. Both males and females are equally susceptible to this malignancy [3].

Right and transverse colon are the commonest sites of colorectal adenosquamous carcinoma while it is rarely seen in sigmoid and descending colon [2]. The mean age at presentation is 62.5 years. Adenosquamous carcinoma colon has been reported to have an extremely aggressive course and poor prognosis than invasive adenocarcinoma alone [3].

### **CASE REPORT**

A 57 year old female presented to the surgery department with history of intermittent bleeding per rectum for the past four months and constipation for the past three days. She also claimed to have suffered a significant weight loss in the past few months which was associated with loss of appetite as well. Her family history and past history were unremarkable. On clinical examination, patient had pallor, the other vital parameters were normal.

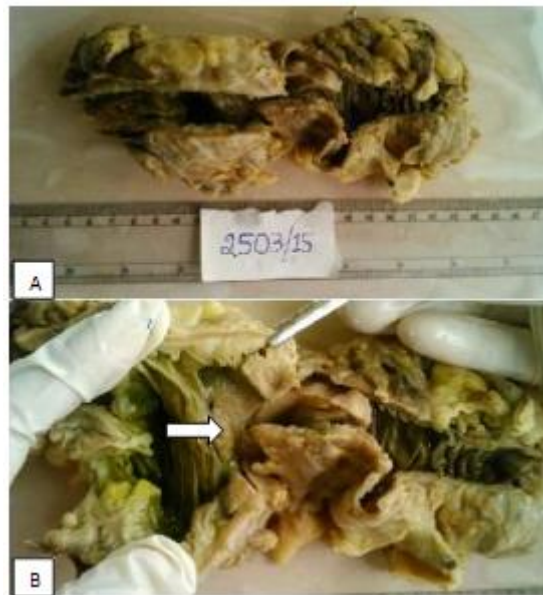
Colonoscopy was performed which revealed an ulcerated mass in the ascending colon. An incisional biopsy taken from the mass was reported as adenocarcinoma colon. Abdominal ultrasound showed

multiple targetoid lesions in the liver, probably metastases.

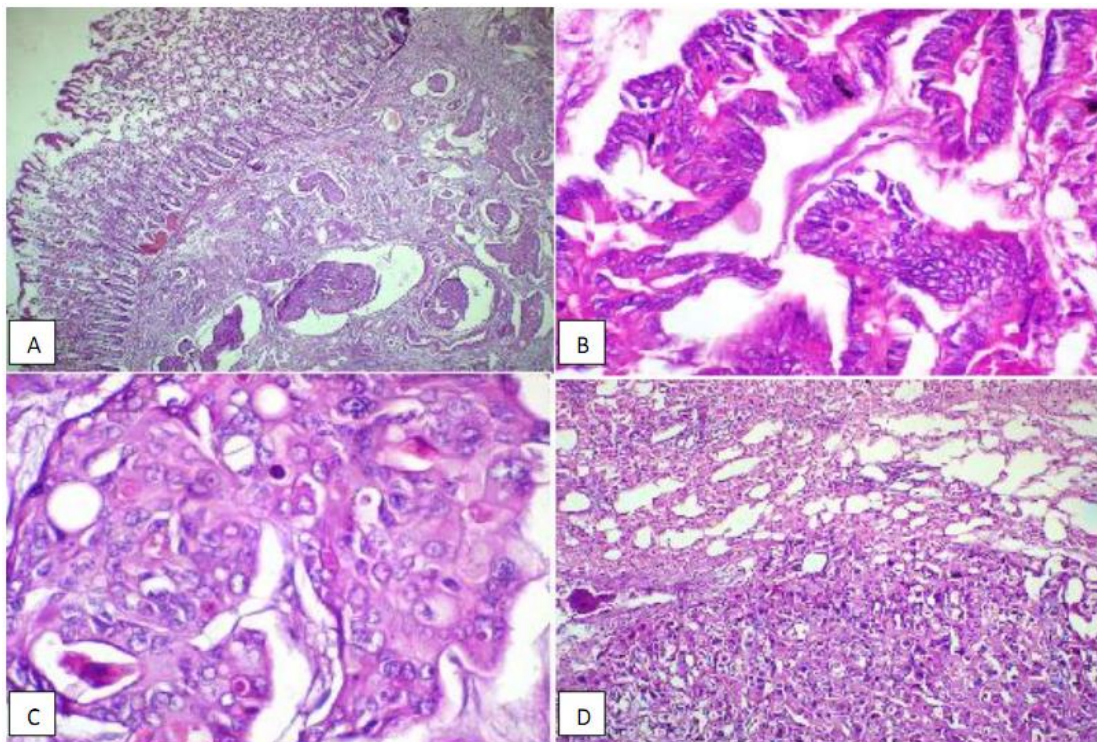
She was then posted for laparotomy and a right hemicolectomy was performed. Prior to laparotomy, an ultrasound guided liver biopsy was also done. Both the specimens were submitted for histopathological examination.

Grossly, the hemicolectomy specimen measured 22 cm in length. On opening, there was a circumferential ulcer measuring 2.5 cm, which was 9 cm from the proximal surgical margin and 10.5 cm from the distal surgical margin. The mucosa adjacent to the lesion appeared normal.

Microscopically, the tumour showed both adenocarcinoma and squamous cell carcinoma components. Both the components were moderately differentiated. The squamous component did not show any keratin pearl formation. Adenocarcinoma component showed tumour cells in acinar pattern with intracellular mucin. Both the components were admixed with each other. The tumour involved the entire thickness of the colonic wall i. e the mucosa, submucosa, muscularis externa and the serosal layer with occasional tumour emboli in the vessels. The proximal and distal surgical margins were free from tumour. No lymph nodes were retrieved from the specimen. Sections studied from the liver biopsy also showed tumour deposits having similar histomorphology as the tumour in the colon. Therefore AJCC (American Joint Committee on Cancer) class of T3NxM1 was given. The patient was administered chemotherapy following hemicolectomy.



**Fig-1: A) Hemicolectomy specimen; B) Circumferential ulceration (arrow)**



**Fig-2: A) Colonic mucosa with tumour. 10X H&E; B) Areas showing adenocarcinoma morphology. 40X H&E; C) Focus of squamous cell carcinoma , with extracellular keratin deposits in the tumour. 40X H&E; D) Metastatic deposits in liver. 10X H&E**

## DISCUSSION

Adenosquamous carcinoma and squamous cell carcinoma colon are rare clinical entities. WHO defines adenosquamous carcinoma as, carcinoma consisting of both adenocarcinoma and squamous cell carcinoma components in different proportions. There may be transitional area between the two components or they may be separate [1].

The commonest cause of squamous histomorphology in colon is metastatic deposits, which have to be ruled out before the diagnosis of primary adenosquamous or squamous cell carcinoma colon [4]. In our patient, a thorough clinical and radiological examination did not reveal any additional masses other than the colonic and liver lesions. Therefore the squamous morphology noted in the colonic mass can be definitively said to be of colonic origin.

According to Williams GT *et al*, one of the criteria for the diagnosis of primary colorectal adenosquamous carcinoma is a colonic tumour arising atleast eight cm above the dentate line [6]. In our case the lesion was situated in the ascending colon and thus distant from the dentate line. The diagnosis of adenosquamous or squamous cell carcinoma colon also requires the exclusion of squamous cell lined fistulous tract which can initiate an adenosquamous or squamous cell carcinoma colon [5]. Clinical examination of our patient did not show any perianal or colocutaneous fistulous tracts.

Numerous theories have been proposed to explain the colonic origin of squamous component in adenosquamous carcinoma colon; however none of them have been adequately investigated or proven. Some of the theories are malignant transformation of embryogenic colonic ectodermal tissue, multidirectional differentiation of endodermal pluripotent stem cells, squamous metaplasia of glandular intestinal mucosa, transformation of in situ adenocarcinoma or colonic adenoma into malignant squamous cells and also repeated destruction of glandular epithelium by deleterious influences like radiation with loss of ability of basal cells to differentiate normally [2]. Ulcerative colitis and schistosomiasis have been noted in association with colorectal adenosquamous carcinoma, suggesting chronic inflammation as a contributing factor [7]. However our case did not show features of inflammatory bowel disease in the surrounding colonic mucosa, either grossly or microscopically.

Colorectal adenosquamous carcinomas usually present in the 6<sup>th</sup> to 7<sup>th</sup> decade of life with a mean age of 59 years [4]. In a study conducted by Masoomi *et al*, colorectal adenosquamous carcinomas were noted more often in individuals younger than 60 years, when compared to cases of adenocarcinoma colon which presented at a later age [3]. Our patient was aged 57 years, which is a relatively early age of presentation for a colonic malignancy.

The spectrum of clinical manifestations of adenosquamous carcinoma colon are quite similar to colonic adenocarcinoma, which include change in bowel habits, pain abdomen, malena (bleeding per rectum) or weight loss [2]. Similarly our patient presented with history of bleeding per rectum, impending signs of bowel obstruction i. e constipation and also significant weight loss in a short span of few months.

Few of the early studies done by Cagir *et al*, found rectum (excluding the distal eight cm) to be most common site of colorectal adenosquamous carcinoma [10]. However population based studies carried out by Masoomi H *et al*, Frizelle *et al*, Kontozoghon and Moyana showed right colon to be the commonest site of

adenosquamous carcinoma [3, 8, 9]. In our case the tumour was present in the ascending colon.

Colorectal adenosquamous carcinoma has an aggressive course and remains a therapeutic challenge [7]. The squamous component of colorectal adenosquamous carcinoma has an increased potential for metastases, therefore leading to worse prognosis [4]. Masoomi *et al* showed that compared to adenocarcinoma, adenosquamous carcinoma colon was associated with higher rate of advanced disease at presentation, explaining the higher mortality rates observed for adenosquamous carcinoma colon [3]. Cagir *et al* reported the rate of regional metastases and distant metastases to be 46% and 42.4% respectively for colorectal adenosquamous carcinoma. The overall 5 year survival rate was only 31% for adenosquamous carcinoma compared to 66% for adenocarcinoma colon [10]. In agreement with the findings of these authors, our patient also presented in an advanced stage with distant metastases to liver. Considering the duration of patient's illness which was only four months, the tumour seems to have had an aggressive course. The patient is on chemotherapy following the hemicolectomy; further course needs to be followed up. Associated ulcerative colitis is said to have a worst prognosis, however our patient did not have features of ulcerative colitis, either clinically or histomorphologically.

## CONCLUSION

In conclusion, we have reported this case to highlight and signify the aggressive behaviour of a rare type of colonic malignancy. Management and overall prognosis of colorectal adenosquamous carcinoma depends on the knowledge of this entity and most importantly accurate histopathological diagnosis. Early detection and radical management including therapeutic modalities like chemotherapy may improve the clinical outcome in these cases.

## REFERENCES

1. Hsueh C, Chen ML, Liao CY, Huang YC, Ho SY, Lee KW, Chou CT; Adenosquamous Carcinoma of the Duodenal Third Portion. *J Radiol Sci.*, 2011; 36: 119-123
2. Shafaghi A, Askari K, Ashoobi MT, Ghanaei FM; Adenosquamous carcinoma of the sigmoid colon: a case report and review of literature. *Int J Clin Exp Med.*, 2013; 6(5):390-392
3. Masoomi H, Ziogas A, Lin BS, Barleben A, Mills S, Stamos MJ, Zell JA; Population-Based Evaluation of Adenosquamous Carcinoma of the Colon and Rectum. *Dis Colon Rectum*, 2012; 55(5): 509–514
4. Abdalla MI, Cornish C, Taboada S, Kothari S, Doshi R, Kothari TH, Kaul V; Adenosquamous Carcinoma of the Cecum: A Rare but Aggressive Form of Colonic Neoplasia. *Fam Med Med Sci Res*, 2014; 3:4

5. Kang DB, Oh JT, Jo HJ, Park WC; Primary adenosquamous carcinoma of the colon. *J Korean Surg Soc* 2011;80:31-35
6. Williams GT, Blackshaw AJ, Morson BC; Squamous carcinoma of the colorectum and its genesis. *J Pathol.*, 1979; 129: 139-147.
7. Qiang LI, Shan HX; Adenosquamous carcinoma of colon and rectum. *Chinese Journal of Cancer Research*, 2000; 12(3):234
8. Michelassi F, Mishlove LA, Stipa F, Block GE; Experience at the University of Chicago, review of the literature, report of two cases. *Dis Colon Rectum.*, 1988; 31:228–35.
9. Kontozoglou TE, Moyana TN; Adenosquamous carcinoma of the colon—an immunocytochemical and ultrastructural study: report of two cases and review of the literature. *Dis Colon Rectum.* 1989; 32:716–21.
10. Cagir B, Nagy MW, Topham A, Rakinic J, Fry RD; Adenosquamous carcinoma of the colon, rectum, and anus: epidemiology, distribution, and survival characteristics. *Dis Colon Rectum*, 1999; 42:258-63.