

## Laryngeal Neuroendocrine Tumour: A Rare Case Report and Review of Literature

Dr. Hetal Marfatia, Dr. Ratna Priya, Dr. Nilam U. Sathe, Dr. Karthik Krishnan

Department of E.N.T, Seth G.S. Medical College and K.E.M Hospital, Mumbai, Maharashtra, India

### \*Corresponding author

Dr. Ratna Priya

Email: [ratnapriya01@gmail.com](mailto:ratnapriya01@gmail.com)

---

**Abstract:** Neuroendocrine tumours consist of diverse group of neoplasms. They are the most common type of non-squamous laryngeal malignancies (0.6-1%) and mainly affect males. Atypical carcinoid is the most common type and typical carcinoid being the rarest. A 60 year male patient presented to the ENT OPD with the chief complaint of irritation in the throat and foreign body sensation since past 6 months. He was a chronic smoker. On indirect laryngoscopy and 70 degree scopy there was a single well defined smooth globular mass over right arytenoid. Both the vocal cords were mobile. Rest of the larynx was normal and there was no pooling of saliva. Neck examination revealed no lymphadenopathy. Wide local excision was done and histopathology was suggestive of neuro endocrine tumour with immunohistochemistry suggestive of cells expressing chromogranin and synaptophysin diffusely and Ki67 was 10-12%. Tumour margins were free. Postoperative 70 degree scopy was absolutely normal with no residual lesion. The first atypical laryngeal carcinoid was described by Goldmann et al in 1969. They are characterised into neural (Paraganglioma) and epithelial types (atypical carcinoid, typical carcinoid, small cell neuroendocrine carcinoma and large cell neuroendocrine carcinoma). Most common site of involvement in larynx is supraglottis. Clinical manifestations include dysphagia, hoarseness, odynophagia, dyspnoea and haemoptysis. The definitive diagnosis depends on histopathology according to the histological and immunohistochemistry features of the tumour type. The treatment of choice in atypical carcinoid is wide local excision or supraglottic laryngectomy ( as most tumours are supraglottic in location). Laryngeal neuroendocrine tumours of the larynx are extremely uncommon. Multidisciplinary approach is required to treat the tumours efficiently.

**Keywords:** neuroendocrine tumors, larynx, carcinoid, diagnosis.

---

### INTRODUCTION

Neuroendocrine tumours consist of diverse group of neoplasms. They are the most common type of non-squamous laryngeal malignancies (0.6-1%) and mainly affect males [1]. The biological behaviour of different tumour types show considerable variations. Broadly depending on their type of origin they are divided into epithelial and neural types. The epithelial type of neuroendocrine carcinoma are further sub classified into well differentiated (Typical carcinoid, grade 1), moderately differentiated (Atypical carcinoid, grade 2) and poorly differentiated (small cell neuroendocrine carcinoma, grade 3) [2]. Atypical carcinoid is the most common type and typical carcinoid being the rarest [3, 4]. Neural type consists of paragangliomas. Here we present a case report of neuroendocrine tumour of larynx and review of literature.

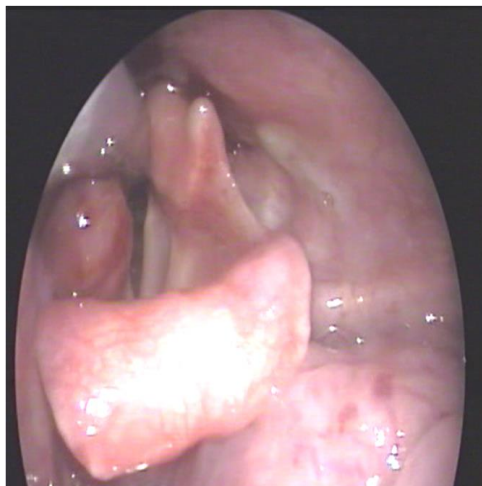
### CLINICAL CASE

A 60 years elderly gentleman who was a chronic smoker (2 packs of cigarette per day for the past 30 yrs) presented to the ENT OPD of KEM hospital with the chief complaint of irritation in the throat and foreign body sensation since past 6 months. He had

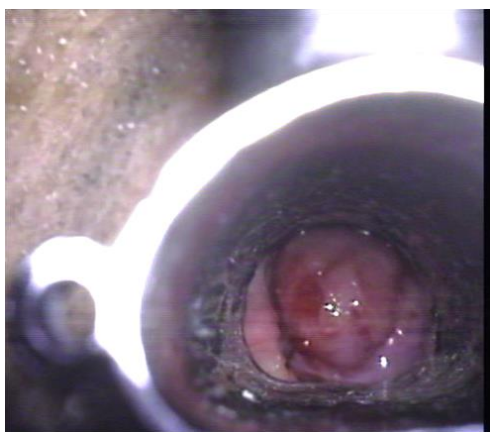
been smoking. Surprisingly, there was no history suggestive of change in voice, respiratory difficulty, and difficulty in swallowing, cough, aspiration or any significant loss of weight. On indirect laryngoscopy and 70 degree scopy there was a single well defined smooth globular mass over right arytenoid. Both the vocal cords were mobile. Rest of the larynx was normal and there was no pooling of saliva. Neck examination revealed no lymphadenopathy.

Microlaryngoscopic examination revealed smooth well defined mass attached to the arytenoid and not involving the surrounding structures. Wide local excision was done and histopathology was suggestive of tumour consisting of cells arranged in nests with abundant cytoplasm with irregular hyperchromatic nuclei with immunohistochemistry suggestive cells expressing chromogranin and synaptophysin diffusely and Ki67 was 10-12%. Tumour margins were free. Postoperative 70 degree scopy was absolutely normal with no residual lesion. Post operatively, based on the histopathological findings the patient was referred to the endocrine department where a complete disease workup was performed. Physical and radiological evaluation (MRI head and neck and whole body CT

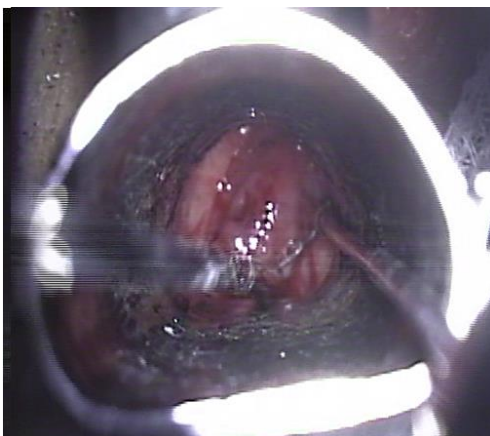
scan) ruled out any associated neuroendocrine tumour and paragangliomas in the rest of the body. Circulating levels of vanillyl mandelic acid and 5-hydroxyindoleacetic acid (5-HIAA) were within the normal limits. The patient was under follow up for six months and there was no recurrence.



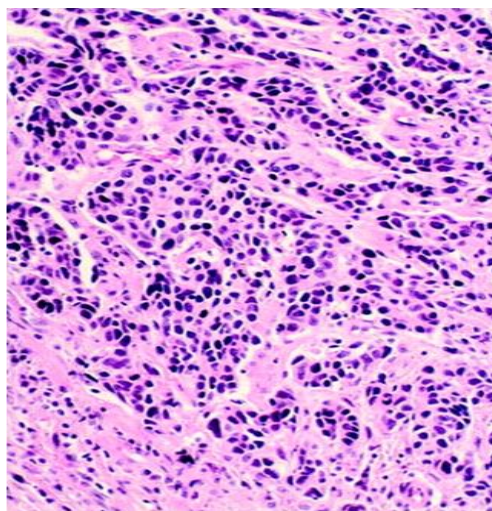
**Fig-1: Pre-operative 70 degree scopy showing a single well defined smooth globular mass over right arytenoid**



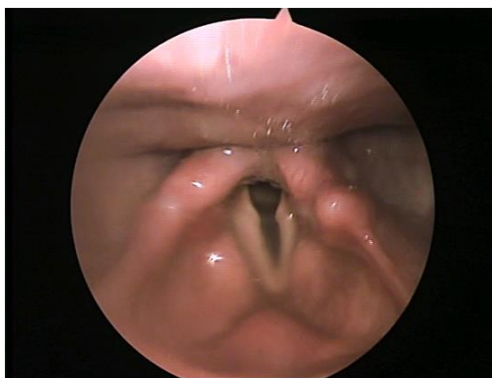**Fig-2: Intra operative microlaryngoscopic image of the same mass**



**Fig-3: Intra operative microlaryngoscopic view depicting mass excision**



**Fig-4: Histopathology image showing grade 2 neuroendocrine tumour showing cells arranged in nests with abundant cytoplasm with irregular hyperchromatic nuclei**



**Fig-5: Post-operative 70 degree scopy showing complete excision of the lesion**

#### DISCUSSION

The overall incidence of primary laryngeal malignancies range from 2-5% of all carcinomas. Among these 99% are squamous varieties. In 1955 Blanchard and Saunders reported the first neural type of laryngeal neuroendocrine carcinoma [5]. The first atypical laryngeal carcinoid was described by Goldmann et al in 1969 [6]. It is considered to be 3 times more common in males' average age being 50-70 yrs [7]. Associated smoking history is found in up to 70% of patients [8].

They are characterised based on their pathological features into neural (Paraganglioma) and epithelial types (atypical carcinoid, typical carcinoid, small cell neuroendocrine carcinoma and large cell neuroendocrine carcinoma). Most common site of involvement in larynx is supraglottis (up to 90% being present in the aryepiglottic fold, arytenoids and epiglottis) [7]. Clinical manifestations depend on the extent and site of disease and may consist of dysphagia, hoarseness, odynophagia, dyspnoea and haemoptysis. The course of the disease varies according to type of

tumour. Tumours grossly appear as sub mucosal masses (polypoidal, pedunculated, or nodular) varying in size from 0.3 to 4 cm. In our case also the patient was a chronic smoker and reported to us only with the complaint of foreign body sensation in throat. Since 70 degree scopy revealed a well-defined globular smooth swelling over the right arytenoid, so we decided to do an excision biopsy of the lesion.

The definitive diagnosis depends on histopathology according to the histological, ultra structural and immunohistochemistry features of the tumour type. Features suggestive of NET are neurosecretory cytoplasmic granules, cells with a variable degree of pleomorphism and organized in nests, cords, trabeculae, glands or rosette-like structures, sub mucosal origin of the neoplasm, evidence of mucin (PAS+) and immunohistochemical positivity for neuroendocrine markers such as chromogranin, NSE, synaptophysin and neurofilaments<sup>[2,3]</sup>. Oncocytic, oncocytoid, mucinous and amyloid changes, focal “Zellballen” rosettes may also be found. Since typical and atypical carcinoid show similar features at histochemical, immunohistochemical and ultra-structural evaluation, the differential diagnosis is mainly based on microscopic characteristics (i.e., the presence of mitosis, necrosis or cellular pleomorphism is strongly suggestive of atypical carcinoid) [4]. In our case histopathology revealed tumour cells arranged in nests with abundant cytoplasm with irregular hyperchromatic nuclei with immunohistochemistry suggestive cells expressing chromogranin and synaptophysin diffusely suggestive of grade 2 neuroendocrine tumour (atypical carcinoid) and Ki67 was 10-12%. Post operatively, based on the histopathological findings the patient was referred to the endocrine department where a complete disease workup was performed. Physical and radiological evaluation (MRI head and neck and whole body CT scan) did not reveal any metastasis or associated neuroendocrine tumour and paragangliomas in the rest of the body. Circulating levels of vanillylmandelic acid and 5-hydroxyindoleacetic acid (5-HIAA) were within the normal limits. The patient was under follow up for six months and there was no recurrence.

The treatment of choice in atypical carcinoid is wide local excision or supraglottic laryngectomy (as most tumours are supraglottic in location) [9]. As there seems to be high incidence of involvement of cervical nodes, elective neck dissection appears to be warranted<sup>4</sup>. Removal of level IIA and level III only is adequate for elective surgical treatment of the neck in supraglottic and glottic tumors [10]. Although previously it was considered that adjuvant radiation and chemotherapy were ineffective in the management of this malignancy [11]. Gillenwater *et al* [12] described that a few patients with atypical carcinoid tumors did respond to these modalities, suggesting the advantage of combined approach for at least some patients.

The clinical behaviour of an atypical carcinoid tumour is aggressive and an unfavourable course is observed when there are lymphatic emboli or when the Ki67 index is higher than 5% [13]. Soga *et al* [14] described finding metastases in 66.7% of 199 cases of atypical carcinoid tumour of the larynx. In 2003, Soga [15] reported that the 5-year survival rate for this tumour was 46.7%. In 2007, Ebihara *et al* [16] collected 33 cases of laryngeal carcinoid (94% atypical carcinoid tumors and 6% typical carcinoid) in Japan. The 3-, 5-, and 10-year survival rates of the patients were 58.5%, 36.5%, and 12.2%, respectively. Thus, the survival rate decreased slowly with the passage of time. In 2004, Soga *et al* [14] reported a 5-year survival rate of small cell neuroendocrine carcinomas to be 7.7%.

The other subdivisions of laryngeal neuroendocrine tumours include small cell neuroendocrine carcinoma, typical carcinoid and paragangliomas. Small Cell Neuroendocrine Carcinoma also present as sub mucosal masses of 0.5-4 cm size and histological categorisation consist of oat cell, intermediate, and combined types. The oat cell type comprises of sheets of small cell with hyperchromatic nuclei and scant cytoplasm frequently associated with rosette formation, cell necrosis and mitotic activity. The intermediate cell type shows identical growth pattern except that the cells are somewhat larger, more polygonal, spindle shaped, or fusiform with prominent cytoplasm. The combined type (very rare), the shows features of both small cell neuroendocrine carcinoma and squamous cell carcinoma or adenocarcinoma. These may be immunoreactive with cytokeratins, EMA, CEA, and with other general neuroendocrine markers, including chromogranin, CD56, CD57, synaptophysin, neuropeptides, including calcitonin, somatostatin, adrenocorticotrophic hormone, bombesin, and serotonin [2].

Paraganglioma, even present as red or blue sub mucosal mass of 1 to 6 cm in size, being firm and rubbery with a red or brown cut surface. Histologically, consist of 2 cell types, chief cells and sustentacular cells. Chief cells are polygonal cells with inconspicuous nuclei and eosinophilic cytoplasm, arranged into a characteristic “Zellballen” pattern. Around the edge of the “Zellballen” is the second type of cell. These are the slender, spindle-shaped sustentacular cells and are highly vascular tumours. LNN can be confused with other neoplasms such as adenocarcinoma not otherwise defined, acinic cell carcinoma, basaloid squamous cell carcinoma, solid type of adenoid cystic carcinoma, poorly differentiated squamous cell carcinoma, undifferentiated carcinoma, amelanotic malignant melanoma, medullary thyroid carcinoma, lymphoma, hemangiopericytoma, and others [17].

Atypical carcinoid is also differentiated from paraganglioma by immunohistochemical staining for



epithelial markers such as carinoembryonic antigen, epithelial membrane antigen and cytokeratins. S-100 positivity may not always be associated with paraganglioma but rarely may also be present in atypical carcinoid and other laryngeal tumours [4]. Typical and atypical carcinoid usually stains positively for calcitonin and paragangliomas show negative for the same [2, 4]. Though paragangliomas show raised levels of urinary catecholamine, vanillylmandelic and homovanillic acid; increased levels of 5-HIAA, NSE and CgA can be diagnostic for carcinoid. Octreotide Scanning with Indium-111 pentetretotide may be suggestive of somatostatin receptors in tumour cells that can be amenable to radio metabolic treatment [18]. NETs of the larynx are rarely associated with clinically evident hormonal activity and elevated levels of circulating catecholamines and their derivatives, calcitonin and urinary 5-HIAA, are uncommon, mostly due to the reduced or absent secretion or release of hormonal substances with qualitative or quantitative anomalies [19]. The Paraneoplastic syndromes that are associated with all subtypes except paraganglioma [20] include carcinoid syndrome (<2%), myasthenic syndrome of Eaton-Lambert, Schwartz-Bartter syndrome and Cushing's syndrome [3, 4].

The treatment for local typical carcinoid and paraganglioma consists of wide local excision, but loco regional lymph node dissection is not indicated because metastatic lymph node involvement is rare [4, 20].

Small cell neuroendocrine neoplasm of the larynx has the worst prognosis, cervical and distant metastases are seen at the time of diagnosis, with five-year survival rates of 5% [21]. Systemic chemotherapy combined with radiation therapy has been suggested as a primary treatment modality for laryngeal small cell carcinoma [22].

The biological behaviour and prognosis of laryngeal NETs vary widely according to the histological tumour type: typical carcinoid and paragangliomas have a smouldering clinical course and rarely metastasize, atypical carcinoid show an intermediate behaviour, while small-cell and large-cell neuroendocrine carcinomas are very aggressive tumors [23]. The most frequent sites of metastatic involvement are lymph nodes, bone, skin, liver and lung. Soga *et al* [13] observed that 33.3% of 42 patients with typical carcinoid of the larynx also developed metastases.

## CONCLUSION

Hence we conclude that laryngeal neuroendocrine tumours of the larynx are extremely uncommon. High index of clinical suspicion is required to diagnose the tumour. Multidisciplinary approach is required to treat the tumours efficiently and effectively.

## REFERENCES

1. Alujevic A, Juric G, Separovic R, Kruslin B; Unusual features of metastatic atypical carcinoid of the larynx. *Eur Arch Otorhinolaryngol.*, 1998; 255: 318-321.
2. Wenig BM, Hyams VJ, Heffner DK; Moderately differentiated neuroendocrine carcinomas of the larynx: a clinicopathologic study of 54 cases. *Cancer*, 1988; 62:2658–2676.
3. Soga J, Osaka M, Yakuwa Y; Laryngeal endocrinomas (carcinoids and relevant neoplasms): analysis of 278 reported cases. *J Exp Clin Cancer Res.*, 2002; 21: 5-13.
4. Ferlito A, Barnes L, Rinaldo A, Gnepp DR, Milroy CM; A review of neuroendocrine neoplasms of the larynx: update on diagnosis and treatment. *J Laryngol Otol.*, 1998; 112: 827-834.
5. Blanchard CL, Saunders WH; Chemodectoma of the larynx: case report. *Arch Otolaryngol.*, 1955; 61:472–474.
6. Goldman NC, Hood CI, Singleton GT; Carcinoid of the larynx. *Arch Otolaryngol.*, 1969; 90:91–93.
7. Machens A, Holzhausen HJ, Dralle H; Minimally invasive surgery for recurrent neuroendocrine carcinoma of the supraglottic larynx. *Eur Arch Otorhinolaryngol.*, 1999; 256: 242-246.
8. Woodruff JM, Senie RT; Atypical carcinoid tumor of the larynx. A critical review of the literature. *ORL J Otorhinolaryngol Relat Spec.*, 1991; 53: 194-209.
9. Ferlito A, Devaney KO, Rinaldo A; Neuroendocrine neoplasms of the larynx: advances in identification, understanding and management. *Oral Oncol.*, 2006; 42: 770–788.
10. Ferlito A, Rinaldo A, Silver CE, Robbins KT, Medina JE, Rodrigo JP, Shaha AR, Takes RP, Bradley PJ; Neck dissection for laryngeal cancer. *Journal of the American College of Surgeons*, 2008; 207(4):587-93.
11. Goldman NC, Katibah GM, Medina J; Carcinoid tumors of the larynx. *Ear Nose Throat J.*, 1985; 64:130–134.
12. Gillenwater A, Lewin J, Roberts D, El-Naggar A; Moderately differentiated neuroendocrine carcinoma (atypical carcinoid) of the larynx: a clinically aggressive tumor. *Laryngoscope*, 2005; 115:1191–1195.
13. Oukabli M, Blechet C, Harket A, Gaillard F, Garand G, Fetissof F; Carcinome atypique de l'aryte'noir'de: a` propos de six observations. *Ann Pathol.*, 2008; 28:2–8.
14. Soga J, Ferlito A, Rinaldo A; Endocrinocarcinomas (carcinoids and their variants) of the larynx: a comparative consideration with those of other sites. *Oral Oncol.*, 2004; 40:668–672.
15. Soga J; Carcinoids and their variant endocrinomas. An analysis of 11842 reported cases. *J Exp Clin Cancer Res.*, 2003; 22:517–530.
16. Ebihara Y, Watanabe K, Fujishiro Y, Nakao K, Yoshimoto S, Kawabata K, Asakage T; Carcinoid tumor of the larynx: clinical analysis of 33 cases in

- Japan. *Acta Oto-Laryngologica*, 2007; 127(sup559):145-50.
17. Milroy CM, Ferlito A; Immunohistochemical markers in the diagnosis of neuroendocrine neoplasms of the head and neck. *Ann Otol Rhinol Laryngol.*, 1995; 104:413–18.
  18. Kau R, Arnold W; Somatostatin receptor scintigraphy and therapy of neuroendocrine (APUD) tumors of the head and neck. *Acta Otolaryngol.*, 1996; 116: 345-49.
  19. Moisa II; Neuroendocrine tumors of the larynx. *Head Neck*, 1991; 13: 498-508.
  20. Ferlito A, Shaha AR, Rinaldo A; Neuroendocrine neoplasms of the larynx: diagnosis, treatment and prognosis. *ORL J Otorhinolaryngol Relat Spec.*, 2002; 64: 108-113.
  21. Ferlito A, Silver CE, Bradford CR, Rinaldo A; Neuroendocrine neoplasms of the larynx: an overview. *Head and Neck*, 2009; 31(12):1634–46.
  22. Monroe AT, Morris CG, Lee E, Mendenhall WM; Small cell carcinoma of the head and neck: The University of Florida experience. *Journal of the Hong Kong College of Radiologists*, 2005; 8(2):83–86.
  23. Brisigotti M, Fabbretti G, Lanzaova G, Brugnari ER, Presutti L, Artoni S; Atypical carcinoid of the larynx: case report. *Tumori.*, 1987; 73: 417-421.