

## Peripartum Cardiomyopathy Precipitated by Preeclampsia

Dr. Mukti Harne<sup>1</sup>, Dr. Sumedha Harne<sup>2</sup>

<sup>1</sup>Resident Obstetrics and Gynaecology, PDVVPF's Medical College, Ahmednagar, Maharashtra, India

<sup>2</sup>Infertility Specialist, Senior Consultant, PDVVPF's Medical College, Ahmednagar, Maharashtra, India

### \*Corresponding author

Dr. Mukti Harne

Email: [drmuktiharne@gmail.com](mailto:drmuktiharne@gmail.com)

---

**Abstract:** Peripartum cardiomyopathy (PPCM) is associated with one in every 3000 to 15000 deliveries, affecting thousands of women every year. According to the definition, PPCM includes cardiac failure in the last trimester of pregnancy or within six months of delivery, absence of an identifiable cause for the cardiac failure, absence of recognizable heart disease before the last month of pregnancy, and left ventricular (LV) dysfunction (ejection fraction of less than 45% or reduced shortening fraction). The detection of this heart disease in pregnancy is important because of its high morbidity and mortality incidence. PPCM is masked in many patients and is unnoticed leading to a high mortality which go undiagnosed. Therefore this case was documented.

**Keywords:** Non Invasive Ventilation, Cardiomyopathy, Pregnancy, Vaginal Delivery, Peripartum, Preeclampsia, Diuretic.

---

### INTRODUCTION

Peripartum cardiomyopathy (PPCM) is associated with one in every 3000 to 15000 deliveries, affecting thousands of women every year [1]. According to the definition, PPCM includes cardiac failure in the last trimester of pregnancy or within six months of delivery, absence of an identifiable cause for the cardiac failure, absence of recognizable heart disease before the last month of pregnancy, and left ventricular (LV) dysfunction (ejection fraction of less than 45% or reduced shortening fraction) [2, 3].

Though it is asymptomatic, it has many risk factors include multiparity, black race, older maternal age, pre-eclampsia, and gestational hypertension [1, 4]. Symptomatically PPCM presents with fatigue, edema, and dyspnea. PPCM clinically resembles patients of pulmonary emboli and eclampsia.<sup>5</sup> Therefore, its diagnosis is often missed or delayed leading to devastating consequences:

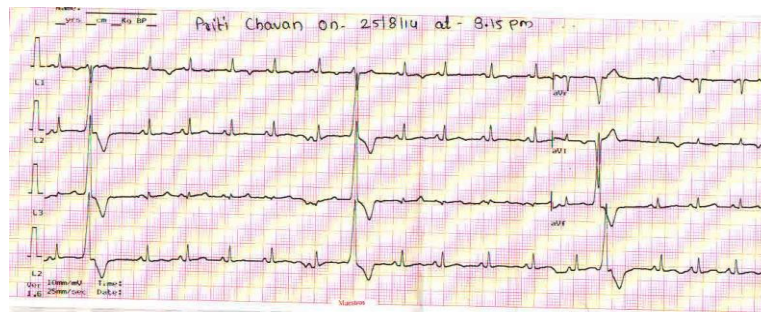
Mortality is as high as 20% to 50% [5]. This article also stress on a case which was diagnosed with PPCM and treated thereafter.

### CASE REPORT

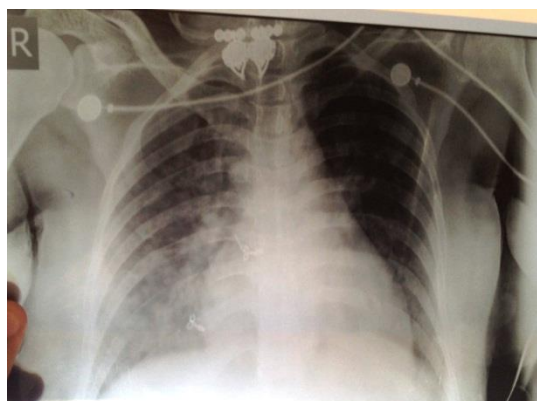An Indian woman (Gravida 2 para 1), age 25 years, presented to labour room at 36 weeks of pregnancy, reporting dyspnea and fatigue that had lasted two days. However, when her husband insisted, she went to the hospital for evaluation. She was found

to be dyspneic and hypoxic. Hence patient was admitted in Intensive Care Unit for further treatment. Her medical history included obesity, but the patient was in relatively good health until approximately her last month of pregnancy, when she developed hypertension (with significant preeclampsia signs and symptoms), dependent peripheral edema, as well as fatigue and palpitation. During examination, the patient was noted to be afebrile and had a blood pressure of 160/96 mm of Hg, a pulse rate of 90 beats per minute irregularly irregular, a respiratory rate of 34 breaths per minute, and an oxygen saturation of 78% while receiving oxygen through a 2-L nasal cannula. Her lungs on auscultation appear to have bilateral extensive crackles and her heart rate was irregular, with an S3 gallop. Her extremities were oedematous, and she had no calf tenderness. Urinalysis results were positive for proteins (+3). Her previous pregnancy was a full term normal delivery, uneventful. She had no similar complaints of the same.

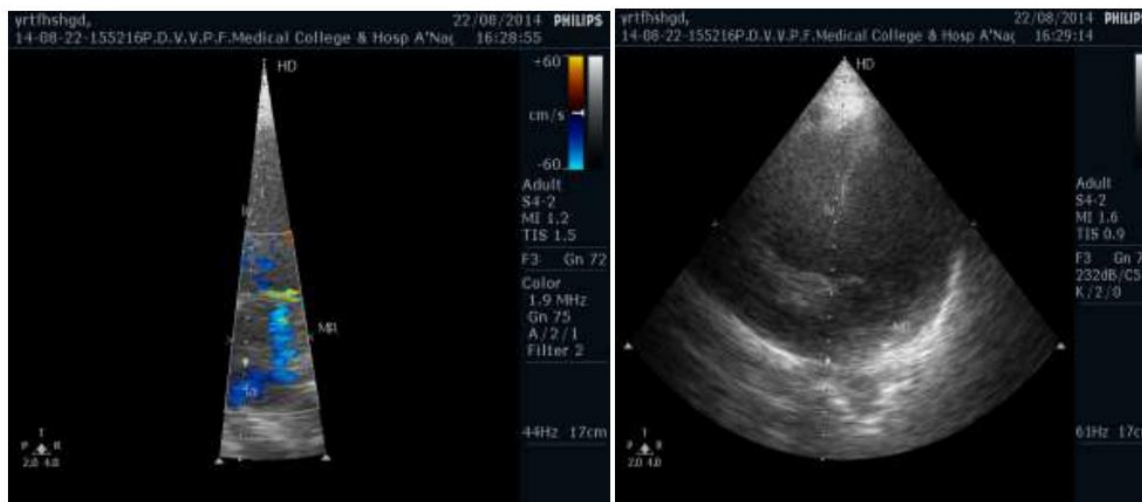The patient was subsequently admitted to the hospital for new-onset PPCM and was given furosemide intravenously for diuresis and non invasive ventilation (BiPAP) with other supportive treatment. Physician reference was taken for the same and the case was managed with equal attention from the physicians. A transthoracic echocardiogram(TTE) done on admission showed an LV ejection fraction (EF) of 25% to 30%, with moderate mitral regurgitation (MR).



**Fig-1:** An electrocardiogram showed a multiple premature ventricular contractions (PVC)



**Fig-2:** Chest radiographs(using an abdominal shield ) showed mild cardiomegaly with pulmonary edema



**Fig-3:** Noncardiogenic pulmonary edema in patient with preeclampsia, due to capillary leak that can be primary component of preeclampsia. Radiograph reveals diffuse increase in lung markings without cephalization or vascular redistribution seen in patients with pulmonary edema from systolic dysfunction. (S/o Acute Pulmonary Edema)

Her fatigue and dyspnea greatly decreased with diuresis. Epidural anaesthesia was given to the patient and propped up position was given when is entered the active stage of labour. Pulse monitoring every 15 minutes and blood pressure every 1 hourly was monitored. Patient went into spontaneous labour. In the end of first stage and beginning of second stage of labour, high concentration pitocin drip was started. Liberal episiotomy was given, which was sutured later. She delivered a male child, weighing 2.13 kgs. Third stage of labour was uneventful and fluid restriction was

done by keeping tab misoprostol 600 ug per rectally. No intrapartum complication. Mother and baby were healthy. Immediately after delivery 2D echo done showed an EF of 40-45 % with moderate MR. She was discharged from the hospital three days later and instructed to take ramipril (5mg- once a day) and low dose of diuretic. Follow-up examination at 1 months showed a stable cardiomyopathy and well-controlled hypertension, and a repeat echocardiogram at the same point showed an ejection fraction of 45-50%. Patient

was advised to use contraceptive measures to prevent future pregnancy.

### CLINICAL FEATURE

According to the New York Heart Association, classification to heart disease is as follows:

- Class I - Disease with no symptoms
- Class II - Mild symptoms/effect on function or symptoms only with extreme exertion
- Class III - Symptoms with minimal exertion
- Class IV - Symptoms at rest

New or rapid onset of the following symptoms requires prompt evaluation:

There are other signs and symptoms which give alert alarms to the obstetrician while treating a patient with any type of heart disease: Cough, Paroxysmal nocturnal dyspnea, Abdominal pain, Fatigue, Orthopnea, Palpitations, Hemoptysis, Chest pain.

The presence of such heart disease in pregnancy not only makes the pregnancy a high risk one but also questions the maternal and fetal morbidity.

### DISCUSSION

Dyspnea is majorly seen in nearly 60% to 70% of women during pregnancy [4]. Cases have been reported with PPCM in young primigravidas and white patients as well, accounting to an incidence of 24%–37% [5-7]. Because dyspnea is a common finding in normal pregnancy and even in the initial postpartum state, PPCM is often missed, especially if the patient population does not fit the typical epidemiology.

### ETIOLOGY

In 1870s a relationship was studied between pregnancy and dilated cardiomyopathy [11]. The reasons why PPCM occurs is still under evaluation. The resemblance of this condition with preeclampsia has brought many confusion amongst the obstetrician with respect to the management of such cases. The awareness of this heart disease has to be brought in the picture. Teamed approach for the management of PPCM is the rule of thumb. Hence any complaints like that of chest pain or dyspnoea should be given equal importance keeping PPCM as a differential diagnosis.

### TREATMENT AND PROGNOSIS

Like any other heart disease in pregnancy, PPCM is also treated the same way. The treatment includes, restriction of physical activities, fluid restriction, salt restrictions, propped up position during delivery, regular vital monitoring,  $\beta$ -blocker, diuretic, and digoxin. Afterload is to be maintained and could be decreased using hydralazine [8]. The use of anticoagulants are brought in practices, mainly warfarin (if near term) so that thrombosis can be kept under check [9]. Warfarin, if started, is to be continued till 5

days of postpartum period. Such patients should be advised sterilization to prevent future pregnancies, as the incidence of PPCM in subsequent pregnancy is around 50 -100 % [10].

### CONCLUSION

This case had an atypical presentation of PPCM with preeclampsia along with hypoxia, clinically and cardiomegaly with pulmonary congestion on chest radiographs. Thus, a teamed approach of Obstetricians and Physicians is necessary for the management of such cases.

### REFERENCES

1. Demakis JG, Rahimtoola SH, Sutton GC, Meadows WR, Szanto PB, Tobin JR, Gunnar RM; Natural course of peripartum cardiomyopathy. *Circulation*, 1971; 44(6):1053-61.
2. Pearson GD, Veille JC, Rahimtoola S, Hsia J, Oakley CM, Hosenpud JD, Ansari A, Baughman KL; Peripartum cardiomyopathy: national heart, lung, and blood institute and office of rare diseases (national institutes of health) workshop recommendations and review. *Jama*, 2000; 283(9):1183-8.
3. Simon PM, Schwartzstein RM, Weiss JW, Fencel V, Teghtsoonian M, Weinberger SE; Distinguishable types of dyspnea in patients with shortness of breath. *Am Rev Respir Dis.*, 1990; 142(5):1009–14.
4. Sliwa K, Fett J, Elkayam U; Peripartum cardiomyopathy. *Lancet*, 2006; 368(9536):687–93.
5. Amos AM, Jaber WA, Russell S; Improved outcomes in peripartum cardiomyopathy with contemporary. *Am Heart J.*, 2006; 152(3):509–13.
6. Bhakta P, Biswas B, Banerjee B; Peripartum cardiomyopathy: review of the literature. *Yonsei Med J.*, 2007; 48(5):731–47.
7. Marx JA, Hockberger RS, Walls RM; eds. Rosen's emergency medicine: concepts and clinical practice. 6th ed. Philadelphia, PA: Elsevier Health Sciences, 2006.
8. Walsh JJ, Burch GE, Black WC, Ferrans VJ, Hibbs RG; Idiopathic myocardial infarction of the puerperium (postpartal heart disease). *Circulation*, 1965; 32:19–31.
9. Felker GM, Jaeger CJ, Klodas E, Thiemann DR, Hare JM, Hruban RH, Kasper EK, Baughman KL; Myocarditis and long-term survival in peripartum cardiomyopathy. *American heart journal*, 2000; 140(5):785-91.
10. Cunningham GF, Gant NF, Leveno KJ, Gilstrap III LC, Hauth JC, Wenstrom KD; eds. Williams Obstetrics. 21st ed. New York: McGraw-Hill; 2001; 1141–514.
11. Fett JD, Ansari AA, Sundstrom JB, Combs GF; Peripartum cardiomyopathy: a selenium disconnection and an autoimmune connection. *Int J Cardiol.*, 2002; 86(2–3):311–6.