

A Case of Extra skeletal Ewing Sarcoma - Scapular Region

Dr. Koyel Das¹, Dr. Deba jyoti Singha Roy², Dr. Anadi Roy Choudhury³, Dr. Sudipta Kumar Mandal⁴

¹Junior Resident, Pathology Deptt, R. G. Kar Medical College & Hospital, Kolkata, West Bengal

²Demonstrator cum Tutor, Pathology Deptt, R. G. Kar Medical College & Hospital, Kolkata, West Bengal

³Associate Professor, Pathology Deptt, R. G. Kar Medical College & Hospital, Kolkata, West Bengal

⁴Assistant Professor, Department Of Anaesthesiology, CMSDH, West Bengal

*Corresponding author

Koyel Das

Email: dr.koyelnrs@gmail.com

Abstract: A 14 year old boy complains of a globular, tender, firm to hard swelling in right scapular region measuring 9 cm in maximum dimension for last 6 months with other complains of weakness, pain and weight loss. His x ray and CT scan lesion showed a soft tissue lesion at the right scapular region with no bone involvement. Histopathology and CD99 immunohistochemistry proved it an extra skeletal Ewing Sarcoma. Occurrence of extra skeletal Ewing Sarcoma in flat bones soft tissue is extremely rare.

Keywords: Ewing Sarcoma, extra skeletal, scapular region.

INTRODUCTION

Ewing Sarcoma is a rare and highly malignant small blue round cell tumour primarily affecting bones. The incidence rate is less than 3 per million people and 90% cases occur in the age group of 5-25 years [1]. In primary extra osseous Ewing Sarcoma of soft tissue underlying bone involvement is not found. It commonly occurs in long bones, mostly in pelvis, femur, tibia, and humerus. It is rarely found in scapular region [2].

CASE REPORT

A 14 year old boy complains of a globular, tender, firm to hard swelling in right scapular region measuring 9 cm in maximum dimension for last 6 months with other complains of weakness, pain and weight loss. He was sent for Fine Needle Aspiration Cytology at Pathology department of RG Kar Medical College, Kolkata. His x ray and CT scan lesion showed a soft tissue lesion at the right scapular region with no bone involvement. Cytology report was of small blue round cell tumour. An incisional biopsy was suggested for histopathology. After proper fixation in 10% neutral buffered formalin and tissue processing steps Haematoxylin-Eosin stain was done. Histopathology showed tumor cells arranged in sheet in a vascular background. Individual tumor cell have pleomorphic round to oval vesicular nucleus and scanty cytoplasm. A few rosette formations were seen. Histopathology suggested of small blue round cell tumor, possibly Ewing Sarcoma [3]. A panel of immune-histochemistry markers were suggested for confirmation as the family of small blue round cell tumor is large comprising of lymphoblastic lymphoma, neuroblastoma, rhabdomyosarcoma and many more. CD99, an immuno-histochemistry maker of Ewing Sarcoma

showed positive membrane staining. CD 45, an immune-histochemistry marker of lymphoblastic lymphoma was negative for staining. Synaptophysin, an immune-histochemistry marker of neuroblastoma was negative for staining. Desmin and myogenin, both immune-histochemistry marker of rhabdomyosarcoma were negative for staining. Thus, a conclusive opinion of Ewing Sarcoma was given. Ethical committee permission was duly taken to carry out the study.

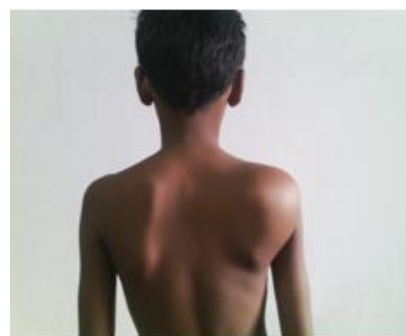

Fig 1: 14 yr old boy showing right scapular swelling

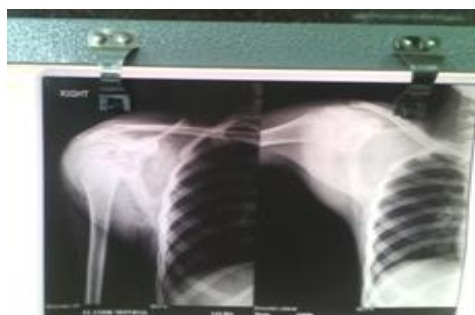

Fig 2: x ray showing right scapular swelling without bony involvement

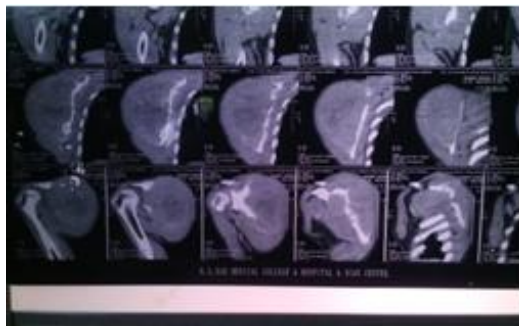

Fig 3: CT scan showing right scapular swelling without bony involvement

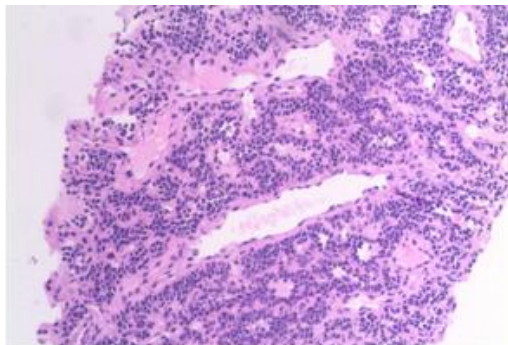


Fig 4: 10X showing small round cells with hyperchromatic nuclei

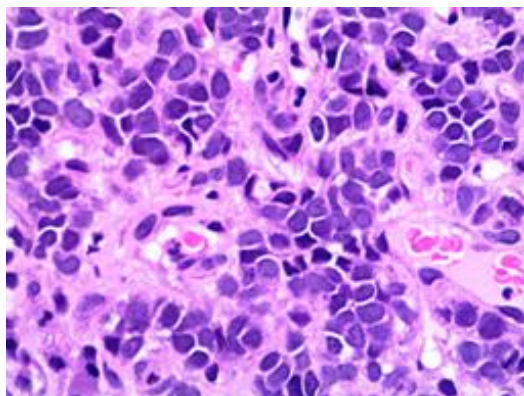


Fig 5: 40X showing round cells with hyperchromatic nucleus and scanty cytoplasm

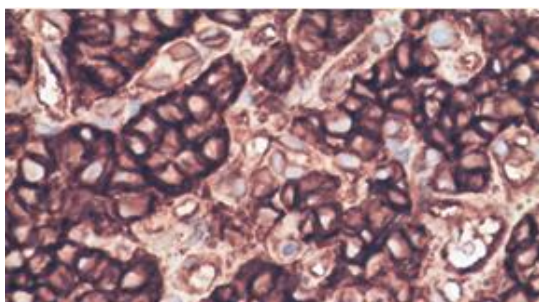


Fig 6: CD 99 showing strong membrane positivity

Soft tissue Ewing Sarcoma is a rapidly growing round malignant cell tumor which can reach more than 10cms by the time the diagnosis is made. The most commonly affected extraosseous sites of Ewing

Sarcoma are paravertebral spaces, lower extremity, head, neck and pelvis. It is very rare in the scapular region. Histopathology showed small blue round cell tumor with occasional rosette formation. CD99 immunohistochemistry showed strong membrane positivity and other immunohistochemical markers were negative for other small blue round cell tumors giving a conclusive diagnosis of Ewing Sarcoma.

CONCLUSION

Occurrence of soft tissue Ewing Sarcoma in flat bones is extremely rare. The mainstay of treatment is surgery, chemotherapy and radiotherapy. The long term survival has improved from 10% to 50-60% or greater. The prognosis of extra osseous Ewing Sarcoma is more favourable than Ewing Sarcoma of bones .The treatment plan should be individualised for each patient based on age, location, size of tumour stage, response to therapy [1].

REFERENCES

1. Waqar SH, Zahid MA; Ewing Sarcoma in scapular region, APSP Journal of case report, 2011; 2(3):22.
2. Philip M.S. Simpson, Robin Reid, Daniel Porter; Ewing Sarcoma of the Upper extremity, Sarcoma, 2005; 9(1/2):15-20
3. Rosai J; Bones and Joints, Rosai and Ackermans Surgical Pathology, 10th Ed, CV Mobsy, St.Louis, 2011; 2046-2050.