

An Atypical Case of Recurrent Phyllodes Tumor

Dr. Souvik Basak^{1*}, Dr. Ahmad F Danish², Dr. Dhritiman Maitra³, Dr. Kashi Nath Das⁴

¹Senior Resident, ²Post Graduate Trainee, ³Assistant Professor, ⁴Professor and Head

Department of Surgery, Medical College, Kolkata, West Bengal, India

*Corresponding author

Dr. Souvik Basak

Email: sb009cmc@gmail.com

Abstract: We report a case of a forty-year-old lady presenting with an ulceroproliferative lesion over lower part of left chest wall after having 5 previous operations on breast including mastectomy followed by chemotherapy and radiotherapy. MRI thorax revealed chest wall and muscle involvement with indentation of ribs, without any distant metastasis. Incision biopsy found malignant cystosarcoma phyllodes. WLE of the mass including resection of ribs followed by chest wall reconstruction was performed. In spite of resection margins being found negative on HPE, there has been local recurrence 1 year following last operation. The rarity of the diagnosis along with several discrepancies in HPE reports and repeated recurrences make this case an intriguing one.

Keywords: Phyllodes tumor, recurrent phyllodes tumor, Mastectomy, Chest wall resection and reconstruction.

INTRODUCTION:

Phyllodes tumor or Cystosarcoma Phyllodes is an uncommon neoplasm that represents 0.3 to 0.5% of female breast neoplasm [1]. It occurs in women aged 45- 49 years [2].

Wide local excision is the mainstay of the disease treatment, and free surgical margins are of curative importance because recurrence is strongly correlated with inadequate margins. In large and multiple recurrences, mastectomy may be necessary to

provide adequate margins [3]. Some patients have recurrent disease even after mastectomy, however their treatment is challenging.

CASE REPORT:

A forty-year-old lady presented with an ulceroproliferative lesion over lower part of left chest wall after having 5 previous breast operations including mastectomy. She first noticed a very small lump on her left breast when she was 30 years old and lumpectomy was performed. Subsequently she had four recurrences.

Year	Presentation	Procedure	HPE Report
2004	Small left breast lump	Lumpectomy	Fibroadenoma
2006	Huge left breast lump	MRM	Cystosarcoma phyllodes, margins free. LN- follicular hyperplasia
2010	Lump over previous scar	WLE with 2cm margin	Stromal sarcoma, margins free
2012	Left Axillary lump	WLE of Axillary Lump	Borderline phyllodes tumor, margins free

Following 3rd surgery, she underwent 6 cycles of chemotherapy and radiotherapy. General survey was within normal limits. On local examination, she had a painless ulceroproliferative growth over anterolateral part of left chest wall. Surrounding and underlying tissues were indurated with associated lymphedema of left upper limb. Contralateral breast was found normal. There was neither any history suggestive of distant metastasis nor any previous history of breast diseases or malignancy in the family.

Routine blood parameters (e.g. complete hemogram, electrolytes, and liver function tests) were found unremarkable. Chest skiagram was taken after

marking the margins with clips for assessing extent. MRI of thorax showed anterior chest wall lesion involving muscles and indentation of ribs. Metastatic disease was ruled out on basis of her symptoms, chest X-ray, CT scan of abdomen. Incision biopsy was performed from ulcer margin and it came out to be malignant cystosarcoma phyllodes.

Patient was adequately prepared. Wide local excision of the mass including Pectoralis Major and Minor muscles along with segmental resection of three ribs was performed. Polypropylene mesh was placed to cover the chest wall defect. Chest wall was reconstructed using Latissimus Dorsi flap and primary

skin grafting was done at the donor site. In the post-operative period, superficial necrosis was found at the medial end of the flap and there was about 50% uptake of skin at donor site. Following regular debridement and dressing, she was discharged on 21st post op day. Histopathology confirmed it to be malignant phyllodes

(Mitosis > 10 / 10 HPF). All margins and ribs found free of malignancy.

Unfortunately, she has again presented with a recurrent mass over the shoulder, 1 year following operation and core needle biopsy has diagnosed it to be malignant phyllodes.

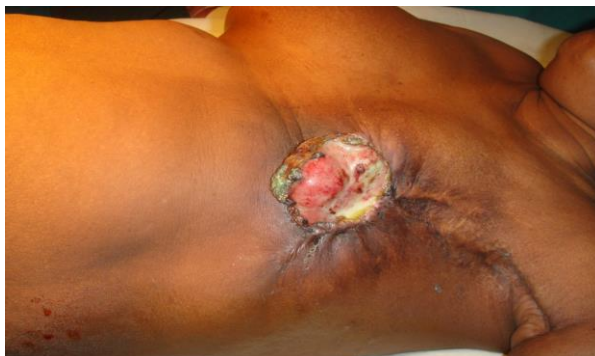

Fig 1: Supine profile of the patient showing ulceroproliferative lesion over lower part of left chest wall.

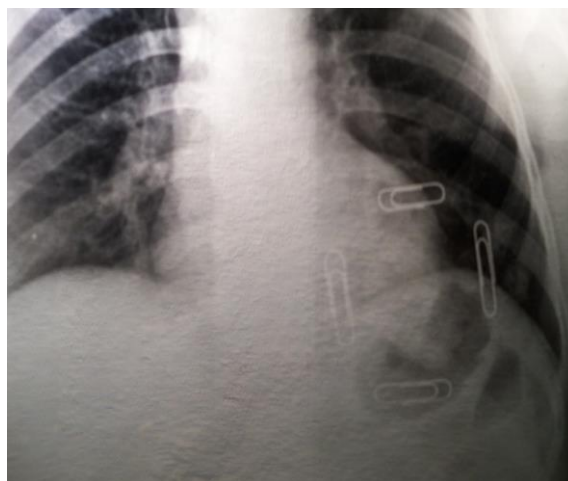


Fig 2: Chest Skiagram (PA view) taken after marking the margins with clips for assessing extent.

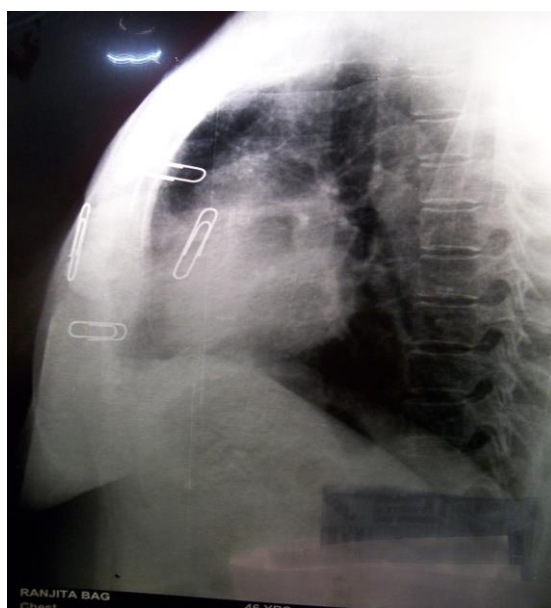


Fig 3: Chest Skiagram (Oblique view) taken after marking the margins with clips for assessing extent.

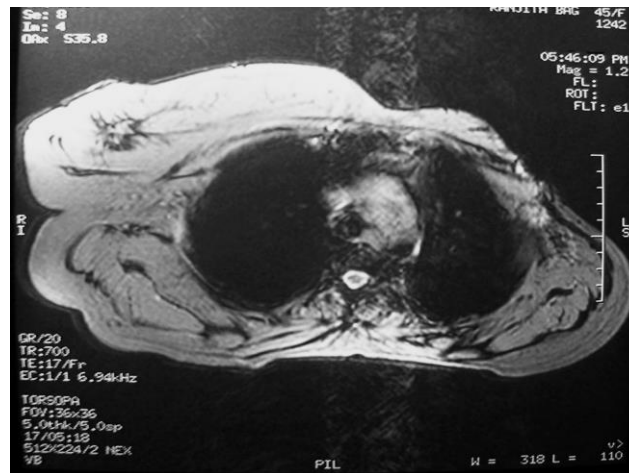

Fig 4: MRI Thorax showing extent of mass and chest wall involvement.

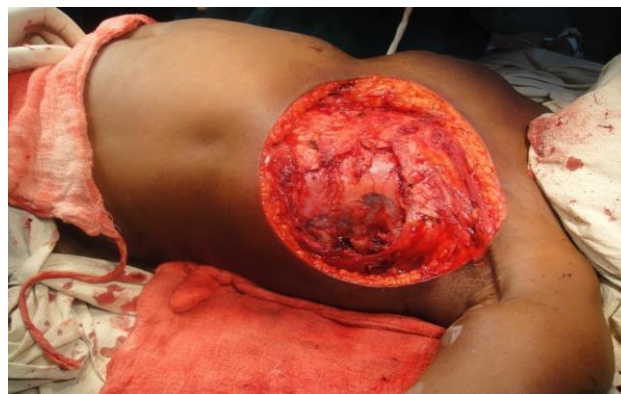

Fig 5: Chest wall defect created after wide local excision and resection of ribs.

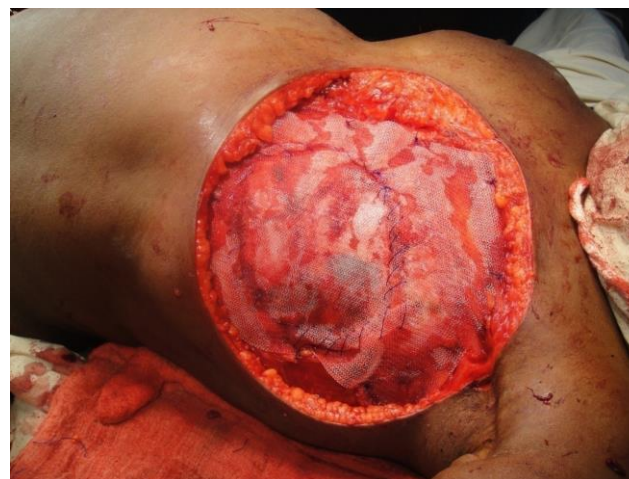

Fig 6: Chest wall defect being covered by polypropylene mesh.

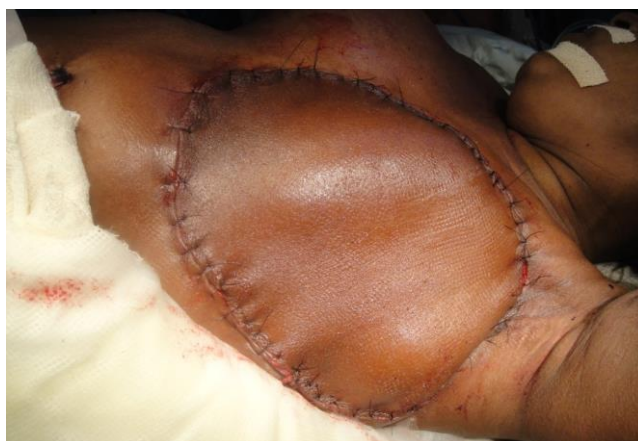

Fig 7: Chest wall being reconstructed by Latissimus Dorsi flap.

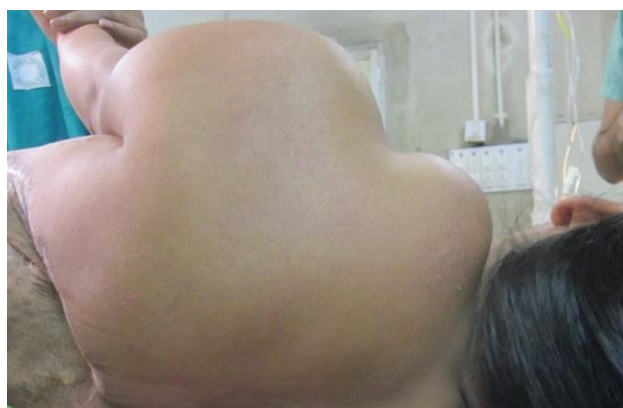

Fig 8: Recurrent shoulder mass (1 yr following operation)

DISCUSSION:

The chief objective of outlining this case report was to highlight the rarity of a case. It shows that in case of recurrences breast tumors, histopathology report may differ every time. In addition, there are few peculiarities in this case which warrants attention.

Phyllodes tumors (PT) of the breast are uncommon and are reported to account for only 0.3–0.5% of all breast tumors [1]. These tumors were first known as Cystosarcoma Phyllodes and were described by Johannes Muller in 1838. The name phyllodes was derived from the Greek word phyllos, meaning leaf because of the leaf-like whorled appearance of the tumor on gross sectioning. Here there has been a repeated recurrence with varied histopathology reports which is unusual.

Phyllodes tumors have an increased potential for local recurrence, even if histologically benign, and some may follow a malignant course. Local recurrence rates of up to 20%, even for benign PT, have been reported [8].

Standard surgical treatment for phyllodes tumor consists of complete excision with wide radial margin of at least 1cm [4]. Mastectomy is recommended for large tumor (>10cm), multiple

recurrences. Axillary dissection is not routine unless nodes are enlarged [5]. The failure is most closely related to local recurrences because of the presence of tumor at surgical margins. Here, in spite of all the margins being free, there has been recurrence.

It should be emphasized that by the time a phyllodes tumor becomes giant, there is no guarantee that the remaining breast tissue has not been infiltrated by tumor cells. Hence, the emphasis should be on complete extirpation of all visible tumor and breast tissue. If all breast tissue has been removed, and all tumor infiltrated soft tissues have been removed, then the tumor is unlikely to recur locally [6].

Chest wall resection and reconstruction with synthetic polypropylene mesh and local muscle flaps can be performed as a safe, effective one-stage surgical procedure for a variety of major chest wall defects [7].

CONCLUSION:

This case illustrates that one should carefully evaluate a breast tumor and corroborate the histopathology report with clinical findings. In addition to that, one has to be very cautious regarding taking histopathology report at face value. In the treatment of phylloides tumor, more than 2 cm histological negative margin is necessary for a complete excision to prevent

recurrences. Even after mastectomy, chance of recurrence remains in phylloides tumour of breast. Full thickness excision with primary reconstruction can be an excellent option for phylloides tumor with repeated recurrences.

REFERENCES:

1. Rowell MD, Perry RR, Hsiu JG, Barrano SC; phyllodes Tumors. *The American j. of surgery*, 1993; 165(3): 363-379.
2. Salvadori B, Cusumano F, Del Bo R, Delledonne V, Grassi M, Rovini D *et al.*; Surgical treatment of phyllodes tumors of breast. *Cancer*, 1989; 63(12): 2532-2536.
3. Soumarova R, Seneclova Z, Horov H, Vojkovská H, Horová I, Budíková M *et al.*; Retrospective analysis of 25 women with malignant phyllodes, treatment, result. *Arch genecol obstet* 2004; 269(4): 278-81.
4. NCCN clinical practice guideline in oncology, version 3, 2014; breast cancer, phyll 1-2.
5. Mangi A.A, Smith B.L, Gadd M.A, Tanabe K.K, Ott M.J, Souba W.W; Surgical management of phyllodes tumors. *Arch surg*, 1999; 134(5): 487-91.
6. Liang M.I, Ramaswamy B, Patterson C.C, McKelvey M.T, Gordillo G, Nuovo G.J *et al.*; Giant breast tumors, surgical management of phyllodes tumor. *World J of surg onc*, 2008; 6(1): 1.
7. Akhtar HA, Naqvi A, Parvaiz Z; Reconstruction of complex chest wall defects by using polypropylene mesh & pedicled LD flap. *J plast recon aesthet surg*, 2008; 61: 628-35.
8. Hajdu SI, Espinosa MH, Robbins GF; Recurrent cystosarcoma phyllodes: a clinicopathologic study of 32 cases. *Cancer*, 1976; 38(3): 1402-1406.