

Bowel Visualization on Bone Imaging Following Urotherapy

Rong-Hsin Yang¹, Yum-Kung Chu^{2*}

¹ Division of Nuclear Medicine, MacKay Memorial Hospital and

² Department of Nuclear Medicine, Taipei Veterans General Hospital, Taiwan

*Corresponding author

Yum-Kung Chu

Email: ykchu@vghtpe.gov.tw

Abstract: A 57-year-old woman with a newly diagnosed lung cancer was referred for a bone survey as a part of cancer workup. An interesting finding on Tc-99m MDP bone scan was accumulation of radioactivity in the bowel, on account of self urine drinking before the imaging. Many people believe that drinking their own urine has a myriad of health benefits, nevertheless, none of which have been scientifically proven. Self urine drinking may cause radioactivity accumulated in the bowel on subsequent imaging, which needs to be distinguished from urinary diversion caused by various pathologies.

Keywords: bone scan, urotherapy, visualization of the bowel.

INTRODUCTION

Urotherapy is a naturopathic remedy practiced in different parts of the world for centuries. Many people believe that certain urinary elements are good for health and healing. Nevertheless, none of which have been proven by peer-reviewed studies. Since trace amount of those constituents in fresh urine is not likely sufficient for medical purposes. As illustrated in this report, self urine drinking may cause radioactivity accumulated in the bowel on subsequent imaging, which needs to be distinguished from urinary diversion caused by various pathologies.

CASE REPORT

A 57-year-old woman with a newly diagnosed lung cancer underwent a bone imaging for preoperative evaluation, as a part of cancer workup. Tc-99m MDP scintigraphy demonstrated degenerative changes in the spine and negative for bone metastasis. Surprisingly, significant radiotracer accumulation in the stomach, small and large intestines was noted (Fig. 1). However, there were no relevant pathologies causing urinary diversion. A thorough inquiry disclosed that the patient had performed a self uroposia (urine drinking) as an ethnic remedy before the imaging.

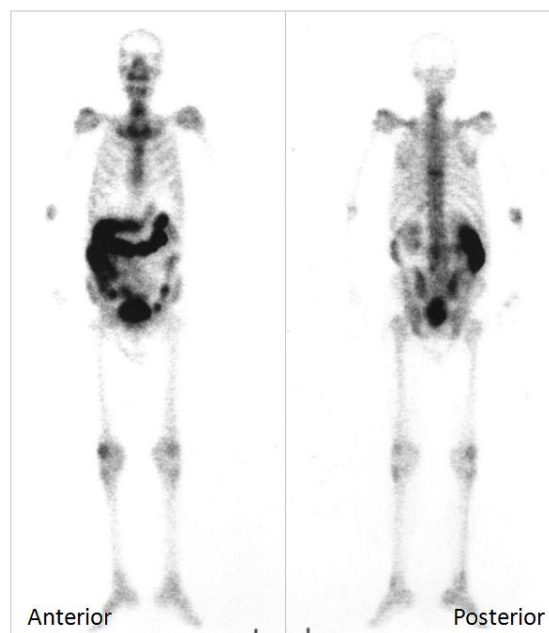


Fig-1: Tc-99m MDP bone scan illustrated degenerative changes in the spine and negative for bone metastasis, but accumulation of radiotracer in the bowel.

DISCUSSION

Self urine drinking, also known in India as “amaroli” (the nectar of immortality), has been practiced both in the East and in the West for centuries. It is considered by some people to be a naturopathic remedy for health restoration and healing. Urotherapy as a system of esoteric, universal cure was advocated in early 20th century [1], however, may seem to be unorthodox. Fresh urine is virtually sterile, consisting of 95% water, 2.5% urea, and the remaining 2.5% a mixture of minerals, salts, hormones, and enzymes. Some trace constituents had been extracted from human urine and were claimed to cure various diseases [2], but not yet to be proven effective for medical purpose by peer-reviewed studies [3].

Bone scans with radiotracers can assess the presence of active lesions or cancer spreads in the skeleton. A radionuclide agent (Tc-99m labeled diphosphonate) is injected intravenously. About 50% of the activity binds in the skeleton. More than 30% of the unbound complex is excreted through the urine within one hour. The distribution of the radiotracer is detected by a gamma camera 2 to 3 hours later and turns the information into a picture. Cells which are most active in the target tissue or organ will take up more of the bone seeking agent. It is important to recognize the extra-skeletal uptake of radiotracers, because the unexpected findings greatly enhance the diagnostic value of the study. Serendipitous bowel visualization [4-6] has been seen in cases of trauma, surgical diversion, fistulas, protein losing enteropathy, bowel infarction, intestinal lymphangiectasia [7], normal intestine in children [8], and previous administration of radiotracers [9]. Self urotherapy should be included in the patient related artifacts in nuclear bone imaging.

COMPETING INTEREST

The authors declare that they have no competing interests.

REFERENCES

1. Armstrong JW; The Water of Life- A Treatise on Urine Therapy. London: Vermilion, 2005.
2. Burzynski SR; Antineoplastons: history of the research (I). *Drugs Exp Clin Res.*, 1986; 12 Suppl 1:1-9.
3. Green S; Antineoplastons”. An unproved cancer therapy. *JAMA*, 1992; 267(21): 2924-2928.
4. Ackerman L, Elam E, Bushnell D, Freeman ML, Kaplan E; Bowel visualization in bone scintigraphy. *Semin Nucl Med.* 1987; 17(1):81-2.
5. Ergün EL, Kiratli PO, Günay EC, Erbaş B; A report on the incidence of intestinal ^{99m}Tc methylene diphosphonate uptake of bone scans and a review of the literature. *Nucl Med Commun*, 2006; 27(11): 877-885.
6. Eftekhari M, Fard-Esfahani A, Haghghatafshar M, Keyvan A, Beiki D, Aghahosseini F, et al; Bone scan with incidental visualization of the entire colon. *Iran J Nucl Med.*, 2010; 18(2):56-59.
7. Lee KH, Chung JK, Lee DS, Lee MC, Song IS, Koh CS. Intestinal leakage of technetium- 99m-MDP in primary intestinal lymphangiectasia. *J Nucl Med.*, 1996; 37(4):639 – 641.
8. Conway JJ, Weiss S, Khentigan J, Tofe A, Thane T; Gall bladder and bowel localization of bone imaging radiopharmaceuticals [Abstract]. *J Nucl Med*, 1979; 20:622.
9. Stadalnik RC, Tsai SC, Kao CH, Lin WY, Wang SJ; January). Intestinal accumulation of Tc 99m MDP on bone scan. In *Seminars in nuclear medicine*, 1999; 29(1): 80-81).