

An Atypical Case of Primary Gastric Lymphoma

Dr. Souvik Basak^{1*}, Dr. Abhishek Sharma², Dr. Kiran Nath², Prof. (Dr.) Kashinath Das³

¹Senior Resident, ²Post Graduate Trainee, ³Professor and Head, Department of Surgery, Medical College, Kolkata, West Bengal, India

*Corresponding author

Dr. Souvik Basak

Email: sb009cmc@gmail.com

Abstract: We report a case of a fifty-two-year old gentleman who presented with a history of early satiety after meals altered bowel habits for 1 month and fever for 2 weeks. On local examination, an intra-abdominal, non-tender, variegated swelling was found extending from left hypochondrium to the epigastric region. Contrast enhanced CT scan showed a heterogeneous mass (11 cm x 11 cm) at left upper quadrant, medial to spleen, compressing the stomach, ?Neoplastic lesion. Exploratory laparotomy found a huge irregular mass involving spleen, tail of pancreas, Gerota's fascia and greater curvature of stomach, having adhesion with diaphragm and omentum, but without any enlarged lymph nodes. En-bloc excision of mass along with spleen, tail of pancreas, and a sleeve of stomach including the greater curvature was performed. Subsequently, histopathology and immunohistochemistry confirmed it to be a case of Diffuse Large B-Cell Lymphoma of stomach (DLBCL). The rarity of the diagnosis along with its nature of presentation, and absence of several characteristic features make this case an interesting one.

Keywords: Primary gastric lymphoma, gastrointestinal lymphoma, Diffuse large B-cell lymphoma.

INTRODUCTION:

Non-Hodgkin's lymphoma (NHL) occurs more often than Hodgkin's disease and may be of the nodal or extra-nodal type. 25% of the non-Hodgkin's lymphomas in North America and about 50% in Europe and the Far East are primary extra-nodal NHL. The stomach is most commonly involved by extra-nodal lymphomas, and in 15–20% of diffuse non-Hodgkin's lymphomas involvement of the stomach has been described [1]. Primary gastric lymphoma is uncommon, accounting for 2% - 8% of all gastric malignancies in Western countries [2-5]. Some recent studies however report that the incidence of primary gastric lymphoma is increasing over the last two decades [3].

According to Dawson [6] gastric lymphomas are considered as primary when the stomach is predominantly involved, and the intra-abdominal lymphadenopathy, if present, corresponds to the expected lymphatic drainage of the stomach. This definition excludes patients with palpable subcutaneous lymph nodes, mediastinal lymphadenopathy and bone marrow, liver or spleen involvement.

CASE REPORT:

A fifty-two-year old gentleman presented with a history of early satiety after meals, altered bowel habits for 1 month and fever for 2 weeks. It was associated with nausea, dyspepsia and intermittent episodes of constipation for the same duration but not associated with vomiting, hematemesis or melena. There were intermittent episodes of fever for 2 weeks

without any history of pain, dyspepsia, headache, palpitation or hematuria.

General survey was essentially normal except mildly impaired nutrition. On inspection, a bulge was seen in the left hypochondrium, becoming more prominent on inspiration and less prominent on leg rising. On palpation, an intra-abdominal, non-tender, variegated swelling was found extending from left hypochondrium to the epigastric region, having an irregular surface, restricted mobility but moving slightly with respiration. Its lower margin was palpable 3cm below costal margin in midclavicular line, but upper margin was not palpable. No organomegaly or ascites found. There was dull note on percussion and absent breath sounds over left lower chest fields on auscultation.

Routine blood parameters (e.g. complete hemogram, electrolytes, and liver function tests) were found unremarkable. Ultrasonography (whole abdomen) showed a heterogeneous SOL noted around spleen, likely to be abscess. Upper GI endoscopy and colonoscopy were also normal. CECT (whole abdomen) reported a heterogeneous mass (measuring 11 cm X 11 cm) at left upper quadrant, medial to spleen, compressing the stomach, neoplastic lesion.

Patient was adequately prepared. Exploratory laparotomy performed via a left thoraco-abdominal incision with patient in left flank - torque position. A huge irregular mass found involving spleen, tail of

pancreas, gerota's fascia and greater curvature of stomach, having adhesion with diaphragm and omentum. No enlarged lymph nodes were found. En-bloc excision of mass along with spleen, tail of pancreas, and a sleeve of stomach including the greater curvature was preformed. The stomach was repaired in two layers. Thorax and abdomen closed after placement of intercostal and abdominal drains.

Histopathology report came out to be high risk GIST (D/D lymphoma), mucosa of stomach being uninvolved. Review of slide revealed features of lymphoma. Immunohistochemistry showed it to be positive for CD45, CD20, BCL2 and BCL6, negative for CD10, CD5 and C-Myc and finally confirming it to be Diffuse Large B-Cell Lymphoma of stomach (DLBCL).

Initial recovery was uneventful, but on 10th post op day profuse serous discharge from wound was noted, having increased amylase but not lipase. Oral gastrograftin study revealed a controlled gastrocutaneous fistula. Patient was put on nil orally and TPN and later feeding was established through jejunostomy. About 100 ml fistula output continued for next 2 weeks. In addition, there was new onset cervical lymphadenopathy, biopsy of which came out to be DLBCL. Patient was later discharged for R-CHOP chemotherapy.

DISCUSSION:

The chief objective of outlining this case report was to highlight the uncommonness of the case. In addition there are a few peculiarities in this case which attracts attention and discussion.

Gastrointestinal tract is the most common extra-nodal site involved by lymphoma accounting for 5%-20% of all cases [1]. Although virtually lymphoma can arise from any region of the gastrointestinal tract, the most commonly involved sites in term of its occurrence are the stomach followed by small intestine and ileo-cecal region [7]. Primary gastrointestinal lymphoma (PGL), however, is very rare, constituting only about 1% - 4% of all gastrointestinal malignancies and 2% - 8% of all cases of primary gastric cancer [2-5].

Histopathologically, almost 90% of the primary gastrointestinal lymphomas are of B-cell lineage with very few T-cell lymphomas and Hodgkin lymphoma. There are two subtypes of PGL, namely diffuse large B-cell lymphoma (DLBCL) and Mucosa-associated lymphoid tissue (MALT) gastric lymphoma.

Most patients are older than 50 years, with disease being most common in the sixth decade. Men are affected more often than women, and it's more common in whites than blacks [10-13]. Many patients experience symptoms, which are vague and nonspecific,

for four to ten months prior to diagnosis [13, 14]. Symptoms are mostly referable to the upper gastrointestinal tract and resemble peptic ulcer disease or gastritis.

There are some salient features of this case which satisfy the Dawson's *criteria* [6] in favor of diagnosis of Primary Gastric Lymphoma. The criteria consist of the following:

1. Absence of peripheral lymphadenopathy at the time of presentation.
2. Lack of enlarged mediastinal lymph nodes (Chest X Ray).
3. The white blood cell count (both total and differential) was normal.
4. Predominance of bowel lesion at time of laparotomy with lymph nodes affected only in the close vicinity.
5. No involvement of liver and spleen.

Certain risk factors have been implicated in the pathogenesis of gastrointestinal lymphoma including *Helicobacter pylori* (*H. pylori*) infection, human immunodeficiency virus (HIV), celiac disease, *Campylobacter jejuni* (*C. jejuni*), Epstein-Barr virus (EBV), hepatitis B virus (HBV), human T-cell lymphotropic virus-1 (HTLV-1), inflammatory bowel disease (IBD) and immunosuppression [8, 9]. However, our patient was neither found immunocompromised nor found afflicted with any viral disease.

Our patient never had any symptoms like cramping pain and dyspepsia which is common in PGL [11, 15]. In a report by Doyle and Dixon [16] describing the CT features of 19 patients with primary gastric lymphoma, the most common and interesting findings were clefts and tracks that have been suggested to be specific and peculiar to these lesions. These were seen in nine scans, while other features included diffuse wall thickening (7), lymphadenopathy (5) rugal prominence (4), and intraluminal mass (3). These features were missing in our case where there was an exophytic swelling.

According to the Lugano Staging System [20] for Gastrointestinal Lymphomas, the stage was IIE in this case (Penetration of serosa to involve adjacent organs or tissues). Historically, surgical excision has been the mainstay of treatment. Stage I and stage II disease is usually amenable to curative resection, but the resectability rate in all patients regardless of stage ranges from between 52% to 76% [17-19]. There has been much debate regarding whether chemotherapy and/or radiotherapy can be used to replace surgical resection as the primary modality treatment but it has been suggested that surgery be used for large tumors that are unlikely to regress on medical treatment. In our case, en-bloc excision of mass along with involved and adhered part of organs was done and later he was discharged for R-CHOP chemotherapy.

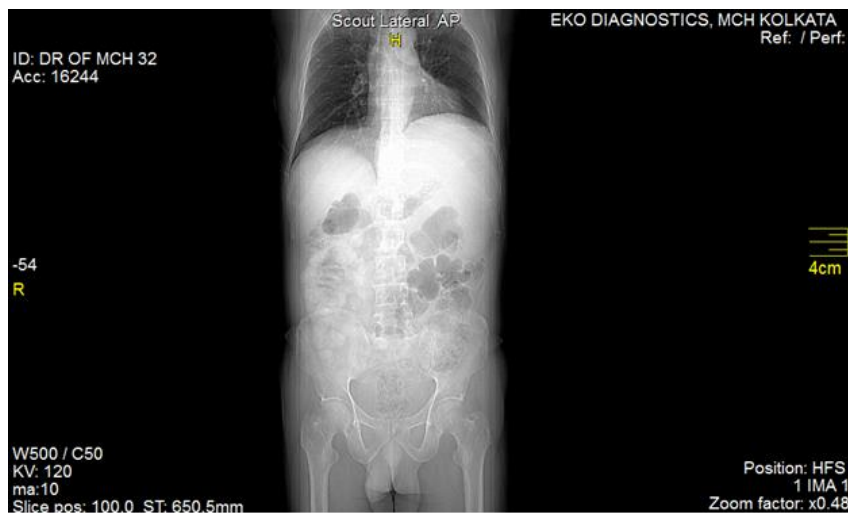

Fig 1: Coronal cut in CECT scan showing inferior displacement of gut.

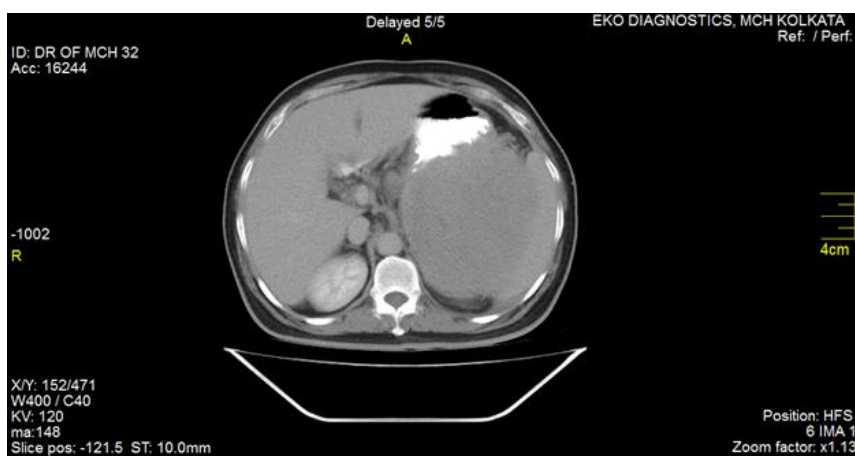


Fig 2: CECT scan showing a large mass medial to spleen compressing the stomach.

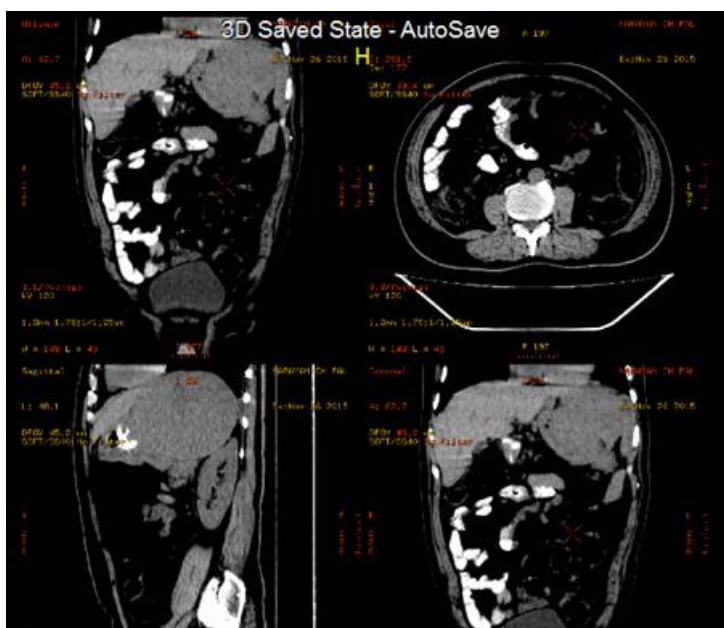

Fig 3: 3D reconstructed image from CECT scan showing extent of mass.

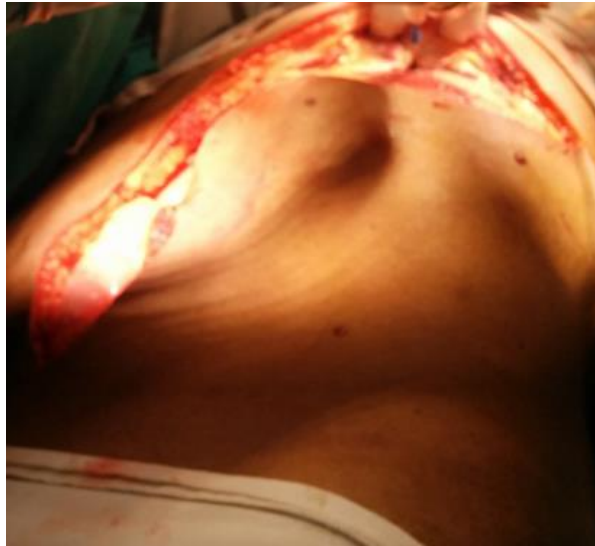

Fig 4: Left thoraco-abdominal incision in a left flank-torque position.

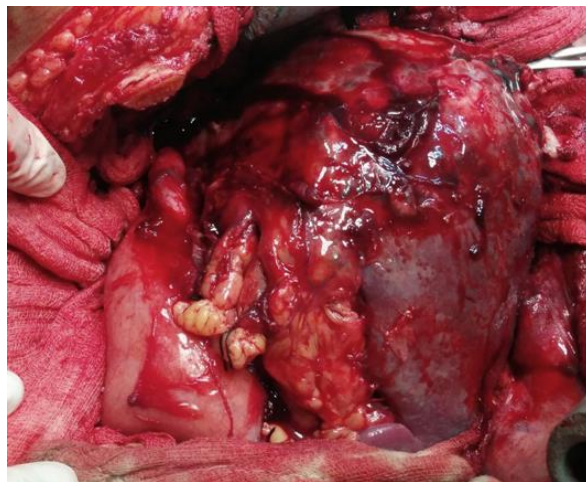


Fig 5: The mass involving greater curvature of stomach and adjacent structures, seen on exploration.

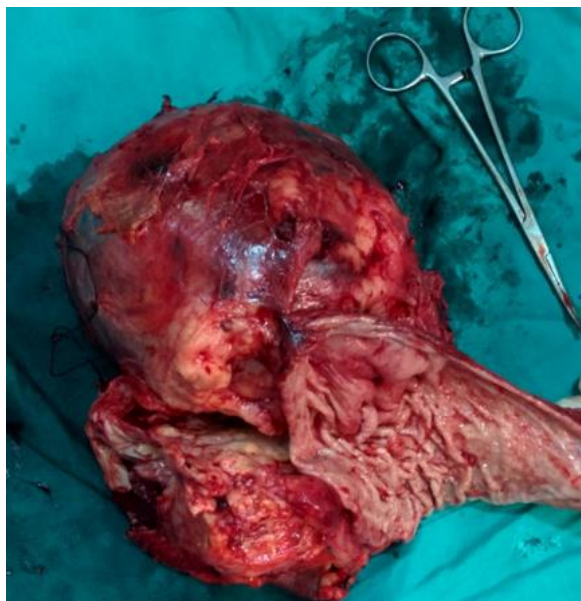


Fig 6: En-bloc excised mass along with spleen, tail of pancreas, and a sleeve of stomach along the greater curvature.

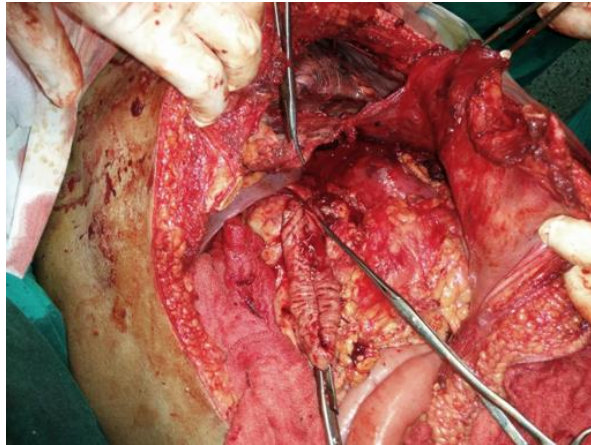


Fig 7: The operative field after excision of tumor.

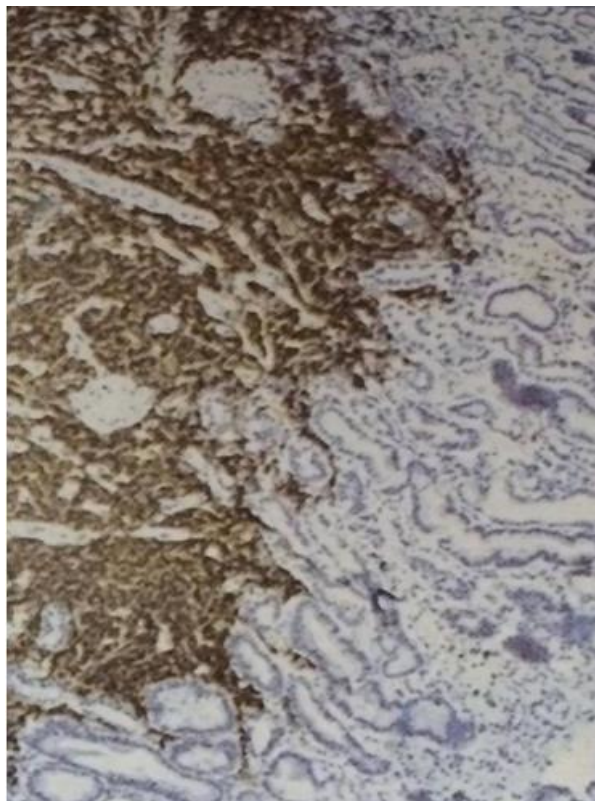


Fig 8: Histopathology slide showing features of lymphoma.

CONCLUSION:

This case presented with features of early satiety and nausea but without any pain, vomiting, hematemesis or melena. Clinical examination and investigations revealed a heterogenous SOL (11 cm X 11 cm) at left upper quadrant, medial to spleen, compressing the stomach. Following en-bloc resection, histopathology and subsequently immunohistochemistry it was confirmed to be a case of Diffuse Large B-Cell Lymphoma of stomach (DLBCL). Postoperative period was eventful but with good recovery. This case illustrates that Primary Gastric Lymphoma (PGL) can present atypically but we need to be attentive for proper diagnosis and management.

REFERENCES:

1. Schutze WP, Halpern NB; Gastric lymphoma. *Surg Gynecol Obstet.* 1991; 172:33–38.
2. Sandler RS; Primary gastric lymphoma: a review. *Am J Gastroenterol.* 1984; 79(1):21–25.
3. Cogliatti SB, Schmid U, Schumacher UR.S, Eckert F, Hansmann M.L, Hedderich J *et al.*; Primary B-cell gastric lymphoma: a clinicopathological study of 145 pts. *Gastroenterology.* 1991; 101(5):1159-1170.
4. Hayes J, Dunn E; Has the incidence of primary gastric lymphoma increased? *Cancer.* 1989; 63:2073–2076.
5. Rosen CB, Van Heerden JA, Martin Jr. JK, Wold L.E, Ilstrup D.M; Is an aggressive surgical

- approach to the patient with gastric lymphoma warranted? *Ann Surg.* 1987; 205(6):634–640.
6. Dawson IMP, Cornes JS, Morrison BC; Primary malignant lymphoid tumours of the intestinal tract. *Br J Surg.*1961; 49: 80–89.
 7. Herrmann R, Panahon AM, Barcos MP, Walsh D, Stutzman L; Gastrointestinal involvement in non-Hodgkin's lymphoma. *Cancer* 1980; 46: 215-222.
 8. Engels EA; Infectious agents as causes of non-Hodgkin lymphoma. *Cancer Epidemiol Biomarkers Prev* 2007; 16: 401-404.
 9. Müller AM, Ihorst G, Mertelsmann R, Engelhardt M; Epidemiology of non-Hodgkin's lymphoma (NHL): trends, geographic distribution, and etiology. *Ann Hematol* 2005; 84: 1-12.
 10. Jones RE, Willis S, Innes DJ, Wanebo H.J; Primary gastric lymphoma: problems in staging and management *Am J Surg.* 1988; 155(1):118-123.
 11. Brooks JJ, Enterline HT; Primary gastric lymphomas: a clinicopathologic study of 58 cases with long-term follow-up and literature review. *Cancer.* 1983; 51:701-711.
 12. Contreary K, Nance FC, Becker WF; Primary lymphoma of the gastrointestinal tract. *Ann Surg.* 1980; 191:593-598.
 13. Frazee RC, Roberts J; Gastric lymphoma treatment: medical versus surgical. *Surg Clin North Am.* 1992; 72:423-431.
 14. Sandler RS; Has primary gastric lymphoma become more common? *J Clin Gastroenterol.* 1984; 6:101-107.
 15. Rackner VL, Thirlby RC, Ryan JA; Role of surgery in multimodality therapy for gastrointestinal lymphoma. *Am J Surg.* 1991; 161(5):570-575.
 16. Doyle TC, Dixon AK; Pointers to the diagnosis of gastric lymphoma on computed tomography. *Australas Radiol.* 1994; 38:176-178.
 17. Rosen CB, van Heerden JA, Martin JK Jr; Is an aggressive surgical approach to the patient with gastric lymphoma warranted? *Ann Surg.* 1987; 205:634-640.
 18. Ichiyoshi Y, Toda T, Nagasaki S, Minamizono Y, Yao T, Sugimachi K; Surgical approaches in primary gastric lymphoma and carcinoma. *Int Surg.* 1992; 78(2):103-106.
 19. Hockey MS, Powell J, Crocker J, *et al.*; Primary gastric lymphoma. *Br J Surg.* 1987; 74:483-487.
 20. Rohatiner A, d'Amore F, Coiffier B, Crowther D, Gospodarowicz M, Isaacson P *et al.*; Report on a workshop convened to discuss the pathological and staging classifications of gastrointestinal tractlymphoma. *Ann Oncol.* 1994; 5(5):397-400.