

A case report on the management of a rare case of a giant intraabdominal testicular tumour

Dr. Saptarshi Mukherjee, Dr. Partha Pratim Das, Dr. Tapan Kumar Mandal, Dr. Tapas Kumar Majhi, Dr. Krishnendu Maiti

Department of Urology, Nil Ratan Sircar Medical College & Hospital, Kolkata, India

***Corresponding author**

Dr. Saptarshi Mukherjee

Email: urodsaptarshi@gmail.com

Abstract: A case of malignant change within an intra-abdominal testis is reported. The development in a 30 year old man of a malignant testicular lesion (seminoma) on histological examination, the absence of serum tumour markers in the presence of a seminoma and the presence of local invasive spread--all uncommon features of testicular tumours together with its management by neoadjuvant chemotherapy followed by surgery--in combination make this a rare case. Orchiopexy does not reduce the risk of malignant transformation and in the post pubertal patient does not affect spermatogenesis. Orchiectomy is therefore advised for all maldescended testes and should be considered mandatory for all intra-abdominal testes.

Keywords: chemotherapy, intra-abdominal, orchiectomy, undescended.

INTRODUCTION

During embryological development, the testes develop in the abdomen and later descend into the scrotal sac in the third trimester, usually between weeks 28 to 32. It may be arrested anywhere along its descent (cryptorchidism) or may migrate into an abnormal position (ectopic testis) [1]. Cryptorchidism, the most common congenital anomaly of the genitourinary tract in males, is found in 1% of boys [2].

In cryptorchid testicles, the incidence of testicular cancer is considered to be 3 to 48 times more than in the general population. Testicular cancer is developed in 10% of the cases with undescended testicles [3]. Various tumor markers are available in the form of alpha fetoprotein (α -FP), beta human chorionic gonadotrophin (β -HCG), lactate dehydrogenase (LDH), and placental alkaline phosphatase (PLAP). They are helpful not only in providing diagnosis but also in formulating a management plan and also in prognosticating the patients. Their sensitivity and specificity vary according to the type of testicular tumor [4].

Due to measures of prevention in force, it is uncommon to find cases of tumors in intra-abdominal testicles. This case report presents a new case of an adult patient with a huge intra-abdominal testicular tumor who has been managed with neoadjuvant chemotherapy followed by surgery.

CASE REPORT

A 30-year-old patient presented to us with complaints of lower abdominal pain and a rapidly

progressive swelling in his right lower abdomen for 1 month. The pain was dull aching in nature, mild in severity. There was no history of weight loss or change in appetite.

On physical examination, his head and neck examinations were within normal limits, and there was no lymph node enlargement. His chest was clear to auscultation, and no cardiac murmur was audible. Abdominal examination revealed a non-tender mass stony hard in consistency and fixed to the surrounding structures, approximately of the size 10 by 11 cm, located in right lower quadrant; there was, however, no hepatosplenomegaly, no inguinal hernias, and no lymph node enlargement.

Scrotal examinations revealed a normal left testis and scrotum, whereas the right testis was neither palpable in the scrotum nor in the inguinal region.

Tumor markers were performed \times -Beta-HCG: 126.2 mIU/ml, AFP-1.2 ng/ml, LDH-704 IU/ml. CT scan revealed a well-defined enhancing mass lesion measuring 114 mm \times 88 mm noted in the infra umbilical region extending towards right iliac fossa with some necrotic areas. The mass displaced the small bowel loops and also the bladder. Chest X-ray was normal.

CT guided tru cut biopsy was taken. The report was suggestive of seminoma. He was then planned for neoadjuvant chemotherapy. He received 3 cycles of Bleomycin (30 units), Etoposide (100mg) and Cisplatin (20mg).

CT was again done after completion of the 3rd cycle. It revealed the previous mass has shrunk to around 6.3cm × 4.7cm. The fat planes with the psoas, bladder and the bowel loops appeared to be maintained.

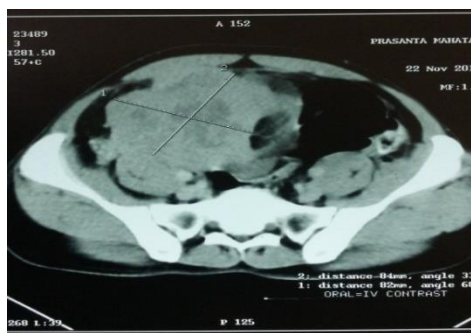

Fig 1: Pre chemotherapy CT scan picture of the testicular mass compressing urinary bladder and the bowel loops

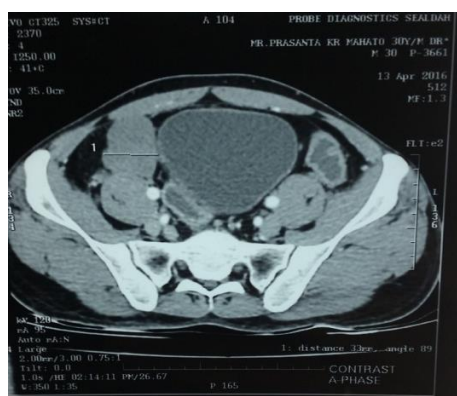


Fig 2: Post chemotherapy picture of the testicular mass which has grossly reduced in size

Laparotomy was done through lower midline incision and total excision of the tumor was carried out. No adhesion or infiltration into the surrounding structures was noted. The resection was performed without complications, and the postoperative period was uneventful.

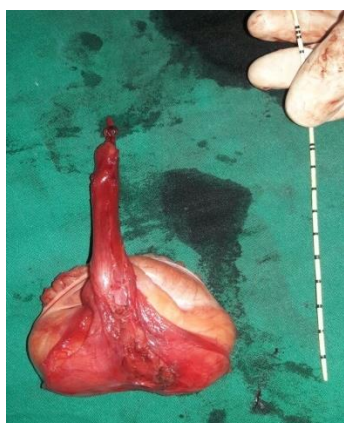


Fig 3: Photograph of the resected specimen which was essentially the testis with the epididymis

The pathological report was consistent with residual germ cell tumour favouring seminoma with degenerative change in abdominal testis (ectopic) and epididymis.

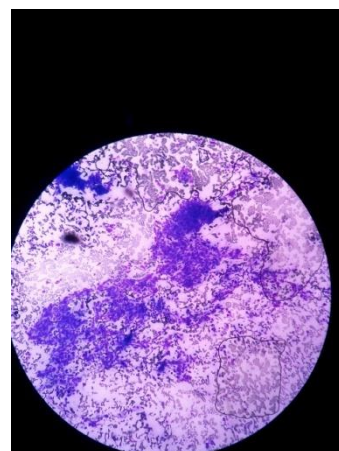


Fig 4: Histopathological slide showing the germ cell tumour

Post-operative tumour markers were found to be within normal limits.

DISCUSSION

During the developmental period the testis may get arrested anywhere along its path of descent (cryptorchidism) or may migrate into an abnormal position (ectopic testis). The common sites of undescended testis are high scrotal (50%), canalicular (20%), and abdominal (10%), bilateral (10%) [1]. The risk of development of malignancy in an ectopic testis is 40 times higher than in a normal testis. Furthermore, an abdominal testis is four times more likely to undergo malignant degeneration than an inguinal testis [2]. The peak age of incidence for the cancer is in the third or fourth decade of life[2]. In this case the testis was in intraabdominal location.

Tumor commonly detected in an abdominal testis is a seminoma, but tumors in testes previously corrected by orchiopexy are more likely to be nonseminomatous origin [5]. As was in our case where the tumour was found to be a seminoma.

In ultrasonographic scanning, most GCTs (giant cell tumors) are solid, hypoechoic tumors. Necrosis and hemorrhage may manifest in the form of cystic degeneration. CT and MRI show heterogenous soft tissue mass and retroperitoneal lymphadenopathy. CT shows calcifications better and MRI is superior in terms of detecting hemorrhage. Imaging and laboratory studies especially the tumour markers (α -FP and B-HCG) not only help in clinching the diagnosis but also aids in prognosis. Exploratory laparotomy with retrieval of the specimen ultimately provides the pathological diagnosis [5].

Undescended testes with intra-abdominal testes are more likely to be seminomas. Seminoma is a germ cell neoplasm of the testis. For this reason, testicular cancer should be considered as the differential diagnosis of an abdominal mass in patients with a nonpalpable testis. In this scenario also a high degree of clinical suspicion was maintained that led to the diagnosis and early management.

Two hypotheses have been proposed to explain this association. The first one posits that local temperature elevation of an ectopic testis is, somehow, procarcinogenic. If this hypothesis is true, then orchidopexy (testis descend and fixation in the scrotum) could protect against cancer if the procedure is performed before precancerous cells differentiate to a critical point such as that of puberty. The second hypothesis states a possible hormonal aetiology predisposing to both cryptorchidism and testicular cancer. If so, orchidopexy is not preventive for the testicular cancer; and orchidectomy would be required [2].

A high intra-abdominal temperature has been incriminated as the cause of carcinogenesis in the testis. There may be a decrease in the spermatogenesis, Leydig cell abnormality, and delay in the development of the Sertoli cells in the testis, leading to infertility [6]. In our case, there was no evidence of sterility due to the testicular malfunction and the patient had two children. Painless enlargement of the testis, or abdominal mass, is the common mode of manifestation in a cryptorchid testis. Rarely, an abdominal testicular tumor can cause a massive abdominal mass which was the case in our patient [6].

Various imaging modalities are available to diagnose and stage the condition. Classically, scrotal ultrasonography shows hypoechoic intratesticular mass in seminoma and at times with some calcification and cystic changes though mainly in nonseminomas. CT scanning of the abdomen and the pelvis is a very sensitive tool for the metastatic evaluation, which definitely helps plan the management. CT scan of the chest can usually be omitted unless there is an abnormal CXR finding [7].

In developed countries, the existence of undescended testicles in the adult population is rare, which is due to systematic practice of elective orchidopexy before the second year of life to prevent cancer and infertility. Orchidopexy does not eliminate cancer risk but allows an early diagnosis by making testicles accessible to exploration [3].

CONCLUSION

Despite the elevated risk of testicular cancer in patients with intra-abdominal testicles, we consider it a low incidence disease. However a high degree of clinical suspicion is required in any young patient

presenting with an abdominal mass on the backdrop of an undescended testis.

Neoadjuvant chemotherapy in selected cases may be of significant benefit though surgery remains the standard of care and may be facilitated by application of neoadjuvant chemotherapy when judiciously used.

REFERENCES

1. Dahnert W; Radiology review manual. 5th ed. Williams and Wilkins, Testicular tumor; 2003; 925.
2. Alshyarba MH; A giant intra-abdominal testicular seminoma. *Biomed Res.* 2010; 21(3):227–229.
3. Cristián Palma C, Cristóbal B, Maccioni R; Seminoma in an adult cryptorchid testis (intra-abdominal): a case report. *Actas Urol Esp.* 2007; 31(2):160–163.
4. Shrestha B, Baidya JL; Unresolved abdominal mass. *Kathmandu Univer Med J.* 2009; 7(25):82–85.
5. Chandrasekharan LV, Abdl Ghaffar T, Venkatramana M, Rath S; A case of teratocarcinoma. *Internet J Radiol.* 2005; 4(1).
6. Haque MM, Siddique AB, Rabbani ABMG, Quasem MA, Rahman AKMG, Rahman MM; Seminoma in undescended intra-abdominal testis: a case report. *TAJ: Journal of Teachers Association.* 2005; 18(2):131–133.
7. Joseph C, Presti JR; Genital tumours. In: Tanagho EA, McAninch JW, editors. *Smith's general urology.* 17th Ed. New York, NY: Lange Medical Books/McGraw-Hill, Medical Publishing Division; 2008; 375–382.