

Rupture of an Unscarred Uterus: An Atypical Presentation

Dr. Deeba Khanam

Assistant Professor, Dept. of Obs and Gynae, JNMCH, AMU Aligarh, UP, India

***Corresponding author**

Dr. Deeba Khanam

Email: khanamdeeba@gmail.com

Abstract: Uterine rupture is a rare but life threatening emergency and its immediate diagnosis and treatment is of prime importance as it could lead to mortality of both mother and the baby especially in developing countries where birth is attended by untrained professionals. Rupture uterus can present atypically and this might pose a challenge in making of diagnosis, as in our case where a young primipara with no previous surgical scar, presented with abdominal pain post normal vaginal delivery and it took 6 hours to diagnose the case as our patient had no risk factors. She was operated and a rent of 7x8 cm was found on anterior uterine segment which was repaired. Thus in absence of typical signs a postpartum patient with abdominal pain should always be evaluated very carefully.

Keywords: Rupture, unscarred uterus, malpresentations, congenital anomaly.

INTRODUCTION

Rupture uterus is a grave obstetrical emergency and is associated with maternal and fetal morbidity and mortality [1]. Previous caesarean section is the major contributory risk factor for uterine rupture [2]. Though rare but cases without any scars on uterus have been reported. Unscarred uterus is least likely to rupture and predisposing factors associated with it are malpresentations, multiparity, manual maneuvers, instrumentation, neglected labor, congenital uterine anomalies and augmented labor [3]. Overall incidence of uterine rupture is 0.07%. The incidence of rupture in an unscarred uterus in developed countries is 0.012% and in developing countries it is 0.11% [4]. This difference is mainly due to difference in the levels of obstetrical care, illiteracy, health education, socioeconomic status and malpractices by untrained health professionals.

Typically it presents with severe abdominal pain, bleeding per vaginum, hypotension, tachycardia, fetal bradycardia, loss of uterine contour but sometimes it has atypical presentations like chest pain, unexplained bradycardia [5]. Certain studies have proposed that unscarred uterus when ruptures is more fatal as there is no confined weak area so rupture extends to other vital organs and as there is no history of surgical intervention previously so diagnosis is usually delayed which increases morbidity [6-9].

Ours is a rare presentation as the patient was primi with no known risk factors and the patient did not display typical signs and symptoms of rupture uterus so the diagnosis was delayed and therefore this case report emphasizes the importance of clinical suspicion for early diagnosis and timely management of the patient

which results in decreased morbidity and mortality of the patient.

CASE REPORT

A 23 year old P1+0 presented to labor room 4 hours after delivery at home. She had delivered a live female baby following which she complained of severe pain in lower abdomen, for which she was brought to labor room. At arrival her BP was 110/70, PR was 98/minute, temp was 98 degree and respiratory rate was 22 per minute and she was conscious and oriented and pain was relieved as she had received certain pain killers. Per abdomen uterus was contracted and contour could be made out, bogginess was felt at lower abdomen and mild tenderness was present. Per speculum and per vaginal examination showed minimal bleeding. Her Hb was 6 gm% TLC was 10000.

She was transfused 3 units of packed RBCs and 3 units of FFP. Injectable antibiotics were given and she was kept under strict observation with vital charting. Her BP was maintained but tachycardia did not settle and started to increase from 98 to 120 within 2 hours without any distention of abdomen so USG was done which showed a hematoma on anterior lower uterine segment around 6x5 cm. Decision for laprotomy was taken. Per operatively minimal amount of blood was present in the peritoneal cavity, a large hematoma of 7x8 cm was present on anterior lower uterine segment and beneath which a transverse rent of 6 cm was found as shown in figure. Uterus was repaired and PR settled to 92 per minute. She was discharged on day 10 in satisfactory condition.

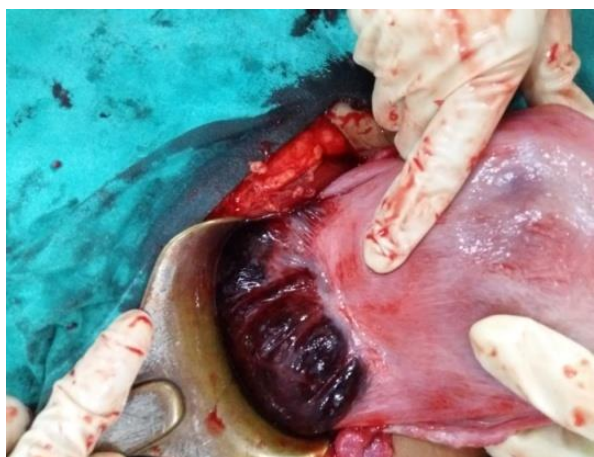


Fig-1: Rupture Uterus in an unscarred uterus

In this case definite management was delayed as rupture uterus was a remote possibility because the patient was primi and anemic and tachycardia was explained by her anaemia. Per abdominal findings did not correlate with rupture uterus as there was no distention or other features of peritonitis. Her delivery was uneventful and no history of instrumentation was there according to the patient and the baby was healthy.

It was an unusual presentation of rupture uterus where unscarred uterus ruptured during labor or post-partum and the bleeding from the ruptured site occurred slowly at intervals forming a hematoma and did not result in immediate vitals deterioration and took 6 hours to get detected. Thus a high index of suspicion of rupture uterus should be kept in mind even when the patient is primi Para.

DISCUSSION

Uterine rupture is a life-threatening emergency which should be promptly diagnosed and managed but unfortunately it is difficult to diagnose specifically in a non-scarred uterus. Its varied presentation and no consistent signs and symptoms have made its diagnosis all the more difficult. RCOG has given a time limit of 30 minutes from rupture to diagnosis to prevent fetal morbidity but it seems irrelevant as once placenta is extruded severe hypoxia cannot be prevented.

Rupture during intrapartum period and in multiparous women was found to be more common as suggested by Golan *et al* [7] Schrimsky and Benson, [10] however multiparity was found only in 0.005% of all the ruptured cases reported by Gardeil *et al* [11] and similarly our patient was also a primi patient without any previous scar who presented to us during postpartum period although it was not clear whether it ruptured during labor or in postpartum period.

Induced or augmented labor is also considered a risk factor for uterine rupture as reported by Mokgokong and Marivate [12] and Rahman *et al* [13] but in our case patient's delivery was not attended by

any traditional birth attendant and was conducted at home so rare possibility of it being augmented.

Nahum *et al* and Ravasia *et al* [4, 14] reported that uterus ruptured more frequently in malformed uterus with congenital anomalies but per operatively we did not find any uterine anomalies in our patient.

Fundal pressure is one commonly applied maneuver which can cause trauma to an unscarred uterus [15, 16]. Rupture is associated with high maternal and fetal mortality as reported by Gurudut *et al* and Sakr *et al* [17,18] but our patient didn't give such history and not only did she survive well but her baby was also healthy.

Thus all the possible risk factors which could lead to uterine rupture were absent in our case and so immediate diagnosis and management was delayed. Diagnosis is usually clinical and treatment is surgical so a high index of suspicion should be maintained in pregnant as well as delivered patients without any known risk factors to avoid any adverse outcomes.

REFERENCES

1. Ofir K, Sheiner E, Levy A; Uterine rupture: risk factors and pregnancy outcome. *Am J Obstet Gynecol.*, 2003;189:4.
2. Smith JG, Mertz HL, Merrill DC; Identifying risk factors for uterine rupture. *Clin Perinatol.*, 2008; 35:85–99.
3. Bretones S, Cousin C, Gualandi M, Mellier G; Uterine rupture. A case of spontaneous rupture in a thirty week primiparous gestation. *J Gynecol Obstet Biol Reprod (Paris)*, 1997; 26:324e327.
4. Nahum GG, Pham KQ; Uterine rupture in pregnancy. *E Medicine* from Webmed, 2008. Available from: <http://emedicine.medscape.com/article/275854-overview>.
5. Yussof SM, Hsuan CC; An Unusual Presentation of Rupture in an Unscarred Uterus . *Journal of Critical Care Obstetrics and Gynecology*, 2016; 2(2).
6. Lao TT, Leung BFH; Rupture of the gravid uterus. *Eur J Obstet Reprod Biol.*, 1987; 25:175-180.
7. Golan A, Sandbank O, Rubin A; Rupture of the pregnant uterus. *Obstet Gynecol.*, 1980; 56: 549-554.
8. Chen LH, Tan KH, Yeo GS; A ten-year review of uterine rupture in modern obstetric practice. *Ann Acad Med Singapore*, 1995; 24:830-835.
9. Van der Merwe JV, Ombelet WU; Rupture of the uterus: a changing picture. *Arch Gynecol.*, 1987; 240:159-171.
10. Schrimsky DC, Benson RC; Rupture of the pregnant uterus: a review. *Obstet Gynecol Surv.*, 1978; 33(4):217-32.

11. Gardeil F, Daly S, Turner MJ; Uterine rupture in pregnancy reviewed. *Eur J Obstet Gynecol Reprod Biol.*, 1994; 56(2):107-10.
12. Mokgokong ET, Marivate M; Treatment of the ruptured uterus. *S Afr Med J.*, 1976; 50(41):1621-4.
13. Rahman J, Al-Sibai MH, Rahman MS; Rupture of the uterus in labor. A review of 96 cases. *Acta Obstet Gynecol Scand.*, 1985; 64(4):311-5.
14. Ravasia DJ, Brain PH, Pollard JK; Incidence of uterine rupture among women with mullerian duct anomalies who attempt vaginal birth after cesarean delivery. *Am J Obstet Gynecol.*, 1999; 181(4):877-81.
15. Pan HS, Huang LW, Hwang JL, Lee CY, Tsai YL, Cheng WC; Uterine rupture in an unscarred uterus after application of fundal pressure. *J Reprod Med.*, 2002; 47:1044-1046.
16. Wei SC, Chen CP; Uterine rupture due to traumatic assisted fundal pressure. *Taiwan J Obstet Gynecol.*, 2006; 45:170-172.
17. Gurudut KS, Gouda HS, Aramani SC, Patil RH; Spontaneous rupture of unscarred gravid uterus. *J Forensic Sci.*, 2011; 56(Suppl. 1):S263eS265.
18. Sakr R, Berkane N, Barranger E, Dubernard G, Darai E, Uzan S; Unscarred uterine rupture: a case report and literature review. *Clin Exp Obstet Gynecol.*, 2007; 34:190e192.