

## **Fine Needle Aspiration Diagnosed Skin Metastasis of Colorectal Signet Ring Cell Carcinoma**

**Dr. Ezhil Arasi N<sup>1</sup>, Dr. Sreelakshmi I<sup>2</sup>, Dr. Ajetareddy B<sup>3</sup>, Dr. Lavanya<sup>4</sup>**

<sup>1</sup>Professor and Head of department, <sup>2</sup>Associate Professor, <sup>3</sup>Senior Resident, <sup>4</sup>Assistant Professor, Upgraded Department of Pathology, Osmania Medical College/Osmania General Hospital, Hyderabad, Telangana, India

### **\*Corresponding author**

Dr. Ajetareddy B

Email: [ajeta05@gmail.com](mailto:ajeta05@gmail.com)

---

**Abstract:** Cutaneous metastasis of rectal carcinoma is rare, it occurs in <4% of patients with rectal cancer. When present, it typically signifies a disseminated disease with a poor prognosis. Early detection and proper diagnosis of metastatic colorectal cancer can significantly alter treatment and prognosis. We report a case of 65 yr old man who presented with skin nodules on the neck, axilla and abdominal wall. Fine needle aspiration cytology of skin nodules was suggestive of signet ring cell carcinoma. Skin lesion biopsy also showed signet ring carcinoma. Patient had a history colorectal carcinoma two months before he developed skin nodules. Final diagnosis of cutaneous metastasis of signet ring cell rectal carcinoma was made based on Fine needle aspiration cytology(FNAC), Histology and Immunohistochemistry.

**Keywords:** Cutaneous metastasis, FNAC, signet ring cell rectal carcinoma.

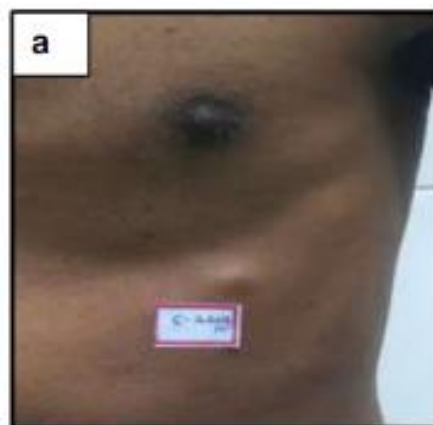
---

### **INTRODUCTION**

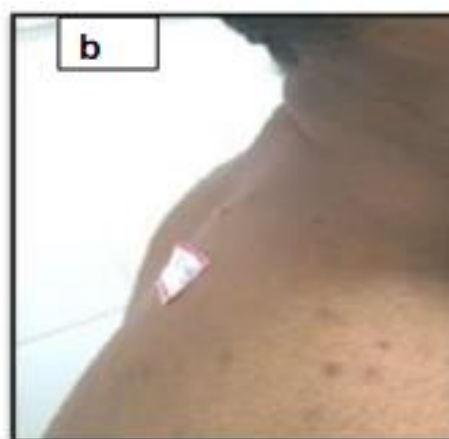
Visceral cancers may develop skin metastasis. Its incidence is reported to vary from less than 1% to 10% and occurs most frequently in older population groups. The primary tumor that most often develops metastasis to skin is breast cancer followed by lung and colorectal cancer [1-3]. The most frequent sites for skin metastasis have been reported in different studies as surgical incisions, abdominal wall or chest wall. Skin metastasis is usually a sign of terminal disease. Invasive procedures for tissue biopsy may not be proper or easy to do, due to poor survival and poor general condition. Fine Needle Aspiration (FNA) cytology is a reliable and non-invasive method for detecting skin metastasis [3-5]. The main sites of metastases in colorectal cancers are liver and lungs. Although colorectal cancers are the second most visceral human cancers causing skin metastasis, only 5% of metastatic skin lesions are from colorectal cancers [6]. Herein, we report a case of FNA diagnosed metastasis to skin from rectal cancer .

### **CASE DETAILS**

A 65yr old male presented with skin lesions on the neck, axilla and abdominal wall .On local examination skin lesions were non-tender and nodular largest nodule measuring 2X1 cm and the smallest measuring 1X0.5cm.



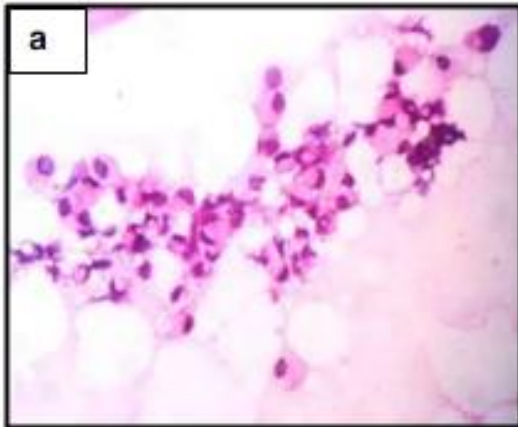
**Fig-1a: Abdominal wall skin lesion measuring 2X1 cms**



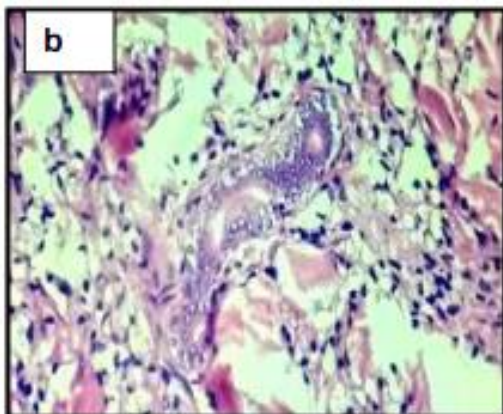**Fig-1b: Skin lesion over nape of neck measuring 1X0.5 cm**

**Microscopy Findings**

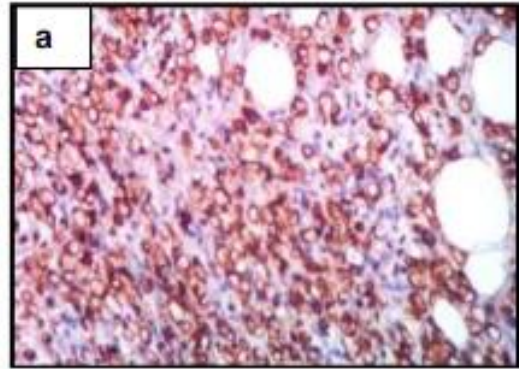
FNAC of swelling from nape of neck showed cellular cytomears with cells arranged in sheets and scattered individually. These cells have peripherally placed hyperchromatic pleomorphic nucleus with vacuolated cytoplasm – signet ring cells. Cyst macrophages and neutrophils were seen in a mucoid background. Possibility of metastatic deposit of signet ring cell carcinoma was considered on FNAC. Excision biopsy of the skin lesion also showed signet ring cells. Immunohistochemistry using panCK, CK7 and CK20 done on skin biopsy revealed panCK and CK20 positivity in tumor cells and tumor cells were negative for CK7. After FNAC and immunohistochemistry diagnosis of cutaneous metastasis of signet ring carcinoma probably from colorectum was considered.



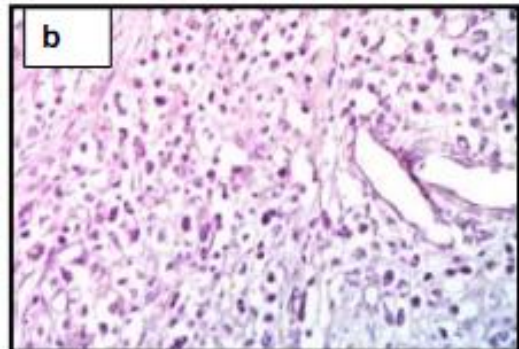
**Fig-2a: FNAC of skin lesion showing signet ring cells in clusters and scattered individually**



**Fig-2b: H&E stained section of skin lesion biopsy shows signet ring cells**

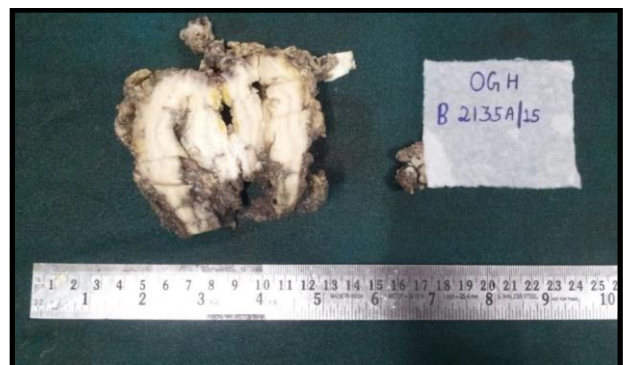

**Fig-3a: Immunohistochemistry (400X) showed CK20 positivity in tumor cells**

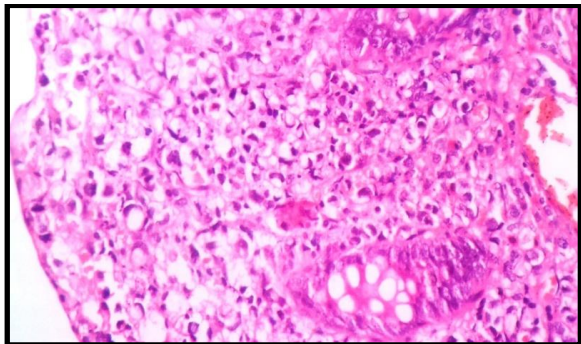


**Fig-3b: Immunohistochemistry (400X) showed CK7 negativity in tumor cells**

Patient had a history of abdominoperineal resection done for carcinoma colon two months before skin lesions developed. Resected specimen showed Adenoacarcinoma Rectum- Signet ring cell type T3NxMx-Stage II. Final diagnosis of cutaneous metastasis of signet ring cell adenocarcinoma of rectum was made based on FNAC, Histology and Immunohistochemistry.



**Fig-4: Gross specimen showing intestinal segment with thickened wall and narrowed lumen**



**Fig-5: H&E stained section shows signet ring cell carcinoma of rectum**

## DISCUSSION

Cutaneous metastasis can occur anytime in the course of malignancy. Especially in an extensively metastatic disease, they may also represent failure of ongoing therapy, recurrence of neoplasm thought to have been eradicated, or the first manifestation of asymptomatic unsuspected occult malignancy. Among all skin cancers, 2% are metastatic skin tumors and the most common primary site for these is breast cancer followed by lung and colorectal cancer [1-3]. Skin metastasis from rectal cancer is rare and occurs in less than 4% of cases. Clinical appearance of cutaneous metastasis has different features such as nodules, bullae, ulcerations, fibrotic and cellulitis-like lesions. The most common lesions are asymptomatic small nodules (1-2 cm). Considering the short estimated survival and probable poor general condition, a surgical biopsy may not be logical for these patients. FNA cytology is an accurate method for diagnosis of skin metastasis in a patient with a known malignancy. Geramizadeh and colleagues reported 25 cases of skin metastasis with no false positive or false negative for FNA results [5]. Skin metastasis are reported at different sites through the body such as abdomen, extremities, head and neck, genitalia and scars from surgery. Among them, surgery scars and abdominal skin are the most frequent sites. Cervical and thoracic skin metastases are less frequent than those on abdominal skin. In a cohort study of 413 patients with metastatic colon cancer, there were 18 patients (4.4%) with skin metastases, of whom eleven having only local metastases, mostly in the abdominal incisions [7]. Cutaneous metastases occur in less than 4% of all cases [8, 9] and can emerge through lymphatic or hematogenous routes or by direct extension or by implantation during surgery. The presence of cutaneous metastatic lesions usually represents a widely spread disease, and its presentation as initial manifestation of the disease is extremely uncommon, being typically a follow-up finding. Another aspect to be pointed out in this case is the tumor morphology. Signet-ring carcinoma is more common at other sites of gastrointestinal tract, an atypical occurrence in colorectal tumors around 0.5 to 2.0% of

the cases. Such patients tend to be younger – many of them under 50 when compared to those with other histological types but our patient was 65yrs old which is again rare.

## CONCLUSION

Herein, we report a rare case of cutaneous metastasis of signet ring cell rectal adenocarcinoma in a 65 year old man. Skin metastasis in colorectal cancer is rare. FNA cytology seems to be a proper and accurate diagnostic method for diagnosis of skin metastasis in a patient with a known malignancy. Signet-ring carcinoma is more common at other sites of gastrointestinal tract, an atypical occurrence in colorectal tumors around 0.5 to 2.0% of the cases. Such patients tend to be younger – many of them under 50 when compared to those with other histological types but our patient was 65yrs old which is again rare.

## REFERENCES

1. Sarid D, Wigler N, Gutkin Z, Merimsky O, Leider-Trejo L, Ron IG; Cutaneous and subcutaneous metastases of rectal cancer. *Int J Clin Oncol.*, 2004; 9(3):202-5.
2. Fyrmpas G, Barbetakis N, Efstathiou A, Konstantinidis I, Tsilikas C; Cutaneous metastasis to the face from colon adenocarcinoma. Case report. *Int Semin Surg Oncol.*, 2006; 3:2.
3. Nasrolahi H, Geramizadeh B, Moaddabshoar L, Hamedi SH, Mohammadianpanah W, Omidvari SH, Ansari M, Ahmadloo N, Mosalaei; Fine Needle Aspiration Diagnosed Skin Metastasis in a Young Man with Rectal Cancer. *Reports of radiotherapy and oncology*, 2013; 3(1):123-127.
4. Eichinger J, George B, Myhand R; Cutaneous metastatic rectal carcinoma masquerading as herpes zoster. *South Med J.*, 2011; 104(3):233-5.
5. Geramizadeh B, Marzban S, Karamifar N, Omidifar N, Shokripour M, Mokhtareh M; Department of Pathology, Transplant Research Center Shiraz University of Medical Sciences. *J Cytol Histol.*, 2012; 3(5).
6. Hamid GA, Hanbala N; Adenocarcinoma of the Rectum with Cutaneous Metastasis. *Middle East Journal of Cancer*, 2012; 3(1): 23-25.
7. Rendi MH, Dhar AD; Cutaneous metastasis of rectal adenocarcinoma. *Dermatol Nurs.*, 2003; 15(2):131-2.
8. Abrams HL, Spiro R, Goldstein N; Metastases in carcinoma; analysis of 1000 autopsied cases. *Cancer*, 1950; 3(1):74-85.
9. Kilickap S, Aksoy S, Dinçer M, Sağlam EA, Yalçın S; Cutaneous metastases of signet cell carcinoma of the rectum without accompanying visceral involvement. *South Med J.*, 2006; 99(10): 1137-9.