

Colon Carcinoma 14 Years after the Removal of Ovarian Cancer

Nasrin Amirifard, Edris Sadeghi*

Cancer Research Center, Kermanshah University of Medical Sciences, Kermanshah, Iran

*Corresponding author

Edris Sadeghi

Email: sadeghi_mkn@yahoo.com

Abstract: Ovarian epithelial carcinoma is one of the most common gynecological cancers and colorectal cancer is the fourth most common cancer in men and the third most common in women. Herein, we report a patient who presented with an adenocarcinoma of the colon of fourteen years after an ovarian adenocarcinoma. A 54-year-old female patient underwent laparotomy due to severe abdominal and pelvis pain. Which sample was excised and sent for histopathology. Her levels of CA125 and lactate dehydrogenase were 131.8 U/mL and 898 U/mL, respectively. The patient then received 6 courses of cisplatin and cyclophosphamide as neoadjuvant chemotherapy. The patient had a good response to this policy of treatment because her CA-125 level fell to normal range. About two weeks later she had a radical hysterectomy. Her condition was well some months after surgery. Fourteen years later, Pathology report indicated well differentiated adenocarcinoma; carcinoma invades through the vascular invasion and margin. The patient is alive and following up's. Distinguishing colonic metastasis and colon cancer as second malignancy may be difficult. And also colon cancer after primary ovarian cancer rarely occurs.

Keywords: Colon, CA-125, Ovarian.

INTRODUCTION

Ovarian epithelial carcinoma is one of the most common gynecological cancers [1]. Colorectal cancer is the fourth most common cancer in men and the third most common in women [3]. Pelvic ultrasound and the serum tumor marker CA-125 have been assessed as potential screening tools and a number of studies have demonstrated their ability to detect patients with ovarian cancer at a preclinical, asymptomatic stage [2]. We report the case of a patient who presented with an adenocarcinoma of the colon of fourteen years after an ovarian adenocarcinoma.

CASE PRESENTATION:

A 54-year-old female patient underwent laparotomy due to severe abdominal and pelvis pain. Which sample was excised and sent for histopathology. Following biopsy, pathological evaluation showed big tumor size (13 cm) of papillary ovarian adenocarcinoma. Her levels of CA125 and lactate dehydrogenase were 131.8 U/mL and 898 U/mL, respectively. The patient then received 6 courses of cisplatin and cyclophosphamide as neoadjuvant chemotherapy. The patient had a good response to this policy of treatment because her CA-125 level fell to normal range. Pathology image showed tumor size (3 cm) in diameter that is obtained after chemotherapy (Figure 1).

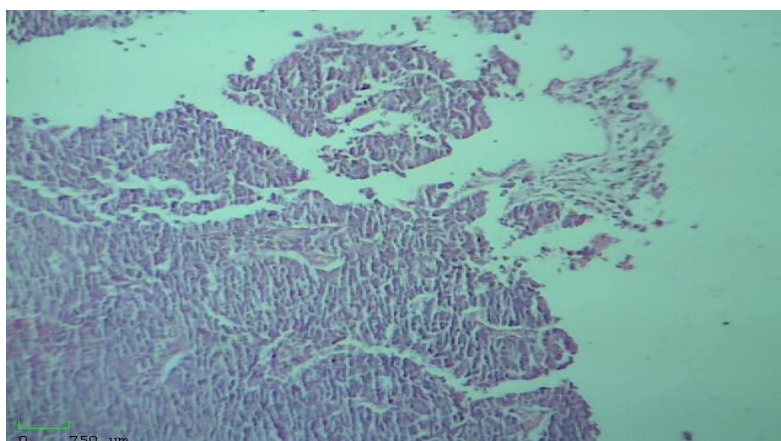


Fig 1: Malignant neoplasm composed of malignant cells with high N/Cyto ratio that arranged in gland like structure

About two weeks later she had a radical hysterectomy. Her condition was well some months after surgery. Therefore we start follow up her for several years. Unfortunately, she came to the department of radiation and oncology after some years with other complaints (like abdominal pain). Her

barium enema image showed tumor in right colon (Fig 2).

So, right hemicolectomy was performed to remove the tumor (Figure 3).

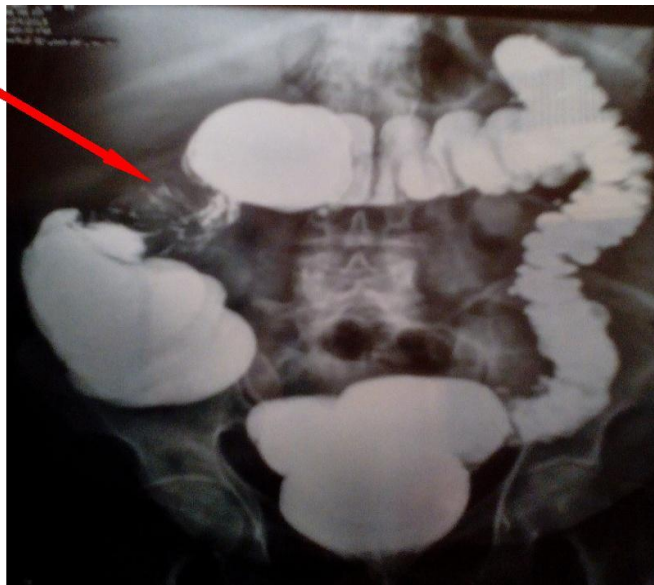


Fig 2: Barium enema screening test that showed carcinoma in the ascending colon

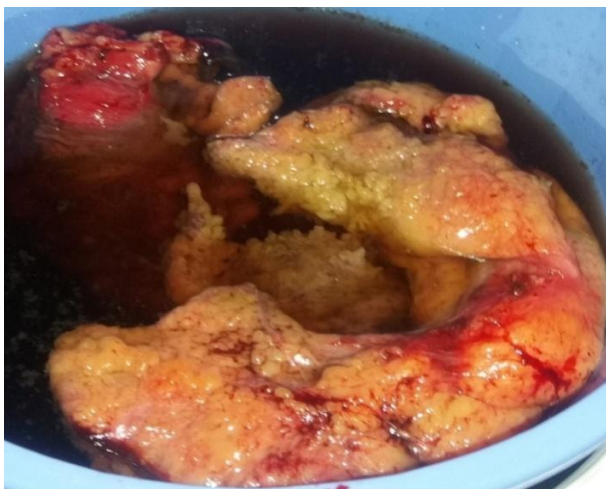


Fig 3: Image of ascending colon after surgery

Pathology report indicated well differentiated adenocarcinoma; carcinoma invades through the vascular invasion and margin (Figure 4). The patient was started on XELOX chemotherapy then we

recommended for her a bimonthly adjuvant FOLFOX chemotherapy regimen consisting of oxaliplatin and leucovorin, 5-fluorouracil (5-FU). The patient is alive and following up with this method of chemotherapy.

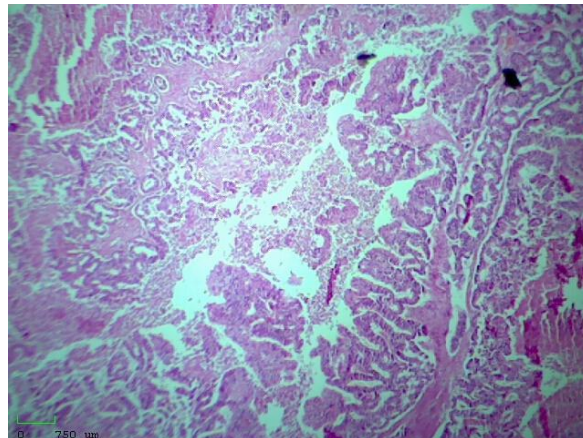


Fig 4: Full wall thicknesses of intestine occupied by a malignant neoplasm composed of bizarre cells that formed glands and sheets

DISCUSSION:

Five to ten percent of all malignant tumors involving the ovary are metastasis and frequently mistaken for primary ovarian carcinoma. Most of the ovarian metastasis arises from the gastrointestinal tract and colonic adenocarcinoma accounts for 37% to 45% [10].

The average age of patients with primary ovarian cancer was 54.50 ± 12.5 years (range 16–79 years) [6] like the patient had 54 years. Synchronous multiple primary tumors are relatively rare. While the etiology and pathogenesis of these tumors remain unclear, it has been proposed that embryologically similar tissues, when simultaneously subjected to either hormonal influences or carcinogens, may develop synchronous neoplasms [7]. According to the Swedish Family-cancer Database, after primary ovarian and endometrial carcinomas the incidence of subsequent malignancies at genitalia, bladder, and kidney increases [8]. In this case, colon cancer appeared after primary ovarian carcinoma. A study reported familial cancer syndromes, radiotherapy, and chemotherapy also may contribute to the increased occurrence of secondary primer malignancies [8]. Important laboratory test like CA125 is thought to be a prognostic and predictive tumor marker for primary ovarian tumors [4]. CA125 in our patient was very high but we could decrease it to normal range with chemotherapy and surgery. Takahashi *et al.*; [5] reported that in patients with a malignant ovarian tumor, 81.3% had positive serum CA 125. The combination of cisplatin with paclitaxel was shown to be superior to cisplatin and cyclophosphamide [9] but we used cisplatin and cyclophosphamide and we got good response in this case.

CONCLUSION:

Distinguishing colonic metastasis and colon cancer as second malignancy may be difficult. Also colon cancer after primary ovarian cancer rarely occurs.

REFERENCES:

1. Jemal A, Siegel R, Xu J and Ward E; Cancer

statistics, 2010. *CA Cancer J Clin*, 2010; 60(5): 277-300.

2. Jacobs I, Stabile I, Bridges J, Kemsley P, Reynolds C, Grudzinskas J *et al.*; Multimodal approach to screening for ovarian cancer. *Lancet*, 1988; 1(8580):268-71.
3. Madani S.H, Sadeghi E, Rezaee A, Sadeghi M, Khazae S, Amirifard N *et al.*; Survey of HER2-neu expression in colonic adenocarcinoma in the west of Iran. *Asian Pacific Journal of Cancer Prevention*, 2015; 16(17):7671-4.
4. Diaz -Padilla I, Razak AR, Minig L, Bernardini MQ, Maria Del Campo J; Prognostic and predictive value of CA-125 in the primary treatment of epithelial ovarian cancer: potential and pitfall. *Clin Transl Oncol*, 2012; 14(1):15-20.
5. Takahashi K, Shibukawa T, Moriyama M, Shirai T, Kijima S, Iwanari O, *et al.*; Clinical usefulness and false-positive results of CA 125 as a tumor marker of ovarian cancer: a study on 674 patients. *Jpn J Surg*, 1986; 16(5):305-10.
6. Stanojevic Z, Djordjevic B, Dunjic O; Metastatic tumors of the ovary: the rate of incidence and the most frequent sites of primary tumors. *Acta Medica Medianae*, 2007; 46(4):5–9.
7. Tong SY, Lee YS, Park JS, Bae SN, Lee JM, Namkoong SE; Clinical analysis of synchronous primary neoplasms of female reproductive tract. *Eur J Obstet Gynecol Reprod Biol*, 2008; 136(1): 78-82.
8. Hemminki K, Aaltonen L, Li X; Subsequent primary malignancies after endometrial and ovarian carcinoma. *Cancer*, 2003; 97(10): 2432-2439.
9. McGuire WP, Hoskins WJ, Brady MF, Kucera PR, Partridge EE, Look KY, *et al.*; Cyclophosphamide and cisplatin compared with paclitaxel and cisplatin on patients with stage III and stage IV ovarian cancer. *N Engl J Med*, 1996; 334:1-6.
10. Diognigi A, Facco C, Tibilette MG; Ovarian metastasis from colorectal carcinoma. *Am J Clin Pathol*, 2000; 114:111-122