

Clinical Correlations of Accessory Head of Flexor Pollicis Longus with Anterior Interosseous Nerve Syndrome: A Case Report

Raviprasanna KH¹, Dakshayani KR²

¹Assistant Professor, Department of Anatomy, Sree Narayana Institute of Medical Sciences, North Kuthiathode, Chalakka, Ernakulum, Kerala, India

²Professor and HOD, Department of Anatomy, Mysore Medical College and Research Institute, Mysore, Karnataka, India

***Corresponding author**

Raviprasanna KH

Email: pravi_kh81@yahoo.in

Abstract: During routine cadaveric dissection done for the undergraduate students in 2013, at the Department of Anatomy, Mysore Medical College and Research Institute, Mysore an accessory muscle head in the left forearm of a male cadaver was observed which was supplied by a branch of anterior interosseous nerve. Gantzer's muscle is an accessory portion of the flexor pollicis longus or flexor digitorum profundus muscle located in the forearm which is considered an anatomical variant. The adequate knowledge regarding muscular variations is essential not only for anatomists but also for surgeons while approaching forearm for tendon transfer of flexor digitorum superficialis or anterior approach of elbow.

Keywords: Flexor digitorum superficialis, Flexor pollicis longus, Common flexor origin, Gantzer's muscle.

INTRODUCTION

In 1813, Gantzer described an accessory muscle in the forearm which could join the flexor pollicis longus and the deep finger flexor muscle [1, 2]. However, Kaplan [3] described that this muscle was described by Albinus almost a century before. Flexor digitorum superficialis produces flexion of the middle phalanges of the fingers at the proximal interphalangeal joints and prolonged contraction leads to the flexion of the metacarpophalangeal joints and wrist joint. Flexor digitorum profundus and flexor pollicis longus belongs to deep layer of flexor compartment of the forearm. The flexor pollicis longus chiefly arises from anterior surface of shaft of the radius intervening between radial tuberosity and to the upper attachment of pronator quadratus muscle and from the adjacent interosseous membrane [4]. In addition the flexor digitorum profundus or flexor pollicis longus, muscles may have additional head which arises from the medial border of the coronoid process of the ulna or from the medial epicondyle of the humerus, such accessory heads are considered as Gantzer's muscle. The relation of gantzer muscle with the anterior interosseous nerve and median nerve is clinically important as it may compress both median and anterior interosseous nerves. Dellon and Mackinnone [5] stated that gantzer muscle is always situated posterior to the median and anterior to the interosseous nerve.

of Anatomy, Mysore Medical College and Research Institute, Mysore an accessory muscle head in the left forearm of a male cadaver was observed. The accessory head was arising in a tendinous form from the under surface of flexor digitorum superficialis muscle and was running downwards & laterally to get inserted to the medial side of flexor pollicis longus muscle [Figure no-1]. The accessory muscle was presented as fusiform shaped muscle with origin and insertion as tendinous and central belly. Its measurements were 7.4 cm in length and 1.2 cm in width and central muscular part 3.8 cm. The relations of accessory head with surrounding structures were noted down. The accessory head was deep to median nerve and superficial to anterior interosseous nerve and ulnar artery. The accessory head was supplied by a branch of anterior interosseous nerve. Persistence of median artery [Figure no-2] was also observed in the same limb which was arising from common interosseous artery and was categorised as palmar type which took part in formation of superficial palmar arch.

OBSERVATION / CASE REPORT

During routine cadaveric dissection done for the undergraduate students in 2013, in the Department

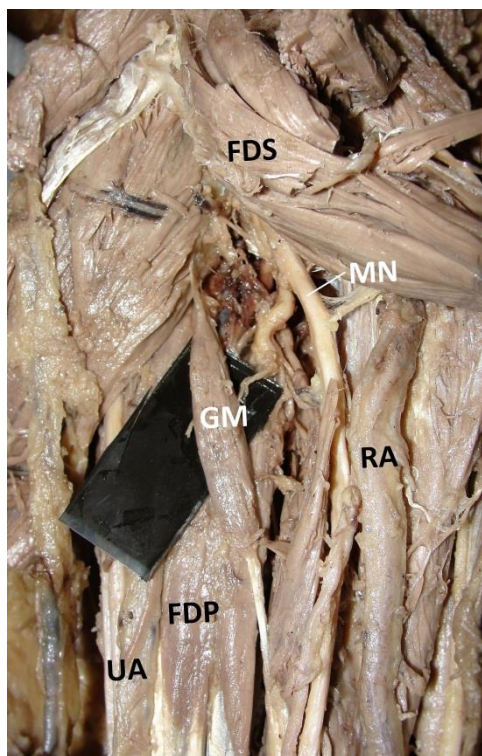


Fig-1: Anterior view of left forearm showing structures. FDS-Flexor digitorum superficialis, MN-Median nerve, RA- Radial artery, FDP- Flexor digitorum profundus, UA- Ulnar artery, GM-Gantzer's muscle

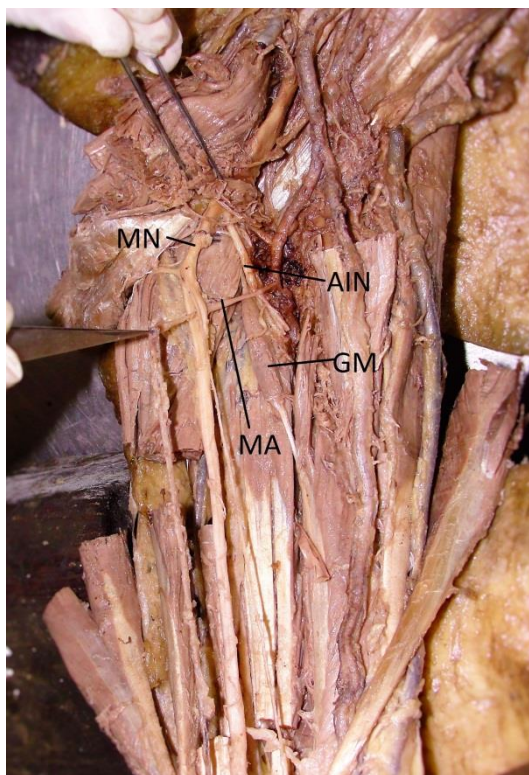


Fig-2: Showing the presence of Median artery (MA) along with Gantzer's muscle (GM). AIN- Anterior interosseous nerve, MN- Median nerve

DISCUSSION

The most common singular point of origin of Gantzer's muscle is under the surface of flexor digitorum superficialis, similar to the present case. The occurrence of Gantzer's muscle is lowest in European Caucasians (33%) and highest in the blacks (89.3%) with the Asian Japanese being midway and in Indian population (46.03%) it lies between the European Caucasians and the Asian Japanese [7, 9]. The presence of additional muscle head (present case) may be due to the incomplete cleavage of the forearm flexor muscles during development as the deep layer of the flexor muscle mass gives rise to the flexor digitorum superficialis, flexor digitorum profundus and flexor pollicis longus [8]. Al Qattan M [6] and Mahakkanukrauh P *et al.* [10] observed additional head of flexor pollicis longus originating from the medial epicondyle of the humerus in 85% and 74.5% cases respectively but Oh C S *et al.* found the same to be merely 10.4% in Asian population [11]. The Gantzer's muscle may get inserted to the flexor pollicis longus, flexor digitorum profundus or flexor digitorum superficialis. The variant muscle bellies and tendons should be kept in mind to avoid clinical complications during surgical approach of these regions. Anterior interosseous nerve syndrome occurs due to compression of the nerve either by these accessory heads in region or any other variant. Nerve compressions and tenosynovitis are the common effects of these accessory heads which surgeons should be familiar with. The imaging techniques like computed tomography and magnetic resonance imaging can be used to detect these types of anatomical variants which help for clinical diagnosis or planning of any surgical procedures in that region. These accessory heads may cause pressure neuritis and produce symptoms such as carpal tunnel syndrome, Kiloh-Nevin Syndrome or Pronator Syndrome [9]. The Kiloh-Nevin Syndrome occurs due to the compression of the anterior interosseous nerve, as in most of the cases, the nerve passes between the flexor pollicis longus muscle posteriorly and additional head of flexor pollicis longus anteriorly [7, 8]. During anterior approach to the proximal radius and the elbow joint and decompressive fasciotomy for compartment syndrome of the forearm these variants should be kept in mind by surgeons. The Gantzer's muscle is made of fusiform muscle fibers whereas the flexor pollicis longus is made of unipennate muscle fibers. The function of fusiform muscle fiber is in direct opposition to unipennate fibers. This could in turn lead to loss of precise and skillful movements [12]. Tabib, Aboufarah and Asselineau reported a case of incomplete anterior interosseous nerve syndrome due to mechanical compression by Gantzer's muscle [13]. Degreef and Smet mention a case where an older female patient with paralysis of the anterior interosseous nerve was reported; on exploration an accessory muscle slip running from the coronoid process of the ulna towards the flexor pollicis longus (Gantzer's muscle) was found compressing the nerve [14].

CONCLUSION

The knowledge of these variants and its unusual relation with adjacent neurovascular structures should be kept in mind by surgeons while approaching the elbow from front.

REFERENCE

1. Caetano EB, Sabongi Neto JJ, Vieira LA, Caetano MF, Moraes DV; Gantzer muscle. An anatomical study. *Acta Ortop Bras.*, 2015; 23(2): 72-5.
2. Wood J; Variations in human myology. *Proc R Soc London*, 1868; 16: 483-525.
3. Kaplan EB; Anatomia funcional y quirurgia de la mano. Buenos Aires: Artécnica; 1961. p. 197-250.
4. Standring S, Berkovitz BKB; Neck. In: Gray's anatomy: The anatomical basis of clinical practice. 39th ed. Edinburgh, London: Elsevier Churchill living stone, 2005;1790-92.
5. Dellon AL, Mackinnon SE; Musculo aponeurotic variations along the course of the median nerve in the proximal forearm. *J Hand Surg Br.*, 1987; 12(3):359-63.
6. Al-Qattan MM; Gantzer's muscle. An anatomical study of the accessory head of the flexor pollicis longus muscle. *J Hand Surg Br.*, 1996; 21(2):269-70.
7. Pai MM, Nayak SR, Krishnamurthy A, Vadgaonkar R, Prabhu LV, Ranade AV; The accessory heads of flexor pollicis longus and flexor digitorum profundus: Incidence and morphology. *Clin Anat.*, 2008; 21: 252-8.
8. Jones M, Abrahams PH, Sanudo JR, Campillo M; Incidence and morphology of accessory heads of flexor pollicis longus and flexor digitorum profundus (Gantzer's muscles). *J Anat.*, 1997; 191: 451-55.
9. Sawant SU, Kolekar SM; Anomalous muscle bellies in the flexor compartment of forearm- a case report. *International Journal of Recent Trends in Science and Technology*, 2014; 12(1): 28-30.
10. Mahakkanukrauh P, Surin P, Ongkana N, Sethadavit M, Vaidhayakarn P; Prevalence of accessory head of flexor pollicis longus muscle and its relation to anterior interosseous nerve in Thai population. *Clin Anat.*, 2004; 17: 631-35.
11. Oh CS, Chung IH, Koh KS; Anatomical study of the accessory head of the flexor pollicis longus and the anterior interosseous nerve in Asians. *Clin Anat.*, 2000; 13:434-8.
12. Shanmuga Sundaram Mani, Vishnumaya G, Madhan Kumar SJ; Accessory head of flexor pollicis longus and its significance in anterior interosseous nerve neuropathies and precision handling. *International Journal of Anatomical Variations*, 2010; 3: 46-8.
13. Tabib W, Aboufarah F, Asselineau A; Compression of the anterior interosseous nerve by Gantzer's muscle. *Chirurgie de la main*, 2001; 20: 241-246.
14. Degreef I, De Smet L; Anterior interosseous nerve paralysis due to Gantzer's muscle. *Acta orthopaedica Bélgica*, 2004; 70(5): 482-484.