

Combined Liver and Peritoneal Hydatid Cyst with Connecting Stalk – A Case Report

Dr. Sambhi Reddy G¹, Dr. Jerusha Daggolu^{2*}, Dr. Prabhu Ram N²

¹Professor, Department of General Surgery, Osmania General Hospital, Osmania Medical College, Afzalgunj, Hyderabad, Telangana, India

²Postgraduate, Department of General Surgery, Osmania General Hospital, Osmania Medical College, Afzalgunj, Hyderabad, Telangana, India

*Corresponding author

Dr. Jerusha Daggolu

Email: drjerusha7@gmail.com

Abstract: Hydatid disease is a zoonotic disease endemic to Mediterranean regions. Liver is the most common site, followed by lung, spleen, and other organs. Peritoneal hydatidosis is rare presentation. We report a case of 37 year old female, presented with pain abdomen since 15 days. On clinical examination, she had hepatomegaly, mild epigastric tenderness and pelvic mass. A diagnosis of liver and peritoneal hydatidosis was established using ultrasonography and CT abdomen. Excision of the liver and peritoneal cyst was done and started on Albendazole for 3 months. Liver hydatid disease constitute the most common presentation, followed by lung and spleen. Primary peritoneal hydatidosis is rare, when compared to secondary peritoneal hydatidosis. Accurate and rapid diagnosis of hydatid disease is possible using modern techniques and prevent complications. High degree of suspicion is needed for cysts in other parts of the body when a patient is diagnosed with liver hydatid disease.

Keywords: Case report, Echinococcus, Secondary peritoneal hydatidosis, Liver hydatid, Albendazole.

INTRODUCTION

Hydatid disease is a zoonotic disease which is endemic in Mediterranean regions and few parts of India. Peritoneal hydatidosis is a rare manifestation of hydatid disease, with primary peritoneal disease accounting for less than 2% and secondary peritoneal disease, secondary to abdominal hydatid accounts for 13% [4]. Liver is the most common site, followed by lung, spleen, and other organs [1, 2]. Peritoneal hydatidosis is rare presentation [3].

CASE REPORT

We report a case of 37 year old Indian female, with complaints of pain all over the abdomen since 15 days. It was dragging in nature and more localized in the lower abdomen. No radiating of pain or association with fever, vomiting or menstrual irregularities were seen.

Physical examination revealed mild epigastric fullness with tenderness. Hepatomegaly is present 3cms below the right costal margin. A pelvic mass of size 11*9cms in the right lower abdomen, non tender, smooth surfaced. All borders are well defined except the lower border. Patient had undergone caesarean section 15 years back, without any complications.

Laboratory investigations showed Hemoglobin 11 gm/dl, total and differential counts were normal. ESR is 9mm in first hour. Liver function test revealed

Serum Bilirubin 0.5 mg/dl, AST 22 U/L, ALT 15 U/L, Alkaline phosphatase 84 IU/L. Bleeding time and clotting time are normal. Total protein was 7.4 gm/dl with Serum albumin 3.2 gm/dl. Patient was positive for HIV-1, with a CD4 count of 270 cells/cumm. Patient was started on anti retroviral therapy. Chest roentgenogram did not show any pulmonary infiltrates.

Ultrasonography revealed multiple cysts in the liver with daughter cyst within and mixed echogenicity. Peritoneal cyst of size 15*10 cms is seen in the lower abdomen extending into the pelvis, with daughter cysts and few calcifications.

CT abdomen shows multiple (3) multiloculated cystic lesions noted in the liver and peritoneum,

1. in the right lobe of liver (10.6*10.4 cms),
2. in the left lobe (14.7*14.9 cms), (Fig. 1)and
3. the other peritoneal (16.5*15 cms) extending from the hypogastrium into the pelvis and indenting the urinary bladder (Fig. 2)
4. Multiple calcific densities noted in the peritoneal cavity suggestive of calcified hydatid cyst.

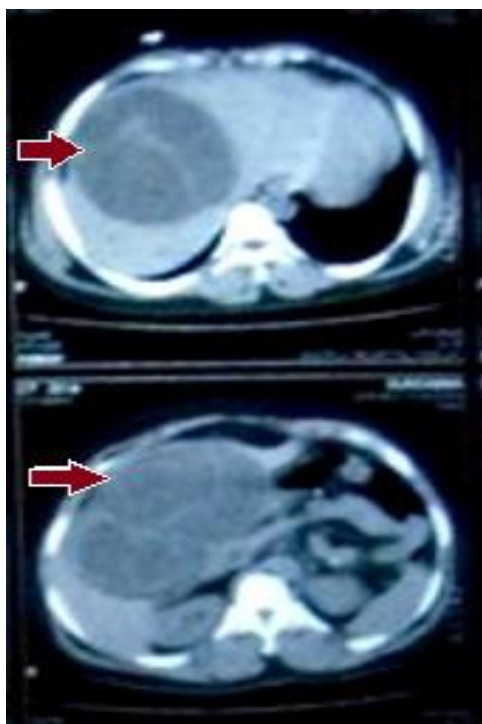


Fig-1: CT showing large cyst in the right and left lobes of liver with daughter cysts(arrow)

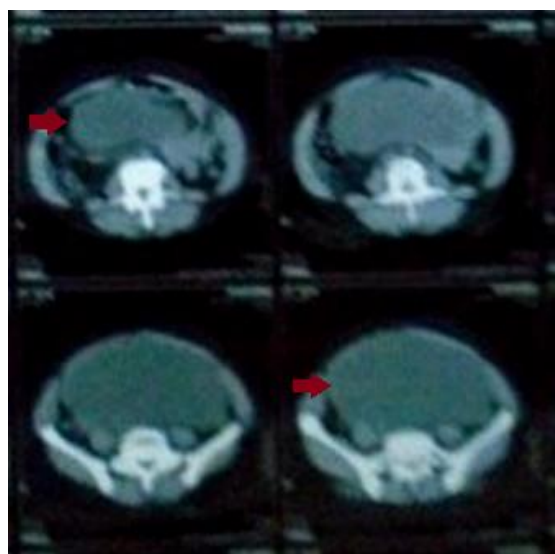


Fig-2: CT showing huge cyst in the pelvis(arrow)

We decided to go for open procedure, with right subcostal incision as the cyst was very huge. The liver cyst was opened after packing the abdomen with towels soaked in scolicidal agent. The cyst cavity was irrigated with hypertonic saline (3%) for 15-20 minutes and all the daughter cysts removed [5]. Inner aspect of the cavity is inspected for communication with bile duct. However, a communication, as small as 1cm was found, connecting it to the peritoneal cyst was seen (Fig. 3). Partial cystectomy of the liver and peritoneal cysts was done as the latter was attached to the bladder. Thorough peritoneal lavage using hypertonic saline was

done. Patient was started on Albendazole 10 mg/kg/day for 3 months. Patient was followed up 9 months.

DISCUSSION

Hydatid disease is a zoonotic disease, caused by larvae of *Echinococcus granulosus*, *E. multilocularis* and *E. oligarthus*[1]. It is endemic in many parts of the Mediterranean countries, Asia and Africa [1, 2]. It is caused by the ingested eggs from dog or infected food and water. It is maintained through dog-sheep-dog cycle. Man is an accidental intermediate host [2].

Hydatid disease mostly involves the liver (50-70%), followed by lung (15%), spleen (5%), brain and bones. Peritoneal involvement of the cystic disease is rare. When the disease reaches the peritoneum, via hematogenous or lymphatic routes, without any abdominal cysts, it is called primary peritoneal hydatidosis. Spread of the disease to the peritoneum from the liver, following surgery or trauma, is called secondary peritoneal hydatidosis [6]. However, spread to the peritoneum following micro rupture of the liver cyst, maintaining connection to it with a stalk is rare. In this case, peritoneal cyst was thought to occur as a result of micro rupture of liver cyst, as evident by a connecting stalk.

The main symptoms are abdominal mass or vague abdominal pain. Accurate and rapid diagnosis is done using ultrasonography and CT abdomen [7]. Ultrasonography will depict typically a cyst with differential wall thickness, separation of membranes (water lily sign), daughter cysts, septa and hydatid sand [8, 9]. WHO classified ultrasonographic features to obtain comparable results worldwide and to link disease status with each morphological type of hydatid cyst [10].

CL Active- Single cyst. Developing and fertile. Cyst wall not visible.

CE1 Active; simple cyst full of hydatid sand (snow flake sign). Visible cyst wall. Fertile.

CE2 Active; multi loculated cysts. Honeycomb like with daughter cysts. Fertile.

CE3 Transition; degenerating cysts but still contain viable protoscolices. Floating membranes in fluid filled cysts

CE4 Inactive; degeneration is advanced. Calcified. Not likely to be fertile. Heterogeneous appearance with few or no daughter cysts.

CE5 Inactive; Often calcified. Usually infertile.

CT abdomen is gold standard in diagnosing number, extent, location and volume of cysts, especially in case of peritoneal cysts. Communication of the liver cyst with the biliary tract can be seen [11].

Serological tests like hydatid antigens, IgG, IgM , ELISA, counter- immuno electrophoresis are

helpful in monitoring the disease after surgery and pharmacotherapy and in prognosis [12].

Treatment of the disease is mainly surgical. Peritoneal cyst needs complete excision of the cyst. However in this case, complete excision of the cyst was not possible as a part of the cyst wall was adherent to the bladder. Liver cyst need to be treated with care to prevent spillage of the daughter cysts. Abdominal cavity should be packed with towels soaked in scolicidal agent. Cyst cavity opened after securing stay sutures, scolicidal agent is injected and wait for 15-20 minutes. Later all the daughter cysts are evacuated carefully. Partial cystectomy is done most commonly. However, other procedures like complete cystectomy, marsupialization, capitonnage, pericystectomy and hepatic resections are performed based on the functional liver residue [13]. Post operative chemotherapeutic agents like Albendazole 10 mg/kg/day used for 3 months in 1 month periods with 15 days interval decreases recurrence and secondary peritoneal hydatidosis [14].

CONCLUSION

Hydatid cyst can present as a surprise diagnosis as, once it enters the systemic circulation it can present anywhere from head to toe. Any lump abdomen should be assessed with suspicion of peritoneal cyst in case of a diagnosed liver cyst and in endemic areas.

ACKNOWLEDGEMENT

I would like to thank the patient who took time to share the details and for regular follow up.

REFERENCES

1. Ates M, Dirican A, Isik B, Yılmaz S. Laparoscopic management of an isolated primary omental hydatid cyst: A case report and literature review. *International journal of surgery case reports*. 2011 Dec 31;2(4):58-60.
2. KL Sampath Kumar. A Case of Primary Peritoneal Hydatidosis: *MJAFL*. 2009;65:278-279.
3. Karavias DD, Vagianos CE, Kakkos SK, Panagopoulos CM, Androulakis JA. Peritoneal echinococcosis. *World journal of surgery*. 1996 Mar 1;20(3):337-40.
4. Wani I, Lone AM, Hussain I, Malik A, Thoker M, Wani KA. Peritoneal Hydatidosis in a Young Girl. *Ghana medical journal*. 2010 Dec;44(4):163.
5. Akinoğlu A, Bilgin I, Erkoçak EU. Surgical management of hydatid disease of the liver. *Can J Surg*. 1985 Mar;28(2):171-2, 174.
6. Acharya AN, Gupta S. Peritoneal hydatidosis: a review of seven cases. *Tropical Gastroenterology*. 2010 Aug 5;30(1):32-4.
7. Fethi D, Mohammad Ben M. Hydatid Cysts of the Liver- Diagnosis, Complications and Treatment, Chapter 5: *Abdominal Surg*; doi: 10.5772/48433.
8. Shah DS, Parikh H, Shah B, Banuprakash S, Shah J. Imaging appearances of hydatid cyst. *Indian Journal of Radiology and Imaging*. 2006 Oct 1;16(4):533.
9. Pedrosa I, Saíz A, Arrazola J, Ferreirós J, Pedrosa CS. Hydatid Disease: Radiologic and Pathologic Features and Complications 1: (CME available in print version and on RSNA Link). *Radiographics*. 2000 May;20(3):795-817.
10. WHO. Inform working group on Echinococcosis. International classification of ultrasound images in cystic echinococcosis for application in clinical and field epidemiological settings. *Acta Trop*. 2003;85(2):253-61.
11. Marrone G, Crino F, Caruso S, Mamone G, Carollo V, Milazzo M, Gruttadauria S, Luca A, Gridelli B. Multidisciplinary imaging of liver hydatidosis. *World J Gastroenterol*. 2012 Apr 7;18(13):1438-47.
12. Zhang W, Li J, McManus DP. Concepts in immunology and diagnosis of hydatid disease. *Clinical microbiology reviews*. 2003 Jan 1;16(1):18-36.
13. Balik AA, Başoğlu M, Celebi F, Ören D, Polat KY, Atamanalp SS, Akçay MN. Surgical treatment of hydatid disease of the liver: review of 304 cases. *Archives of Surgery*. 1999 Feb 1;134(2):166-9.
14. Haluk RU, Yeliz Y. Rupture of liver hydatid into peritoneal cavity. *Saudi Med J*. 2010;31(1).