

An incomplete superficial palmar arch- a case report

Raviprasanna. K.H¹, Anand L Kulkarni²

¹Assistant Professor, Department of Anatomy, Sree Narayana Institute of Medical Sciences, North Kuthiathode, Chalakka, Ernakulam, Kerala.

²Associate Professor, Department of Anatomy, Sree Narayana Institute of Medical Sciences, North Kuthiathode, Chalakka, Ernakulam, Kerala.

***Corresponding author**

Dr. Ravi Prasanna. K. H

Email: pravi_kh81@yahoo.in

Abstract: Superficial palmar arch is a dominant vascular structure in the palm. About a third of superficial palmar arches are formed by ulnar artery alone; a further third are completed by the superficial palmar branch of radial artery; and a third by the arteria radialis indicis, a branch of either arteria princeps pollicis or median artery. During routine dissection in the Department of Anatomy, Sree Narayana Institute of Medical Sciences, Ernakulam, a variant in the formation of superficial palmar arch was observed in right hand of embalmed human male cadaver. The superficial palmar arterial arch observed was of incomplete variety, where superficial branch of ulnar artery supplied medial three and half fingers without anastomosing with the superficial palmar branch of radial artery. The lateral side of index finger and thumb were supplied by deep branch of radial artery. Knowledge about the variations of vascular pattern in hand has gained more importance in reconstructive hand surgeries, microsurgical techniques, preoperative screening of the radial artery harvesting for the myocardial revascularisation.

Keywords: Superficial palmar arch, Variations, Radial artery, ulnar artery.

INTRODUCTION:

Arterial supply to human's hand is derived from the radial and ulnar arteries in the form of superficial and deep palmar arterial arches. Superficial palmar arch is formed mainly by superficial branch of ulnar artery which enters palm along with ulnar nerve superficial to flexor retinaculum and lateral to pisiform bone. It passes medial to hook of hamate and curves laterally to form an arch that is convex distally and level with a transverse line through the distal border of fully extended pollicial base. About a third of superficial palmar arches are formed by ulnar artery alone; a further third are completed by the superficial palmar branch of radial artery; and a third by the arteria radialis indicis, a branch of either arteria princeps pollicis or median artery. From the convexity of superficial palmar arch, 4 palmar digital arteries arise which supply the medial three and half fingers [1]. The fact that superficial palmar arch is main vascular structure of the palm, hence the familiarity about the possible variations in its pattern is important for surgeons dealing with reconstructive hand surgeries and those concerned with restoration of the functional anatomy of the hand.

course in forearm, entered palm superficial to flexor retinaculum along with ulnar nerve and divided into superficial and deep branches. The superficial branch curved laterally to give four palmar digital branches, the most medial branch continued as proper digital branch for medial side of little finger and other three continued to supply 4th, 3rd and 2nd web spaces respectively from medial to lateral side of hand, however it was observed that the superficial palmar branch of radial artery didn't contribute to superficial palmar arch in palm. The princeps pollicis and radialis indicis arteries were arising from deeper part of radial artery which supplied the thumb and lateral side of index finger respectively (Figure-1). The superficial palmar branch of radial artery was absent and there was no anastomosis between superficial branch of ulnar and radial arteries.

OBSERVATION:

During routine dissection in the Department of Anatomy, Sree Narayana Institute of Medical Sciences, Ernakulam, an incomplete variant of superficial palmar arch was observed in right hand of embalmed human male cadaver. The ulnar artery displayed its typical

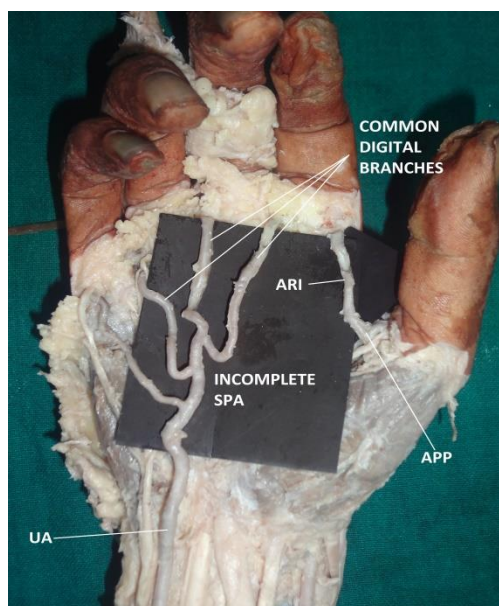


Fig 1: Showing incomplete variant of superficial palmar arch.

Abbreviations: UA- Ulnar artery, ARI- Arteria radialis indicis, APP- Arteria princeps pollicis. SPA- Superficial Palmar Arch

DISCUSSION:

Coleman and Anson [2] in 1961 observed the complete form of arch in 78.5% and incomplete form in 21.5% out of 650 hands used for study. As per the classification provided by Coleman & Anson, there are two groups in formation of superficial palmar arch. Group-1: Complete arch (78.5%), which is further divided into five subtypes. Type A: Classical type which is formed by the radio ulnar arch (superficial palmar branch of radial artery and the larger ulnar artery which constitute to 34.5%). Type-B: formed entirely by ulnar artery alone (37%). Type-C: ulnar artery with an enlarged median artery (3.8%). Type-D: the arch is formed by the combination of three vessels namely radial, median and ulnar (1.2%). Type-E: the arch is formed by ulnar artery and completed by a large sized vessel derived from the deep arch (2%). Group-2: Incomplete arch. (21.5%) The contributing arteries to the superficial palmar arch don't anastomose and when the ulnar artery fails to reach the thumb and index finger, the arch is incomplete. It is further divided into Type-F: the superficial branches of radial and ulnar arteries take part in supplying the palm and fingers but doing so they fail to anastomose (3.2%). Type- G: the ulnar artery forms the SPA but the arch is incomplete because it does not supply the thumb and index finger (13.4%). Type-H: superficial vessels receive contributions from both median and ulnar arteries but without anastomosis (3.8%). Type-I: radial, median and ulnar arteries give origin to superficial vessels but don't anastomose (1.1%). The observation in present case report is similar to Type-F variant where the ulnar artery supplies only up to medial three and half fingers

whereas the branches from radial artery supply lateral side of index finger and both sides of thumb and there is absence of superficial palmar branch of radial artery. The incomplete arch was observed earlier by Loukas, Holdman and Holdman [3] in 10% of their cases, 16% by Patnaik, Kassey and Singla [4], 16% by Al-Turk and Metcalf [5]. The knowledge of different patterns in formation of superficial palmar arch is important while performing the superficial dissections and to the radiologists while performing the angiographic procedures. The clamping of radial artery is contraindicated in cases of deficient collateral flow through the ulnar artery (as in present case) which can lead to ischemia and gangrene of the index and thumb fingers. The recent advances in microsurgical techniques for the reconstruction of hand and upper extremity after trauma and congenital deformities have necessitated better understanding of the vascular patterns of the vessels. The hand surgeon needs to refer to the existence and healthy functioning of the arch before surgical procedures such as, arterial repairs & vascular graft applications. During surgical procedures of thumb & in the cases similar to our study, ligation of radial artery may not be sufficient to stop the profuse bleeding since major blood supply would be coming from the ulnar artery. The knowledge of arterial anatomy and its morphology may be of use in graft surgeries, especially when the arteries of upper limb are harvested for the coronary artery bypass grafts [6]. Allen's test, Doppler ultra sound, Arterial angiography and Pulse oximetry should therefore be used to assess the efficiency of collateral circulation before surgical interventions. Characteristics favoring the use of Radial artery for coronary grafting are: A caliber similar to that of the major coronary arteries, adequate thickness and resistance of the arterial wall, and sufficient length to allow complete myocardial revascularization, Non-dominant arterial supply in upper limb and if dominant-Ulnar artery can be used.

EMBRYOLOGY:

Arey [7] has described the causes of anomalous blood vessels developmentally. (a) The choice of unusual paths in the primitive vascular plexus. (b) The persistence of vessels normally to be obliterated. (c) The disappearance of vessels normally retained. (d) Incomplete development and (e) Fusion & absorption of the parts usually distinct.

CONCLUSION:

Vessels of the palm bleed profusely but at the same time heal rapidly because of arterial anastomoses. Superficial palmar arch plays a principal role in microsurgeries following crush injuries of hand. It maintains the collateral circulation in case of obstruction of any of the arteries in hand. The hand surgeons should be aware of these different types of variants before attempting surgical procedure like vascular repair, graft application. Knowledge of variations of vascular patterns of hand gained more

importance even in preoperative screening of radial artery harvesting for myocardial revascularization and in arterial interventions that include radial artery cannulation and radial artery forearm flap. A lack of knowledge of such type of variants might complicate reconstruction hand surgeries.

REFERENCES:

1. Standring S, Ellis H, Healy JC. Vascular supply and lymphatic drainage. Gray's Anatomy-Wrist and Hand. 39th ed. Edinburgh: Elsevier Churchill Livingstone. 2005:925-33.
2. COLEMAN SS, Anson BJ. Arterial patterns in the hand based upon a study of 650 specimens. *Surgery, gynecology & obstetrics*. 1961 Oct; 113:409.
3. Loukas M, Holdman D, Holdman S. Anatomical variations of the superficial and deep palmar arches. *Folia Morphol (Warsz)*. 2005 May; 64(2):78-83.
4. Patnaik VV, Kalsey G, Singla RK. Palmar arterial arches-A morphological study. *J Anat Soc India*. 2002; 51(2):187-93.
5. Al-Turk M, Metcalf WK. A study of the superficial palmar arteries using the Doppler Ultrasonic Flowmeter. *Journal of anatomy*. 1984 Jan; 138(Pt 1):27.
6. Latiff AA, Othman F, Suhaimi FH, Das S. Anomalous superficial palmar arch: a cadaveric study with clinical implications. *Archives of Medical Science*. 2008 Jun 1;4(2):197-9
7. Arey L.B. *Developmental Anatomy*, W.B. Saunder's Co. Philadelphia, 6th edition, 1957; 375-377.