

## Effects of Ethanolic Extract of *Bauhinia Variegata* Leaves Alone and In Combination with Metoclopramide on Induced Model of Acute Colitis in Rabbits

Mustafa Hussein Sachit<sup>1</sup>, Ahmed Rahma Abu Raghif<sup>2</sup>, Shihab Abdul Rhman Shihab<sup>3</sup>

<sup>1</sup>M. Sc. Pharmacology, Dept. of Pharmacology, Al-Nahrain University College of Medicine, Baghdad, Iraq

<sup>2</sup> Professor in Pharmacology, Al-Nahrain University College of Medicine, Baghdad, Iraq

<sup>3</sup> Lecture in pharmacology, Al-Nahrain University College of Medicine, Baghdad, Iraq

### Original Research Article

#### \*Corresponding author

Mustafa Hussein Sachit

#### Article History

Received: 07.02.2018

Accepted: 15.02.2018

Published: 28.02.2018

#### DOI:

10.21276/sajp.2018.7.2.5



**Abstract:** The exact reasons of UC are still unidentified; however, numerous factors have been implicated in the pathophysiology of the disease. Inflammatory mediators such as cytokines, reactive oxygen species, also 5-HT plays a key task in the pathogenesis of UC. The available drugs for the treatment of UC have considerable systemic side effects. Therefore, there is a pressing need for the development of new therapeutic agents for the treatment of UC, Thus, the evolution of a new safe, efficient and cheap medicine is required. The aim of current study is to investigate the effect of ethanolic extract of *Bauhinia variegata* alone or in combination with metoclopramide on inflammatory biomarkers, oxidative stress parameters and histopathological score in experimentally induced colitis. This study was conducted on thirty six male albino weighting about (1000-1750) g rabbits were brought from animal house previously submitted to starvation for at least 12hrs. Animals were divided into six groups (n=6/group). All groups except group I (served as normal control and received no treatment) were received 2ml acetic acid rectally. Group II served as a colitis control and were received only acetic acid rectally. Group III, IV, V and VI rabbits with colitis treated rectally with mesalazine 100mg/kg, ethanolic extract of *Bauhinia variegata* 200mg/kg and metoclopramide 0.5mg/kg and combination of *Bauhinia variegata* plus metoclopramide respectively for 5days. All these drugs were given for five days rectally. After the end of experiment, blood collected from animals for measurement of the serum cytokines (Tumor necrosis factor-alpha and Interlukin-6) by ELISA kits, then sacrificed by an over dose of diethyl ether inhalation and then the abdomen was rapidly dissected and open the colon was removed and submitted to microscopical assessment (histopathological score) and the measurement of the colonic tissue of lipid peroxide and glutathione peroxidase by ELISA kits. Combination produced the significant reduction in histological score in comparison with ethanolic extract of *Bauhinia variegata*, metoclopramide, ( $P < 0.01$ ),  $1 \pm 0$ ,  $1.11 \pm 0.06$ ,  $2 \pm 0$ , respectively, but less than mesalazine which is  $0.9 \pm 0.04$ . Combination produced the significant reduction in colonic tissue of lipid peroxide in comparison with ethanolic extract of *Bauhinia variegata*, metoclopramide ( $P < 0.01$ ) and its effect was comparable to that produced by mesalazine ( $P > 0.05$ )  $10.04 \pm 1.21$ ,  $10.67 \pm 1.09$ ,  $13.87 \pm 1.31$ ,  $9.5 \pm 1.88$  respectively. Combination produced the significant reduction in colonic tissue of glutathione peroxidase in comparison with ethanolic extract of *Bauhinia variegata*, metoclopramide ( $P < 0.01$ ) and its effect was comparable to that produced by mesalazine ( $P > 0.05$ )  $37.11 \pm 1.12$ ,  $36.04 \pm 1.83$ ,  $27.26 \pm 1.98$ ,  $37.56 \pm 1.63$  respectively. Combination produced the significant reduction in serum level of tumor necrosis factor alpha in comparison with ethanolic extract of *Bauhinia variegata*, metoclopramide ( $P < 0.01$ ) and its effect was comparable to that produced by mesalazine ( $P > 0.05$ )  $16.86 \pm 0.6$ ,  $18.34 \pm 1.26$ ,  $29.09 \pm 1.28$ ,  $14.76 \pm 0.77$  respectively. Combination produced the significant reduction in serum level of interlukin-6 in comparison with ethanolic extract of *Bauhinia variegata*, metoclopramide ( $P < 0.01$ ) and its effect was comparable to that produced by mesalazine ( $P > 0.05$ )  $89.97 \pm 1.08$ ,  $91.01 \pm 1.58$ ,  $119.05 \pm 1.03$ ,  $87.09 \pm 1.88$  respectively.

**Keywords:** Ulcerative colitis, *Bauhinia variegata* leaves, Serotonin, Antioxidant, Antiinflammatory.

## INTRODUCTION

Ulcerative colitis (UC) is categorized by continuous colonic mucosal inflammation that spreads proximally from the rectum. It is a prolonged illness that classically presents in the second or third decade of life with bloody diarrhea and abdominal spasms [1]. The chief symptoms of UC are diarrhea, rectal bleeding, tenesmus, passageway of mucus, and crampy abdominal pain [2].

The severity of UC can be categorized as mild, moderate, severe, or fulminant [3]. UC is more public than Crohn disease. Both diseases are more common in the industrialized world, principally North America and Western Europe, though the incidence is increasing in Asia. The total incidence is reported as 1.2 to 20.3 cases per 100,000 persons per year, with a prevalence 100, 000 of 7.6

The uncertainty of the etiologic factors of UC and the failure of current treatment strategies to control many cases of UC make a strong stimulus to find out a new relatively safe and effective modality of treatment. Studies pointed to overproduction of free radicals and decreased antioxidant capacity in the pathogenesis of UC both in animal models of induced colitis, also serotonin (5-HT) plays a key task in the pathogenesis of UC.

## MATERIALS AND METHODS

### Plant collection and extraction

- The leaves of *B.variegata* were collected from Baghdad city and authentication was done in pharmacognosy and medicinal plants in college of pharmacy-AL-Mustansiriyah University.
- Plant material was then cut into smaller pieces and then washed with tap water followed by washing with D.W.
- Then dried in an incubator at 37c, until water droplets get completely evaporated.
- Dried plant material then crashed by mortar and pistol to be extracted by soxhlet apparatus.
- 200gm of air dried leaves of *B. variegata* plant were placed into soxhlet thimble to be extracted with 1500ml of ethanol 95% for 15 hrs. Then cooled, filtered and evaporator under reduced pressure by rotary evaporator, the residents obtained and weighted after evaporation [4].

### Animal

Thirty six male albino weighting about (1000-1750) g rabbits were brought from animal house. The animals were maintained on normal conditions.

### Induce colitis

After an overnight fasting, Colonic inflammation will be induced under general anesthetic diethyl ether; by intrarectal administration of 2ml of 5% (v/v) acetic acid in 0.9% NaCl with polythene plastic catheter will be inserted into lumen of the colon via anus [5].

### Collection of blood sample and tissue specimen

At end of each group experimental, blood samples were collected by intracardiac puncturing under light diethyl ether anesthesia and collected in clean test tubes, allow for clotting, then centrifuged for 20minutes at 3600(r.p.m).Serum was separated and stored into Eppendorf tubes at -20c to be used for determination of the levels of two inflammatory mediator interleukin 6(IL-6) and TNF-alpha by ELISA kits.

Tissue specimens: Incise specimen and weigh, add a given amount of PBS (PH 7.4). Immediately freeze for later used to study mucosal contents of oxidative stress studies,

- Lipid peroxidation. (ELISA) kit.
- Glutathione peroxidase activities. (ELISA) kit

### Histopathological studies

After scarification, decapitation and dissection, colon from each rabbits was rapidly excised and then perfused in saline solution. Pieces from the colon and rectum of rabbits of different groups were taken and fixed in 10% neutral buffered formalin for twenty four hours. Fixed organs were sent to histopathology laboratory in AL-Nahrin Medicine, for further processing, blocking in wax, sectioning and staining with hematoxylin and eosin (H&E). And results scored according to [6].

## RESULTS

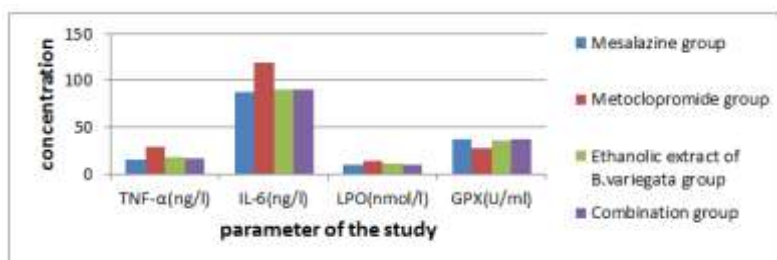
The finishing weight and yield percentage of ethanoic extract of *Bauhinia variegata* leaves that were extracted from 200gm of leaves powder are show in table 1:

Table-1: weight and yield percentage

| Weight | Yield %    |
|--------|------------|
| 40gm.  | 20 % (w/w) |

### Effects between the studied groups on the involved parameters

The mean results of effects of mesalazine, metoclopramide, ethanolic extract of *Bauhinia variegata* and combination on the four studied parameters are shown in figure 1:



**Fig-1: The mean results of effects of mesalazine, metoclopramide, ethanolic extract of *B. variegata* and combination on the four studied parameters**

Analysis of variance test (ANOVA) was used to compare between the effects of the four studied (mesalazine, metoclopramide, ethanolic extract of *B. variegata* and combination groups on each parameter (TNF- $\alpha$ , IL-6, LPO and GPX). It was found that there was significant difference regarding TNF- $\alpha$ , IL-6, LPO and GPX between the four groups ( $P \leq 0.01$ ).

Tukey's HSD test was used for testing the significant difference of the six possible pairs of the four studied groups.

The results of the Tukey's HSD test at 0.05 level of significance are shown in table 1.

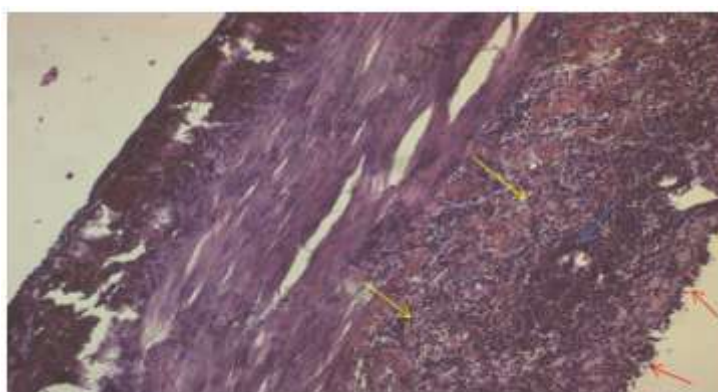
**Table-2: significant differences between the pairs of treatment regarding the percentages of means reduction at 0.05 using tukey's test**

| Pairs of treatment                       |  | TNF | IL6 | LPO | GPX |
|--|--|-----|-----|-----|-----|
| Mesalazine                               | Metoclopramide                           | *   | *   | *   | *   |
| Mesalazine                               | Ethanolic extract of <i>B. variegata</i> | ↔   | ↔   | *   | *   |
| Mesalazine                               | Combination                              | ↔   | ↔   | ↔   | ↔   |
| Metoclopramide                           | Ethanolic extract of <i>B. variegata</i> | *   | *   | *   | *   |
| Metoclopramide                           | Combination                              | *   | *   | *   | *   |
| Ethanolic extract of <i>B. variegata</i> | Combination                              | ↔   | ↔   | *   | *   |

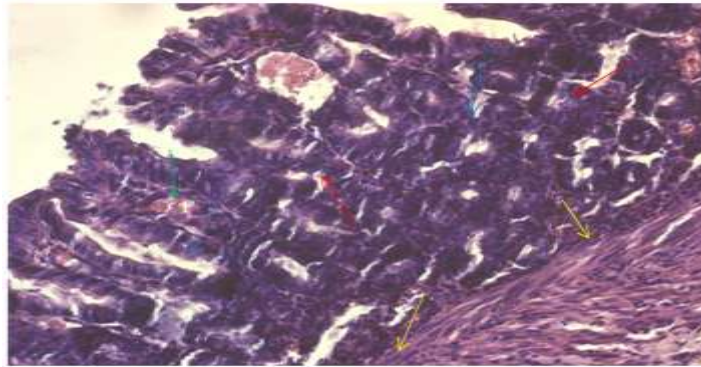
\*: significant difference ( $p \leq 0.05$ ). ↔: No significance difference change ( $P > 0.05$ ). Combination (ethanolic extract of *Bauhinia variegata* + metoclopramide)

Combination produced the significant reduction in histological score in comparison with ethanolic extract of *Bauhinia variegata*,

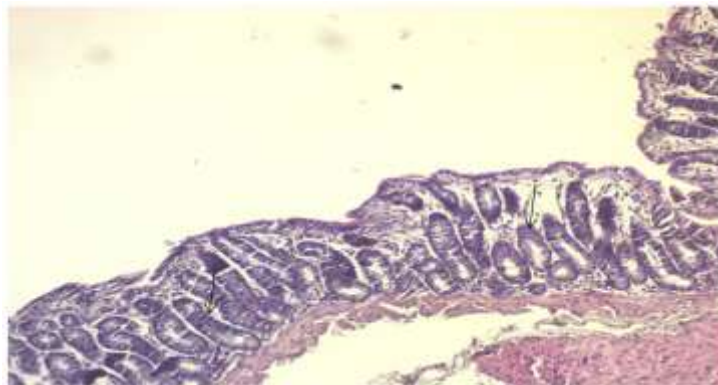
metoclopramide, ( $P < 0.01$ ),  $1 \pm 0$ ,  $1.11 \pm 0.06$ ,  $2 \pm 0$ , respectively, but less than mesalazine which is  $0.9 \pm 0.04$ .



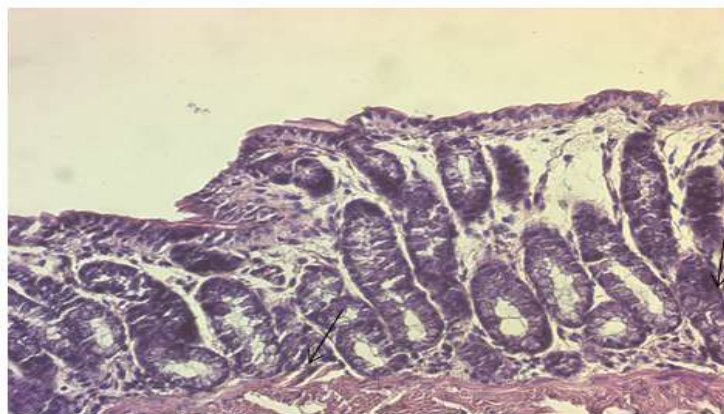
**Fig-2: Section of rabbit colonic tissue (Induction by acetic acid group) showing diffuse mucosal ulceration (red arrows), diffuse architectural abnormality of colonic crypts (blue arrow), severe and extensive inflammation reaching submucosa (yellow arrows), (score 3), H&E, 10X**



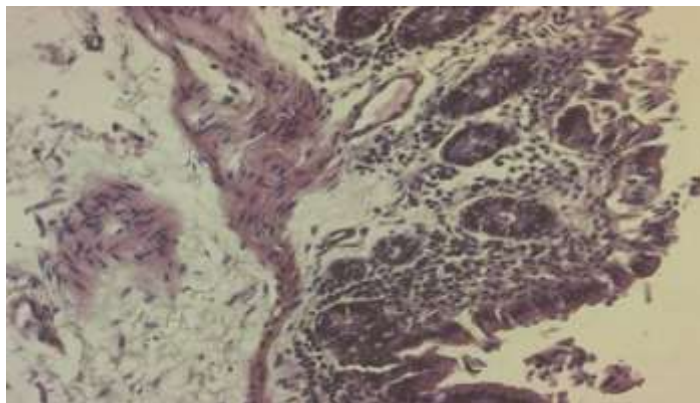
**Fig-3:** Section of rabbit colonic tissue (Induction by acetic acid group) showing, diffuse architectural abnormality of colonic crypts (blue arrows), complete depletion of goblet cells (green arrow), severe and extensive inflammation reaching submucosa (yellow arrows), diffuse dysplasia (red arrows). (score3), H&E, 20X



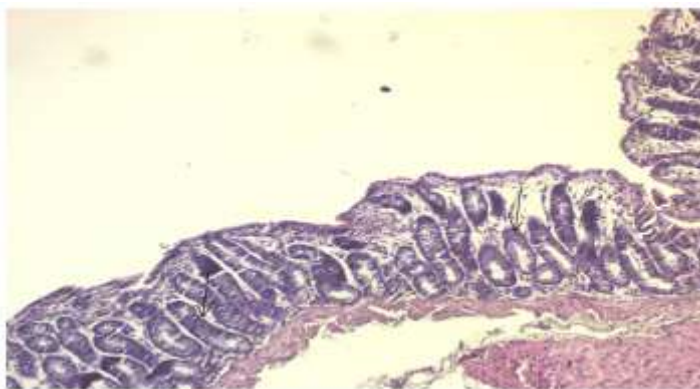**Fig-4:** Section of rabbit colonic tissue of normal group showing morphologically normal colonic glands containing goblet cells (black arrow) and stroma. (Score 0).H&E 10X



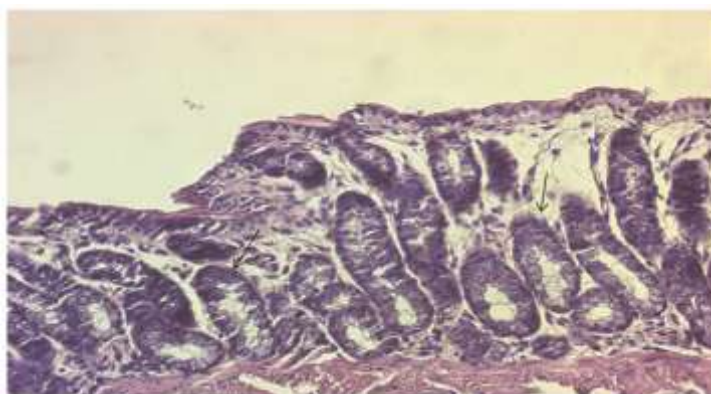
**Fig-5:** Section of rabbit colonic tissue of normal group showing morphologically normal colonic glands containing goblet cells (black arrow) and stroma. (Score 0).H&E 10X



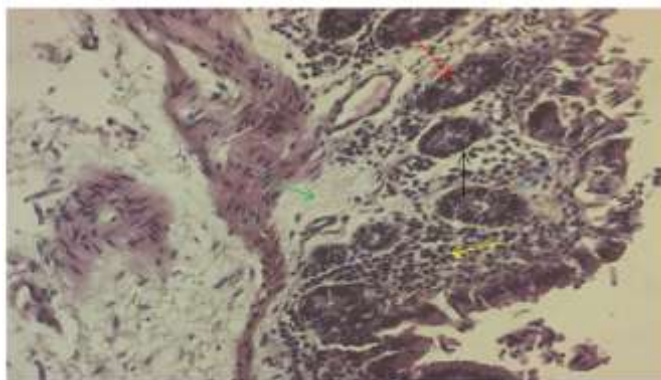
**Fig-6:** Section of rabbit colonic tissue(mesalazine gp) showing focal architectural distortion of glandular crypt(red arrow),slightly depleted goblet cells (blue arrow),inflammatory cell infiltrate at the subepithelial and lamina propria and crypt bases infiltration (yellow arrow),focal edema(green arrow)and focal dysplasia(black arrow).(score1).H&E,20X



**Figure 7:** Section of rabbit colonic tissue(herbal gp) showing focal architectural distortion of glandular crypts (red arrow),slightly depleted goblet cells (blue arrow),inflammatory cell infiltrate at the subepithelial and lamina propria and crypt bases infiltration (yellow arrow),focal edema(green arrow)and focal dysplasia(black arrow).(score1).H&E,10X



**Fig-8:** Section of rabbit colonic tissue (Metoclopramide gp)showing zonal architectural distortion of colonic crypts(red arrow),moderate depleted goblet cells (blue arrow), inflammatory cell infiltrate reaching muscularis mucosa (yellow arrow),moderate diffuse edema(green arrow)and zonal dysplasia(black arrow).(score 2). H&E,20X



**Fig-9: Section of rabbit colonic tissue(combination gp) showing architectural distortion of glandular crypts(red arrow),slightly depleted goblet cells (blue arrow),inflammatory cell infiltrate at the subepithelial and lamina propria and crypt bases infiltration (yellow arrow),focal edema(green arrow)and focal dysplasia(black arrow).(score1).H&E,20X**

## DISCUSSIONS

The available drugs for the treatment of UC have considerable systemic side effects. Therefore, there is a pressing need for the development of new therapeutic agents for the treatment of UC. Thus, the evolution of a new safe, efficient and cheap medicine is required.

In this study Acetic acid-induced ulcerative colitis (UC) is a model of UC that bears close resemblance to human UC in terms of pathogenesis, histopathological features and inflammatory mediator profile [7]. In the present study showed significant reduction in the pro-inflammatory cytokines of both TNF- $\alpha$  and IL-6 due to ethanolic extract of *Bauhinia variegata* have significant anti-inflammatory activity [8].

In present study showed that ethanolic extracts of *B. variegata* significantly reduced in lipid peroxide and increase in glutathione peroxidase due to reduce the oxidative stress via elevating the levels of anti-oxidant enzymes and reducing the levels of lipid peroxides [9].

In this work ethanolic extracts of *B. variegata* had significantly reduced histopathological changes of colon in experimentally induced colitis. The profound reduction in histopathological changes following the administration of ethanolic extracts of *B. variegata* when compared to induction group may be attributed to the more potent anti-inflammatory and anti-oxidant activity of ethanolic extracts of *B. variegata*. Furthermore, kaempferol which is a type of flavonide is active ingredient in *B. variegata* preserved the goblet cell function [10].

The present study demonstrated that mesalazine significantly reduced TNF- and IL-6 proinflammatory cytokines in rabbits because it is ability to interfere with the production of these cytokines [11]. And its anti-inflammatory properties.

Mesalazine also have both anti-inflammatory and immunomodulatory properties [12].

On the other hand the mesalazine significantly reduced lipid peroxide and increase glutathione peroxidase levels in rabbit colonic mucosa in comparison with colitis group due to reduce the production of free radicals and anti-oxidant properties [13]. Furthermore, mesalazine may have antioxidant properties that reduce tissue injury and play a part in inhibition of T cell activation and proliferation [14].

On the other hand mesalazine had significantly reduced histopathological score of colon in experimentally induced colitis because the mesalazine was effective in reducing tissue damage and oxidative and inflammatory damage, restored antioxidant capacity [11].

In this study metoclopramide cause significant reduction in TNF- and IL-6 proinflammatory cytokines and lipid peroxide and increase in glutathione peroxidase in comparison with induction group may be due to metoclopramide have 5HT3 receptor antagonist and experimental studies revealed that 5-HT3 receptor both analgesic and anti-inflammatory effects [15], also another study reported that 5-HT4 receptor stimulation can resistance to oxidative stress-induced apoptosis and inhibit inflammation[16], Metoclopramide, which targeted both 5-HT4 and 5-HT3 receptors [17].

Metoclopramide cause less changes in studied parameters in compare with other treatable groups (mesalazine, ethanol *Bauhinia variegata* and combination)

On the other hand metoclopramide had significantly reduced histopathological score of colon in experimentally induced colitis but less than other treatable groups in this study and the effect of metoclopramide on histopathological score may be due to activation of mucosal 5-HT4 receptor lead to

epithelial cell proliferation, wound healing, and oxidative stress resistance. Can restore normal motility in animals with colitis [18]. In combination group show the important results from present study may be due to additive effect between metoclopramide and ethanolic extract of *Bauhinia variegata* when given to animals. Indeed, the combination group showed significantly more reduction in inflammatory parameters (serum levels of tumor necrosis factor- $\alpha$ , and interleukin-6), oxidative stress parameter (tissue levels glutathione peroxidase and lipid peroxide).

The reasonable interpretation for this additive effect could be due to the concomitant effort of the different mechanisms of action of both ethanolic extract of *Bauhinia variegata* and metoclopramide, because of anti-inflammatory activity [19], potent antioxidant activity [20]. Furthermore, *B. variegata* have free radical scavenging [21].

### CONCLUSIONS

- Ethanolic extract of *Bauhinia Variegata* was effect in treatment of acetic acid induce colitis due to it is ability to reduce TNF- $\alpha$ , IL-6, lipid peroxide and increase glutathione peroxide. also it enhance histopathological picture.
- Metoclopramide cause partial effect on acetic acid induce colitis due to it is ability to reduce TNF- $\alpha$ , IL-6, lipid peroxide and increase glutathione peroxide. also it is effect on histopathological picture was significant.
- The combination group (ethanolic extract of *Bauhinia variegata* plus metoclopramide) showed more potent anti-inflammatory and antioxidant.

### REFERENCES

1. Danese S, Fiocchi C. Ulcerative Colitis. N Engl J Med.2011; 365(18):1713-1725.
2. Friedman S, Blumberg RS. Inflammatory bowel disease in. Braunwald Eugene, Harrison's principles of internal medicine. Fifteenth edition.2001; pp. 1679-1681.
3. Ford AC, Moayyedi P, Hanauer SB. Ulcerative colitis. BMJ. 2013; 346:f432.
4. Prashant T, Bimleshk, mandeep K, phytochemical screening and Extraction: A Review Internationale Pharmaceuticasciencia..2011;(1):1
5. MacPherson, B and Pfeiffer C. Experimental production of diffuse colitis in rats. Digestion. 1978;17: 135-50.
6. Cooper HS, Murthy SN, Shah RS .Clinical pathological study of dextran sulfate sodium experimental murine colitis. *Lab Invest* .1993; 69:238-49.
7. Hartmann RM, Morgan Martins MI, Tieppo J. Effect of *Boswellia serrata* on antioxidant status in an experimental model of colitis rats induced by acetic acid. *Dig Dis Sci*.2012;57 (8):2038-2044.
8. Mohameda MA, Mammoudb MR, Hayenc H. Evaluation of Antinociceptive and Anti-

- Inflammatory Activities of a New Triterpene Saponin from *Bauhinia variegata* Leaves.2009; 64: 798-808.
9. Johnson DB, Narayanan DRV, Kavimani DS. Effect of *Indigofera aspalathoides* and *Bauhinia variegata* on Paracetamol induced hepatotoxicity. *Int J Pharma Innovations*.2012; 2(3): 1-14
10. Park MY, Ji GE, Sung MK. Dietary kaempferol suppresses inflammation of dextran sulfate sodium-induced colitis in mice. *Digestive diseases and sciences*. 2012 Feb 1;57(2):355-63.
11. Campregher C, Gasche C. Aminosalicylates. *Best Pract ResClin Gastroenterol*.2011;25:535-46.
12. MacDermott RP. Progress in understanding the mechanism of action of 5-aminosalicylic acid. *Am J Gastroenterol* .2000; 95: 3343-3345.
13. Sutherland L, Roth D, Beck P, May G, Makiyama K. Oral 5-aminosalicylic acid for maintenance of remission in ulcerative colitis. *CochraneDatabase Syst Rev*.2002; (4): CD000544.
14. Santucci L, Wallace J, Mencarelli A, Farneti S, Morelli A, Fiorucci S. Different sensitivity of lamina propria T-cell subsets to nitric oxide-induced apoptosis explains immunomodulatory activity of a nitric oxide-releasing derivative of mesalamine in rodent colitis. *Gastroenterology*.2005; 128: 1243-1257.
15. Fiebich BL, Akundi RS, Seidel M, Geyer V, Haus U, Müller W, Stratz T, Candelario-Jalil E. Expression of 5-HT<sub>3A</sub> receptors in cells of the immune system. *Scandinavian journal of rheumatology*. 2004 Jun 1;33(sup119):9-11.
16. Leppkes M, Roulis M, Neurath MF, Kollias G, Becker C .Pleiotropic functions of TNF- $\alpha$  in the regulation of the intestinal epithelial response to inflammation. *International immunology*.2014; 26:509-515.
17. De Maeyer JH, Lefebvre RA, Schuurkes JA. 5-HT<sub>4</sub> receptor agonists: similar but not the same. *Neurogastroenterology & Motility*. 2008 Feb 1;20(2):99-112.
18. Spohn SN. Protective Actions of 5-HT<sub>4</sub> Receptors in the Colonic Epithelium.
19. Calderón-Montaña JM, Burgos-Morón E, Pérez-Guerrero C, López-Lázaro M. A review on the dietary flavonoid kaempferol. *Mini Rev Med Chem*.2011; 11:298-344).
20. Mishra A, Kumar S, Bhargava A, Sharma B, Pandey AK. Studies on in vitro antioxidant and antistaphylococcal activities of some important medicinal plants, *Cellular and Molecular Biology*.2011; 57(1), 16-25.
21. Uddin G, Sattar S, Rauf A. Preliminary phytochemical, in vitro pharmacological study of *Bauhinia Alba* and *Bauhinia variegata* flowers. *Middle-East Journal of Medicinal Plants Research*. 2012; 4:75-9.