

## Inferior Wall Post-Myocardial Infarction Ventricular Septal Defect: Case Report and Literature Review

Franck Ekoba Othende<sup>1\*</sup>, Camara Mamady<sup>1</sup>, Ousmane Diawara<sup>1</sup>, Camara Tibou<sup>1</sup>, Fatima Rebbouh<sup>1</sup><sup>1</sup>Service de Cardiologie et Maladies Vasculaires, CHU Mohamed VI Marrakech, MoroccoDOI: [10.36347/sjmcr.2023.v1i103.042](https://doi.org/10.36347/sjmcr.2023.v1i103.042)

| Received: 03.02.2023 | Accepted: 15.03.2023 | Published: 31.03.2023

\*Corresponding author: Franck Ekoba Othende

Service de Cardiologie et Maladies Vasculaires, CHU Mohamed VI Marrakech, Morocco

### Abstract

### Case Report

Ventricular septal rupture secondary to a myocardial infarction is a fearsome acute complication whose mortality is not negligible in the early phase. We report the case of a septal rupture in a 71-year-old patient admitted to emergency department for the management of an inferior wall post-myocardial infarction. It is an extreme emergency whose management must be multidisciplinary. We emphasize the localization and treatment of this complication.

**Keywords:** Myocardial infarction, ventricular septal defect, inferior wall, Morocco.

**Copyright © 2023 The Author(s):** This is an open-access article distributed under the terms of the Creative Commons Attribution **4.0 International License (CC BY-NC 4.0)** which permits unrestricted use, distribution, and reproduction in any medium for non-commercial use provided the original author and source are credited.

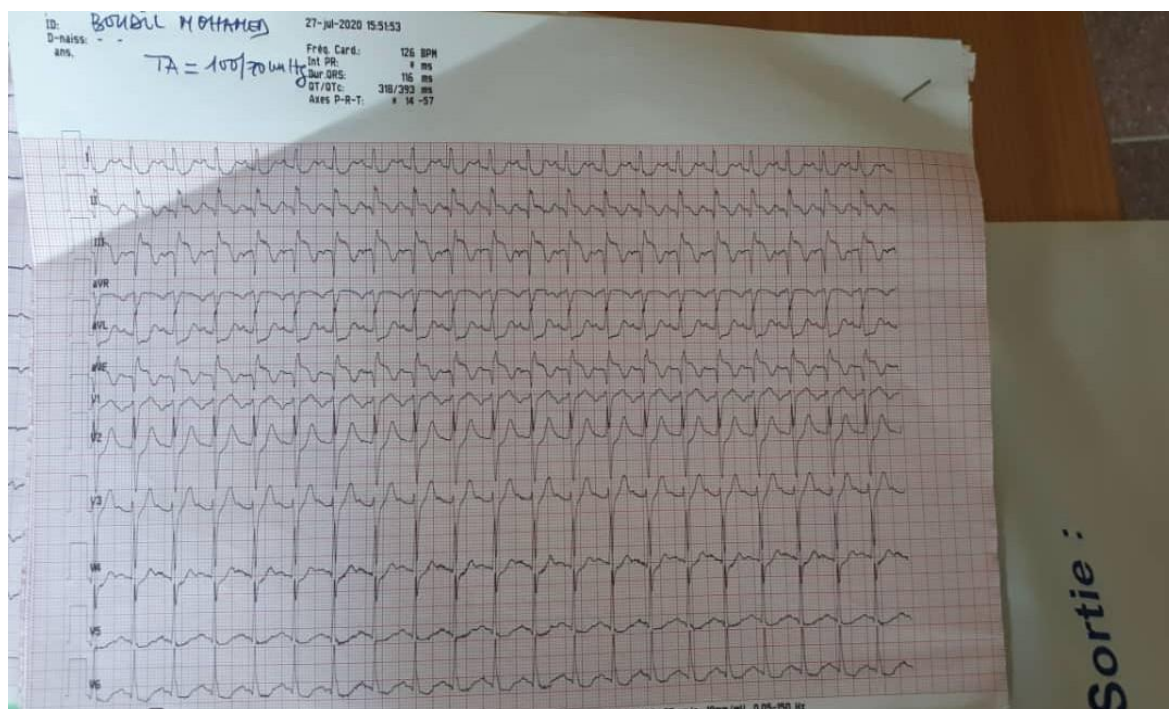
## INTRODUCTION

Post-myocardial infarction (MI) ventricular septal defect (VSD) is a rare but no less exceptional complication in the era of aggressive treatments and thrombolysis in the early phase of acute coronary syndrome. Its prevalence was 1 to 2% before the popularization of thrombolysis; however, mortality remains high of around 90% [1] according to some studies. This is an extreme emergency imposing multidisciplinary care between cardiologist, emergency doctor and cardiovascular surgeon. We report in this observation the case of a patient who has presented an acute coronary syndrome with septal rupture St Segment elevation.

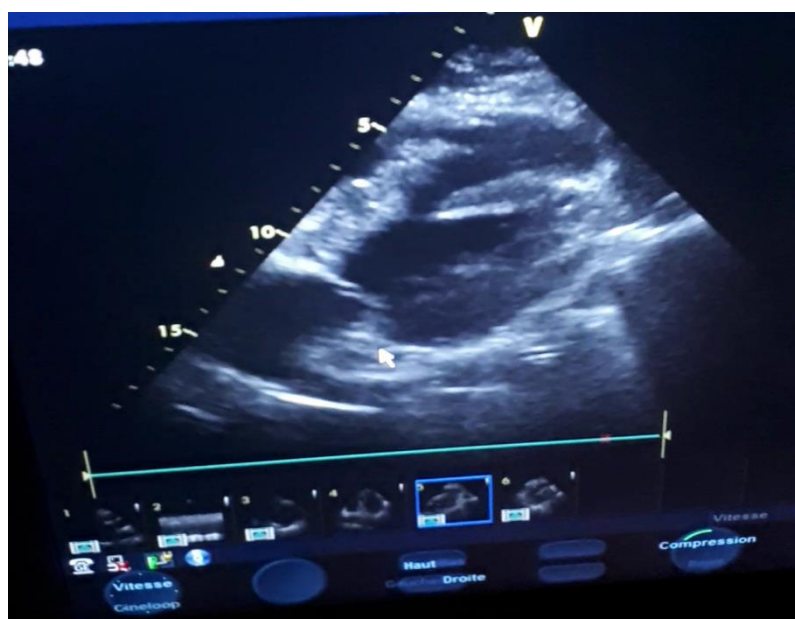
## PATIENT AND OBSERVATION

He is a 71-year-old man, with as cardiovascular risk factors a tabaco exposure degree at 30 packets year and dyslipidemia admitted for chest pain. The start of the symptoms dates back to 48 hours before his admission by installing the infarction pain associated with dyspnea NYHA stage 4 evolving in an apyretic context and general state conservation. Once admitted to the resuscitation room, the patient was aware with 88/55mmhg hemodynamic instability,

tachycardia at 110bpm with the presence of shock signs (cool, cyanosis and marbling). We noted the presence of right heart failure signs, jugular venous distention, hepato-jugular reflux. Auscultation revealed a mill-wheel systolic murmur on mitral valve. On respiratory level, the patient was Tachypneic at 35 breaths per minute. His pulsed oxygen saturation was 94% in open air. The electrocardiogram had objectified inferior wall St Segment elevation with necrosis q waves presence (Figure 1). US troponin was high, the renal function moderately altered and the protein C was 150mg/l. The transthoracic echography shows an inferior wall septal defect measuring 11 mm, leading to a left-right shunt. The right ventricle appears to be hypokinetic non-dilated; the left ventricular function was preserved while the contractile alteration is limited to its lower part (Figure 2). The patient was put under dobutamin 10ug/kg/min, double anti-aging and heparin, he benefited from an emergency coronarography objectifying an acute thrombotic occlusion of the posterior inter-ventricular artery with timed flow = 0 culprit to dilate in emergency, stenosis significant of the average anterior interior artery, significant stenosis of the second marginal artery. The patient was transferred to cardiological intensive care while awaiting the establishment of a balloon in which he dies.



**Figure 1: Electrocardiogram had objectified inferior wall ST Segment elevation with necrosis q waves presence**



**Figure 2: Ventricular septal defect**

## DISCUSSION

Post-myocardial infarction septal rupture is a catastrophic complication involving the vital prognosis which current incidence is between 0.2% to 1% with high mortality exceeding 90% [2]. The average time to this complication is 1 to 5 days [3], in our case it takes 2 days after the Coronary syndrome ST+ starts. Advanced age is one of the most common risk factors in our case the patient was 71-years-old [4]. The anterior part remains the most frequent about 61% against 39% for the posterior part, such as our patient who had a dominant right network with right coronary occlusion. The MI can be complicated with right ventricular

insufficiency in 45% of cases [5]. Cardiogenic shock is described in 60% cases as is the case of our patient. The positive diagnosis is echocardiographic. The treatment is medico-surgical as well as intervention. An urgent surgical repair has been initially proposed since the 1980s, because medical treatment alone was sold by mortality of around 100% [6]. AHA/ACC recommends emergency restorative surgery despite an early surgery (3 days-4 weeks) has an intra-hospital mortality of 52% while for delayed surgery, it is around 8% [7]. Waiting for a surgical treatment intra-aortic balloon pump can be put in place (60% of cases).

## CONCLUSION

Post-myocardial infarction ventricular septal defect is an extreme diagnostic and interventional emergency whose lethality remains worrying today despite therapeutic advances.

## CONFLICTS OF INTEREST

The authors declare no conflicts of interest regarding the publication of his paper.

## REFERENCES

1. Crenshaw, B. S., Granger, C. B., Birnbaum, Y., Pieper, K. S., Morris, D. C., Kleiman, N. S., ... & Topol, E. J. (2000). Risk factors, angiographic patterns, and outcomes in patients with ventricular septal defect complicating acute myocardial infarction. *Circulation*, *101*(1), 27-32. [PubMed] [Google Scholar]
2. Kalyani, R., Trivedi, A., Philippe Aldebert, A. R. C., Julien Mancinid, E., Gilles Levyf, J. C. M., Jacques Quilicci, C., & Gilbert Habibc, A. F. B. (2015). Prise en charge séquentielle des communications interventriculaires postinfarctus myocardique. *Archives of Cardiovascular Disease*, *108*(5), 321-330. [Google Scholar]
3. Deja, M. A., Szostek, J., Widenka, K., Szafron, B., Spyt, T. J., Hickey, M. S. J., & Sosnowski, A. W. (2000). Post infarction ventricular septal defect—can we do better?. *European journal of cardiothoracic surgery*, *18*(2), 194-201. [PubMed] [Google Scholar]
4. Gueret, P., Khalife, K., Jobic, Y., Fillipi, E., Isaaaz, K., Tassan-Mangina, S., ... & Meune, C. (2008). Echocardiographic assessment of the incidence of mechanical complications during the early phase of myocardial infarction in the reperfusion era: a French multicentre prospective registry. *Archives of cardiovascular diseases*, *101*(1), 41-47.
5. Gaudiani, V. A., Miller, D. G., Stinson, E., Oyer, P. E., Reitz, B. A., Moreno-Cabral, R. J., & Shumway, N. E. (1981). Postinfarction ventricular septal defect: an argument for early operation. *Surgery*, *89*(1), 48-55. [PubMed] [Google Scholar]
6. Papalexopoulou, N., Young, C. P., & Attia, R. Q. (2013). What is the best timing of surgery in patients with post-infarct ventricular septal rupture?. *Interactive cardiovascular and thoracic surgery*, *16*(2), 193-196. [Article PMC gratuit] [PubMed] [Google Scholar]
7. Held, A. C., Cole, P. L., Lipton, B., Gore, J. M., Antman, E. M., Hochman, J. S., ... & Alpert, J. S. (1988). Rupture of the interventricular septum complicating acute myocardial infarction: a multicenter analysis of clinical findings and outcome. *American heart journal*, *116*(5), 1330-1336. [PubMed] [Google Scholar].