

Post-Operatively Complete Atrioventricular Block (AVB) Complicated Left Atrial Myxoma: Case Report and Literature Review

Franck Ekoba Othende^{1*}, Ousmane Diawara¹, Camara Mamady¹, Camara Tibou¹, Fatima Rebbouh¹¹Service de Cardiologie et Maladies Vasculaires, CHU Mohamed VI Marrakech, MoroccoDOI: [10.36347/sjmcr.2023.v1i103.043](https://doi.org/10.36347/sjmcr.2023.v1i103.043)

| Received: 03.02.2023 | Accepted: 16.03.2023 | Published: 31.03.2023

***Corresponding author:** Franck Ekoba Othende

Service de Cardiologie et Maladies Vasculaires, CHU Mohamed VI Marrakech, Morocco

Abstract**Case Report**

Cardiac myxomas constitute the most frequent forms of primitive and benign heart tumors. The left atrial location is by far the most frequent. The variability of their clinical symptomatology is related to size, mobility and location of the mass. Their diagnosis is first and foremost echocardiographic. This pathology has an increased risk of sudden death and thromboembolic complications therefore requiring early surgical management. We report the case of a 38-year-old patient with a dyspnea Stade III NYHA whose clinical examination objectified a breath of mitral narrowing. Echocardiography made possible the diagnosis of left atrium myxoma with the beginning of entrapment in the mitral valve histologically confirmed after an urgent surgical resection. The patient presented a complete AVB successfully set right after surgery. Cardiac myxomas are pathologies with serious complications involving patient's life and functional prognosis. Conduction disorders are part of the rhythmic complications encountered in post-operative state.

Keywords: Cardiac myxomas, Echocardiography, Atrioventricular block, atrial septal (AS).**Copyright © 2023 The Author(s):** This is an open-access article distributed under the terms of the Creative Commons Attribution 4.0 International License (CC BY-NC 4.0) which permits unrestricted use, distribution, and reproduction in any medium for non-commercial use provided the original author and source are credited.

INTRODUCTION

Cardiac myxomas are the most frequent intracardiac tumors in adults. They occur at an average age around fifties with a female predominance. The left atrial location represents 85% against 15% in the right atrium [1]. In the majority of cases, their insertion is at interior septum level in the region of the oval pit. The symptomatology is disparate and the diagnosis is facilitated by echocardiography and its management is a surgical emergency, especially due to thromboembolic complications. We report in this observation the case of a 38-year-old patient who presented a complete AVB after excision of a myxoma.

PATIENT AND OBSERVATION

She is a 38-year-old woman without cardiovascular risk factors and without any particular history admitted for dyspnea Stade III NYHA and precordial catch syndrome. The clinical examination finds a conscious patient; her BP is 110/77mmHg with a heart rate at 109bpm. Pulsed oxygen saturation is 97%, cardiac auscultation reveals a systolic mitral pan 3/6th as a radiating towards the left axils and a diastolic bearing of 4/6th intensity. The electrocardiogram was

on regular and sinus rhythm without conduction or repolarization disorders. The thorax radiography showed a hilum overlay with dilation of the pulmonary artery. The echocardiography objectified the presence of finely rounded pediculated training with attachment to the SIA measuring 3*3cm and beginning of ancestor at the mitral valve creating a functional mitral narrowing with an average gradient of 13mmHg and a moderate IM. This aspect being in favor of a myxoma (Figure 1). The right ventricular function is preserved, there is a severe functional IT (sor = 40mm²) associated with a severe BP at 120mmHg. The diagnosis of OG myxoma is retained with indication of surgical resection with plastic repair of tricuspid valve. The patient is then transferred to the cardiovascular surgery service. It benefited from a myxoma resection in its entirety 5mm of margin of its implantation base with closure of the SIA defect by an untreated pericardial patch with De VEGA technique tricuspid valve plastic repair (Figure 2). Anatomopathological examination has confirmed the diagnosis of myxoma without signs of malignancy. The evolution at J9 in post-operatively is marked by the appearance of a complete recurrent AVB having benefited from the implementation of a double room pace with simple operating suites.

Citation: Franck Ekoba Othende, Ousmane Diawara, Camara Mamady, Camara Tibou, Fatima Rebbouh. Post-Operatively Complete Atrioventricular Block (AVB) Complicated Left Atrial Myxoma: Case Report and Literature Review. Sch J Med Case Rep, 2023 Mar 11(3): 417-418.

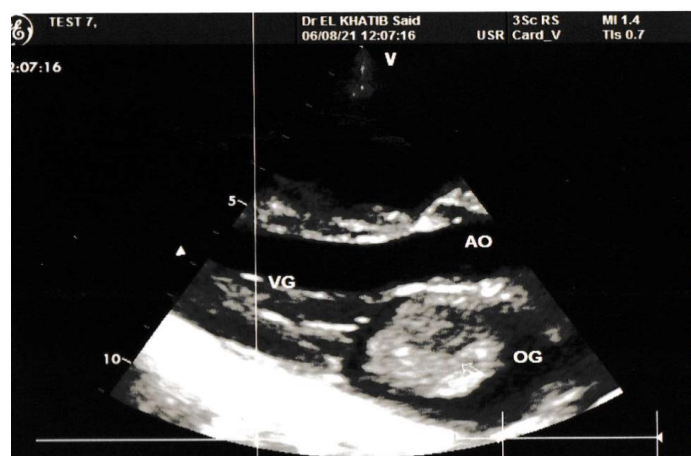


Figure 1: Transthoracic echocardiography of myxoma

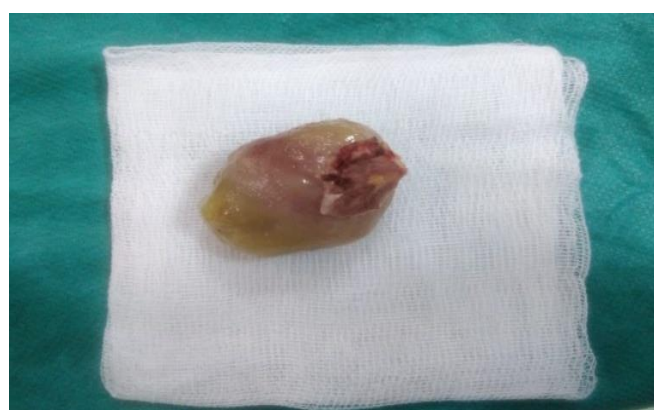

Figure 2: Operatory piece of myxoma mensuration 5*4*3.5 cm

DISCUSSION

Cardiac myxomas are histologically made up of multipotent mesenchymal cells, residue of the cardiac embryonic period. Their consistency is gelatinous, friable, explaining why the diagnosis is often revealed by an embolic complication which occurs in 45% to 60% of cases [2] and can concern different organs. The discovery average age is around 40 years and a clear female predominance is reported this is the case of our patient. Left atrium location represents around 85% of cases it's the location found in our observation [2, 3]. Echocardiography is the key examination of diagnosis with a sensitivity of 93%. Surgical resection most often allows permanent treatment and must be carried out quickly given the risks of sudden death and embolism. However, there is no real consensus concerning the approach as well as the attitude towards the site of establishment [4]. Post-operative morbidity marked by an high incidence of rhythm and conduction disorders is helped by the biatrial approach and large excision.

CONCLUSION

The cardiac myxoma is characterized by a clinical polymorphism which can be confusing for the

clinician. Echocardiography is the key examination of positive diagnosis. Despite its benign histological nature, its intracardiac location engages the vital prognosis which requires an emergency surgical treatment with minimal post-operative mortality.

CONFLICTS OF INTEREST

The authors declare no conflicts of interest regarding the publication of his paper.

BIBLIOGRAPHIC REFERENCES

1. Braun, S., Schrötter, H., Reynen, K., Schwencke, C., & Strasser, R. H. (2005). Myocardial infarction as complication of left atrial myxoma. *Int J Cardiol.*, 101(1), 115-21.
2. Riberi, A., Gariboldi, V., Grisoli, D., & Collart, F. (2010). Les tumeurs cardiaques. *Revue de Pneumologie Clinique. 1 févr.*, 66(1), 95-103.
3. El bakkali, Y., Boulahya, A., & Wahid, F. (2003). Myxomes atriaux : à propos de 7 cas opérés. *Rev Mar Cardio*, 5, 5-8.
4. Sellke, F. W., Lemmer Jr, J. H., Vandenberg, B. F., & Ehrenhaft, J. L. (1990). Surgical treatment of cardiac myxomas: longterm results. *The Annals of thoracic surgery*, 50(4), 557-561.