

Foreign Body Ingestion in Children: A Case Report and Management Strategies

Zakarya Alami Hassani (MD)^{1*}, Toulalouth Lafia², Omar Dalero², Houda Oubejja³, Hicham Zerhouni³, Mounir Erraji³, Fouad Ettayebi³

¹Resident Doctor, Surgical Pediatric Emergency Department, Children's Hospital, Faculty of Medicine and Pharmacy, Mohamed V University, Rabat, Morocco

²Specialist in Pediatric Surgery, Surgical Pediatric Emergency Department, Children's Hospital, Faculty of Medicine and Pharmacy, Mohamed V University, Rabat, Morocco

³Professor of Higher Education, Surgical Pediatric Emergency Department, Children's Hospital, Faculty of Medicine and Pharmacy, Mohamed V University, Rabat, Morocco

DOI: [10.36347/sjmcr.2023.v11i04.021](https://doi.org/10.36347/sjmcr.2023.v11i04.021)

| Received: 27.02.2023 | Accepted: 11.04.2023 | Published: 14.04.2023

*Corresponding author: Zakarya Alami Hassani (MD)

Resident Doctor, Surgical Pediatric Emergency Department, Children's Hospital, Faculty of Medicine and Pharmacy, Mohamed V University, Rabat, Morocco

Abstract

Case Report

Introduction: Foreign body ingestion in children is a common pediatric emergency that can result in serious complications if not managed promptly. **Observation:** it is a case report of an 18-month-old infant who ingested a knife while playing with his 3-year-old sister. The patient was stable but required a surgical approach due to the size of the object and the risk of esophageal injury during removal. **Discussion:** Children between 6 months to 3 years are at the highest risk for foreign body ingestion. The most common foreign bodies ingested by children are small objects such as coins, toys, magnets, button batteries, and small parts of other objects. Symptoms can vary depending on the type and location of the foreign body and can range from choking, difficulty breathing, and vomiting to blood in stool or vomit and fever. Sharp and elongated objects, as well as batteries and magnets, can cause life-threatening complications such as airway obstruction, esophageal perforation, or bowel obstruction. The approach to management depends on the type and location of the foreign body, and preventing foreign body ingestion in children is critical to avoiding the need for management. Various measures, such as keeping small objects out of reach, providing age-appropriate toys, and supervising young children during playtime, can be implemented to prevent foreign body ingestion in children. **Conclusion:** Foreign body ingestion is a common pediatric emergency that can lead to serious complications if not managed promptly. Prevention is key in reducing the incidence of foreign body ingestion in children.

Keywords: Foreign body ingestion, children, pediatric surgery, knife ingestion, case report.

Copyright © 2023 The Author(s): This is an open-access article distributed under the terms of the Creative Commons Attribution 4.0 International License (CC BY-NC 4.0) which permits unrestricted use, distribution, and reproduction in any medium for non-commercial use provided the original author and source are credited.

INTRODUCTION

Ingestion of foreign bodies is a common pediatric emergency that can lead to serious complications if not managed promptly. Children are particularly vulnerable to this type of incident due to their curious and exploratory nature, which leads them to put objects in their mouth. Foreign body ingestion can range from harmless incidents to life-threatening emergencies. We report the case of an 18-month-old infant who ingested a knife while playing with his 3-year-old sister. The patient was stable but required a surgical approach due to the size of the object and the risk of esophageal injury during removal.

OBSERVATION

An 18-month-old infant was brought to the pediatric surgical emergency department with suspected knife ingestion, which occurred while playing with his 3-year-old sister.

The parents were not present at the time of the incident, so no additional information could be obtained from them.

The patient was in good general condition, stable hemodynamically and respiratorily, with a

respiratory rate of 20 cycles per minute, and a soft abdomen without palpable mass.

A plain abdominal x-ray (figure 1) confirmed the presence of a foreign body at the esophago-gastric junction, which was identified as the metal part of the knife.

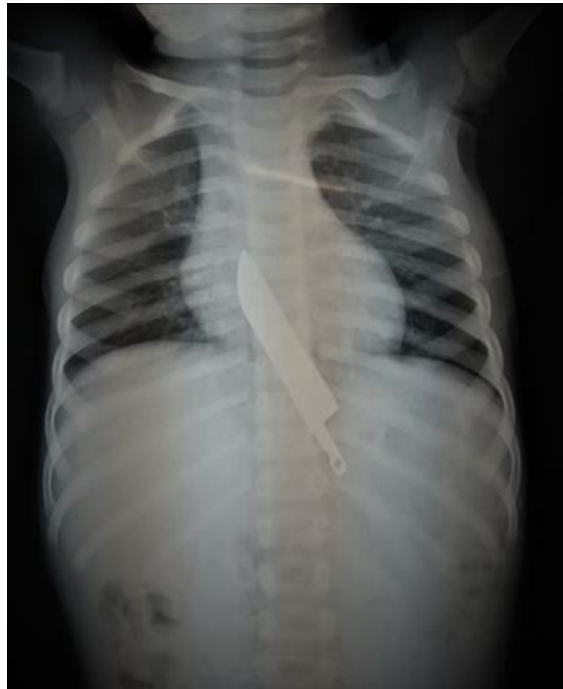

Figure 1: Plain abdominal x-ray showing the metal part of the knife in the esophago-gastric junction

Due to the size of the object and the risk of esophageal injury during removal, a surgical approach was chosen over endoscopic removal.

During exploration, the plastic part of the knife was felt inside the stomach (figure 2A), and a gastrectomy (figure 2B) was performed to extract the 16

cm long kitchen knife (figure 2C). No lesions were found during the exploration of the gastric mucosa and cardia. The patient was discharged from the operating room with a nasogastric tube in place and kept fasting for 4 days allowing good healing of the gastric sutures. The patient was later discharged after 5 days with a referral to child psychiatry for follow-up.

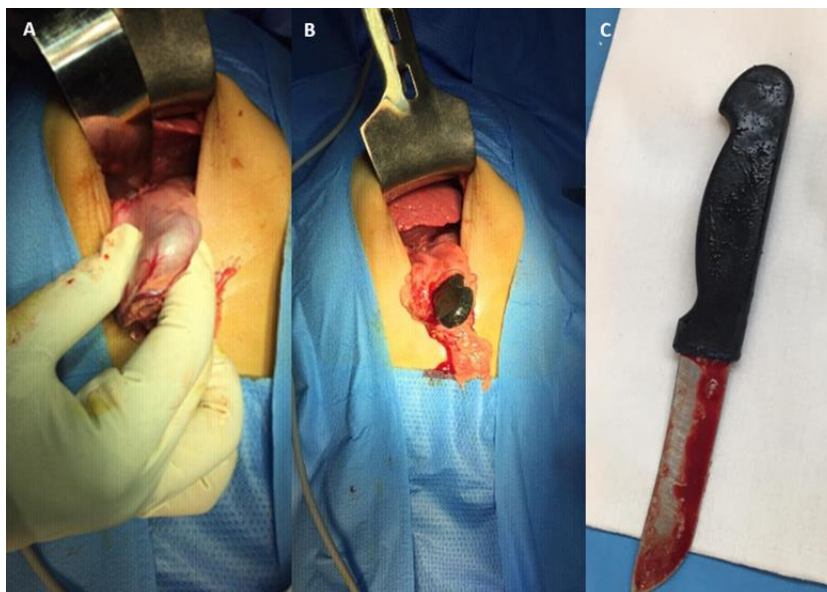


Figure 2: (A) The plastic part of the knife inside the stomach, (B) Exteriorization of the knife from the stomach, (C) a kitchen knife of 16 cm long

DISCUSSION

The ingestion of foreign bodies is a relatively common problem in children. Studies have shown that children between the ages of 6 months to 3 years are at the highest risk for foreign body ingestion, with peak incidence around 1 to 2 years of age [1].

The specific types of foreign bodies can vary depending on the age and developmental stage of the child, as well as their access to certain objects. The most common ones are small objects such as coins, toys, magnets, button batteries, and small parts of other objects.

Symptoms can vary depending on the type and location of the object. Some children may not show any symptoms at all, while others may experience: choking, difficulty breathing or wheezing, refusing to eat or drink, abdominal pain or discomfort, vomiting, blood in stool or vomit, fever [2].

The most dangerous foreign bodies are those that can cause life-threatening complications such as airway obstruction, esophageal perforation, or bowel obstruction. These can include sharp objects such as knives, pins, or needles, as well as batteries, and magnets. Button batteries are particularly hazardous as they can cause tissue damage and severe injury to the esophagus or stomach if not promptly removed [1].

The management of a patient with suspected ingestion of foreign bodies depends on several factors, including the type of foreign body, location, size, and the presence of any complications. It involves stabilizing the patient, obtaining a detailed history, performing a physical examination, and ordering diagnostic tests such as X-rays, CT scans, or ultrasounds.

The approach to management depends on the type and location of the foreign body. Small, smooth, and non-toxic foreign bodies located in the stomach or beyond may pass spontaneously and can be managed conservatively with observation and supportive care.

Sharp and elongated objects are responsible for a significant proportion of cases (15% to 35%) [3]. While perforation can occur anywhere in the digestive system, it is more likely to occur at areas of curvature or narrowing, particularly the ileocecal valve. Objects longer than 5 cm in length (3 cm in young children) and wider than 2 cm are unlikely to pass and should be urgently removed endoscopically or surgically as it was the case for our patient, before passing the stomach.

Smaller objects can be observed until they pass in the stools and can be managed conservatively [4].

Battery ingestion can cause tissue injury through pressure necrosis, low voltage electric current, and release of alkaline solution, which can cause liquefaction necrosis and perforation of the esophagus. Urgent endoscopic removal is necessary for batteries lodged in the esophagus, as one hour of contact time can result in mucosal injury, and all layers of the esophagus may be involved within four hours [5].

Preventing foreign body ingestion in children is paramount to avoid having to manage it altogether. To achieve this, various measures can be implemented, including keeping small objects out of reach, providing age-appropriate toys, and supervising young children during playtime.

CONCLUSION

Foreign body ingestion is a common pediatric emergency that can lead to serious complications if not managed promptly. Prevention is key in reducing the incidence of foreign body ingestion in children.

CONFLICT OF INTEREST STATEMENT

The authors have no financial disclosures or conflict of interest.

Informed Consent

Written consent was obtained from the patient's parents for the publication of their child's case.

REFERENCES

1. Kader, A., & Hesham, H. (2010). Foreign body ingestion: children like to put objects in. *World J Pediatr.*, 6(4), 301-310.
2. Monte, C., & Uyemura, M. D. (2005). Foreign Body Ingestion in Children. *American Family Physician*, 72(2).
3. Tam, W., & Cheng, P. K. H. (1999). Foreign-Body Ingestion in Children: Experience With 1,265 Cases. *Journal of Pediatric Surgery*, 34, 10.
4. Jayesh, D., Hemanshi, S., Charu, T., Deepa, M., & Vikrant, K. (2016). Ingested sharp objects in children: is conservative management effective? *International Journal of Contemporary Pediatrics*, 3(4).
5. Eliason, M. J., Ricca, R. L., & Gallagher, T. Q. (2017). Button battery ingestion in children. *Current Opinion in Otolaryngology & Head and Neck Surgery*, 25(6).