

Celiac Trunk Aneurysm: About A Case Report

Y. Bouktib^{1*}, M. Raboua¹, B. Boutakioute¹, M. Ouali¹, N. Cherif Idrissi Ganouni¹

¹Radiology Department, Arrazi Hospital, CHU Mohammed VI, Faculty of Medicine and Pharmacy, Cadi Ayyad University, Marrakech, Morocco

DOI: [10.36347/sjmcr.2023.v11i04.028](https://doi.org/10.36347/sjmcr.2023.v11i04.028)

| Received: 02.03.2023 | Accepted: 11.04.2023 | Published: 14.04.2023

*Corresponding author: Y. Bouktib

Radiology Department, Arrazi Hospital, CHU Mohammed VI, Faculty of Medicine and Pharmacy, Cadi Ayyad University, Marrakech, Morocco

Abstract

Case Report

Introduction: Celiac trunk (CT) aneurysms are known to be rare; their severity is represented by the risk of rupture which is often lethal. Their diagnosis is becoming easier due to the more common use of imaging means. **Objective:** Demonstrate the value of angioscanner in the diagnosis of aneurysms and guide the therapeutic management. **Case Report:** This is a 59-year-old patient with a history of ACFA who has presented for 1 month with diffuse abdominal pain without associated signs. Abdominal angioscanner objectifies a fusiform aneurysmal dilatation of the terminal part of the celiac trunk measuring 19 mm in diameter with no detectable signs of rupture or appearance of calcifications or thrombus. **Conclusion:** Advances in imaging have significantly changed the incidence; angioscanner can help in planning surgical and other clinical interventions.

Keywords: Celiac trunk (CT), imaging, diagnosis, Abdominal angioscanner.

Copyright © 2023 The Author(s): This is an open-access article distributed under the terms of the Creative Commons Attribution 4.0 International License (CC BY-NC 4.0) which permits unrestricted use, distribution, and reproduction in any medium for non-commercial use provided the original author and source are credited.

INTRODUCTION

Celiac trunk (CT) aneurysms are known to be rare, their severity is represented by the risk of rupture which is often lethal. Their diagnosis is becoming easier due to the more common use of imaging means.

OBSERVATION

This is a 59-year-old patient with a history of ACFA who has presented for 1 month with diffuse abdominal pain without associated signs.

RESULTS

Abdominal angioscanner (Figure 1 and 2) objectifies a fusiform aneurysmal dilatation of the terminal part of the celiac trunk measuring 19 mm in diameter with no detectable signs of rupture or appearance of calcifications or thrombus.

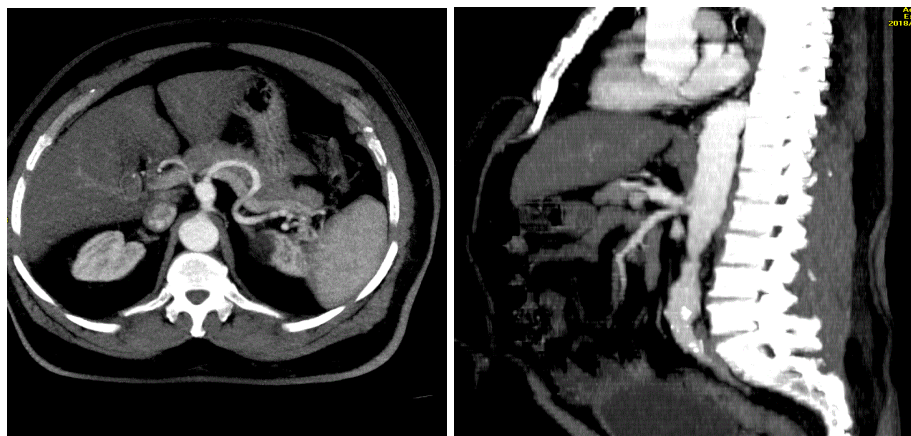


Figure 1 and 2: Abdominal angioscan axial and sagittal sections: Fusiform aneurysmal dilatation of the terminal part of the celiac trunk measuring 19 mm in diameter without signs of rupture

DISCUSSION

The actual frequency of celiac trunk aneurysms is difficult to assess; they represent the fourth most frequent location among visceral artery aneurysms. The risk of rupture is low but real, it is estimated between 10 and 20%, it would be more important for infectious aneurysms and those whose size is greater than 2 cm, the presence of thrombus or calcifications does not increase the risk of rupture. The association with other extra visceral aneurysmal locations has been noted. Atherosclerosis is currently the most frequent cause, infectious aneurysms, particularly syphilitic aneurysms, have become exceptional. In most cases, celiac trunk aneurysms are asymptomatic or the symptomatology is so modest as to be unrecognized. In the books of surgical semiology, a "triad" was described: epigastric pain, abdominal murmur, epigastric pulsatile mass, which presence was considered pathognomonic of aneurysm.

Imaging: Diagnosis involves ultrasound and especially abdominal angioscanner, providing information on:

Aneurysm: size, neck, branches, carrier vessels, wall.

Dissection: extent, entry-exit

Signs of rupture, evolutivity

Organ damage

Other possible arterial lesions.

Diagnosis of celiac trunk aneurysms requires ultrasound to differentiate a cystic or hypoechoic mass from a circulating aneurysm and to look for signs of hyperflow and/or stenosis of the digestive arteries. However, it remains of limited value depending on the location of the aneurysm and the morphology of the patient.

Abdominal angioscanner allows a better definition of the aneurysm, its shape, often saccular, < 2cm, well limited, with homogeneous enhancement, often thin-walled, and which may be the site of calcifications or fine thrombus. In case of dissection, it appears with a double lumen aspect with or without the presence of stenosis of the portal artery.

Angiography has the same diagnostic value as CT, but is especially important for the endovascular treatment of complicated aneurysms.

Treatment:

Endovascular treatment is often the first-line treatment. It includes exclusion of the aneurysm by an aortic endoprosthesis placed opposite the celiac trunk after embolization of the stomach coronary artery and the hepatic artery.

The indication for endovascular treatment depends on:

- The size: > 2 cm or 2 x diameter of the portal artery.
- The evolution: growth, modification of the contours).
- The location.
- The terrain: pregnancy, PH, liver transplantation, PAN, elastopathies.

CONCLUSION

Advances in imaging have significantly changed the incidence; angioscanner can help in planning surgical and other clinical interventions.

REFERENCES

- Aneurysms of the digestive arteries: diagnosis and pre-therapeutic assessment Véronique Marteau - Stéphane Silvér Luigi Novelli - Marc Zins Groupe Hospitalier Paris Saint Joseph JFR 2015
- Jesinger, R. A., Thoreson, A. A., & Lamba, R. (2013). Abdominal and pelvic aneurysms and pseudoaneurysms: imaging review with clinical, radiologic, and treatment correlation. *Radiographics*, 33(3), E71-E96.
- Pitton, M. B., Dappa, E., Jungmann, F., Kloeckner, R., Schotten, S., Wirth, G. M., ... & Dueber, C. (2015). Visceral artery aneurysms: incidence, management, and outcome analysis in a tertiary care center over one decade. *European radiology*, 25, 2004-2014.